

CLINICAL AND INSTRUMENTAL ANALYSIS OF PROSTHETIC TREATMENT SUPPORTED BY ZIRCON PRIOR DENTAL IMPLANTS

A.M. Potapchuk, V.M. Kryvanych, V.V. Rusyn, M.Y Goncharuk-Khomyn

Uzhgorod National University

Department of Postgraduate Dental Education

Summary: The complex evaluation of the effectiveness of prosthetic treatment of dentition defects with the use of fixed structures supported by Zircon prior dental implants was based on results of clinical and instrumental diagnostics methods. The evaluation of success rate also was provided in the remote period.

Key words: dental implantation, late resorption, Zircon prior

Background. Despite the fact that the number of dental implantation procedures in dental practice is increasing every year, the loss of implants associated with development of periimplantitis and disintegration of implants, unfortunately, is a common complication. Studies that involve research of the factors that cause negative dental implantation results are relevant and ongoing nowadays. Number of researches directed on the investigation of the biocompatibility level of the materials of which implants are made, features and lapses of different implantation techniques, and the influence of bacterial («plague theory») and biomechanical overload factors (“loading theory”) on remote and immediate outcomes [4,6].

Comprehensive assessment of prosthetic treatment efficiency of patients with dentition defects by fixed structures supported with dental implants should be directed on the evaluation of the clinical and periodontal impact factors on the peri-implant tissue condition at the immediate and remote post-treatment periods [8,10]. Also, such assessment should be done with regard to subjective patient satisfaction by conducted implant treatment, as one of the indicators of the overall success of any iatrogenic intervention [1,2]. Only the verification of such relationships will form the objective criteria for adequate selecting of treatment algorithm and adapted implantation protocol that justifies the use of dental implants with the relevant structural characteristics [1-3]. Such differentiated approach is aimed to improve the efficiency of direct and remote results of prosthetic treatment supported by dental implants and provide complex argumentation of convincingly confirmed success prognosis of iatrogenic intervention.

Objective: to conduct complex clinical and instrumental analysis of implantation success results with the use of “Zircon Prior” implant system and evaluate the effect of clinical and periodontal factors on late bone resorption late at periimplant region; to provide argumentation for compliance of clinical intervention effectiveness indicators and success criteria of implant treatment according to the results of questionnaire survey of patients from researched groups.

Materials and methods. A comprehensive examination and treatment of 83 patients aged from 25 to 75 years with defects of dentition (I-III classes by Kennedy) with the fixture of 250 implants were provided to evaluate the algorithm of dental implantation. Among researched group 37 males (44.6%) and 46 females (55.4%) were presented, while 115 implants were installed during males treatments and 135 during treatment of female group (Fig. 1-2).

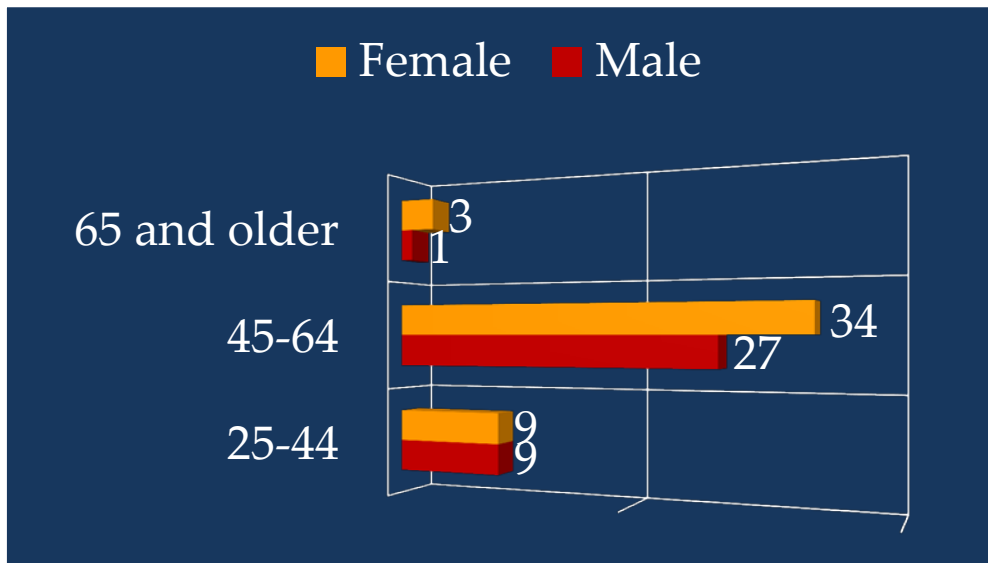


Figure 1. Distribution of patients by age and gender

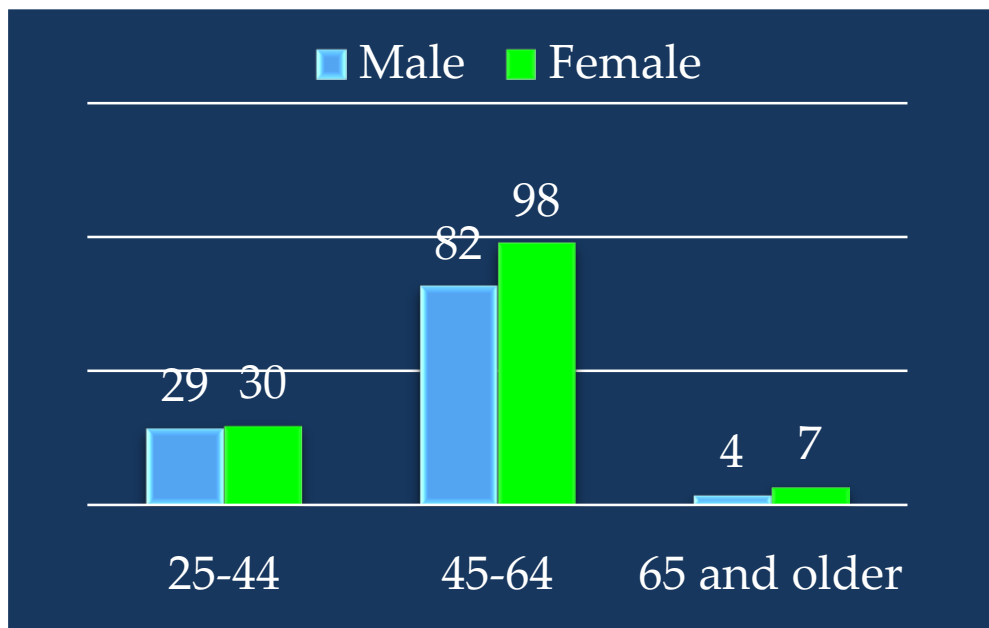


Figure 2. Distribution of implants by gender and age

Identical protocols of selection, preoperative examination, surgical phase of implantation and postoperative treatment were used for all patients. All patients were divided into 2 groups - patients who underwent implantation with a standard protocol (group I) and patients who underwent immediat-implantation (group II) (Fig. 3).

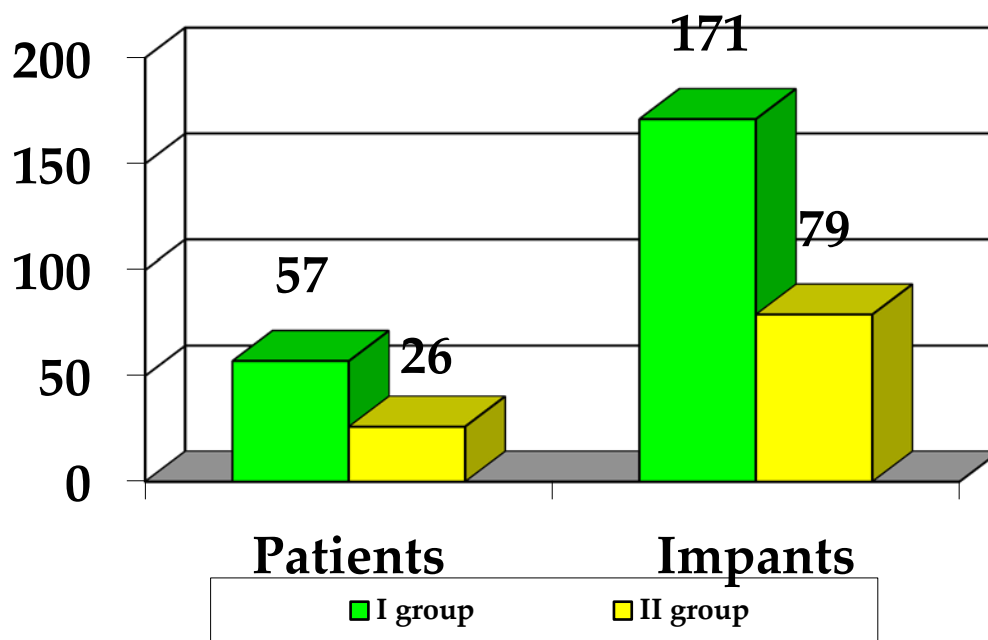


Figure 3. Distribution of researched groups

X-ray computed tomography were done for a more detailed examination of quantitative and qualitative characteristics of the bone of the upper and lower jaws held by scanner on Planmeca ProMax 3D Max (Finland) with 0.3 mm thickness of slice. Further analysis of 3D image was carried in a special program Planmeca Romexis Viewer. The clinical success of dental implants was evaluated due to the dynamics of bone resorption, conditions of periimplant tissue, results of functional studies and evaluation of the primary stability of the implant.

Changes of soft tissues and levels of the medial and distal papillae were evaluated by taking photos with a digital camera Nikon P 90 before extraction, after implantation and fixation of temporary crowns, at 3 months, 6 months after fixation of permanent crowns, and 12 months after implantation (due to Kan J.Y.S., 2004) [3,4].

Measurement of marginal bone level loss at medial and distal sides of the implant were evaluated by the series of periapical X-ray images. Apical edge of orthopedic implant platform was chosen as starting line. Marginal bone level measurement was carried out by X-ray due to method of Rungcharassaeng K. et al., 2002 [1,2]. The dynamics of bone resorption at the cervical area of implant was determined using software package "Trophy" by "Sirona". The measurements were performed after 3, 6 and 12 months after implantation. Radiography was performed by using parallel technology positioner Rinn XCP (XCP post bite blocks54-0862), Dentsply for an objective comparison of the results of measurements in different terms. Measurements were performed in the medial and distal directions from cervix of implant.

Depth test was conducted at 4 sites (buccal, lingual, medial, distal) with a pressure sensitive mechanical plastic probe for clinical quantitative and qualitative assessment of the severity of peri-implant changes. The distance from the gingival margin to the bottom of sulcus was measured to the nearest mm.

Overall satisfaction criteria of implant treatment was provided to determine the verification success rate of implantation. For this purpose all participants were offered to fill in a questionnaire with questions (criteria): comfort, layout, ability to chew food, the ability to speak, the ability to clean the implants, the overall satisfaction. Each factor can be assessed by the four-point scale: 1) fine; 2) good; 3) satisfactorily; 4) unsatisfactory.

Results and discussion. The structure of tooth loss causes of patients from researched groups had next distribution: complicated caries - 68%, periodontitis - 20%, trauma - 12%. An analysis of bone quality and quantity based on the classification of types of bone tissue proposed by Misch (1999) in patients of both studied groups revealed that the most frequently met is III type of bone, slightly less prevalent are II and IV bone types, and the I type is the unexpanded and mostly can be found at mandible. III type of bone often were found at the upper jaw, the II type in the frontal areas and type IV in lateral regions. Most lateral sides of the maxilla had IV type of bone. In lateral areas of the mandible IV type of bone was rarely encountered, and found just in cases where place was not healed after root extraction.

In patients with II type of bone implants Zircon Prior Flat were used, and Zircon Prior FerroX and Zircon Prior Fortis were used in patients with III-IV types of bone. Zircon Prior implants of different length (8 mm, 10 mm, 12 mm and 14 mm) were used during treatment. In most clinical cases were used implants of 10 and 12 mm. 12 implants with 8 mm length were fixture in the lateral regions of mandible, because installation region was limited by depth of mandibular canal and the internal oblique line. The same 5 implants were installed on the upper jaw. Diameter of implants were 3.75 mm, 4.0 mm, 4.5 mm and 5.0 mm. Implants with a diameter of 3.75 mm and 4.0 mm were often installed in the frontal regions of the upper and lower jaws, whereas 5 mm implants - in the lateral sides.

Not only were the shape of the crown, but harmony of gingival contour taken into the account during assessing the aesthetic result of subsequent prosthetic implant treatment. Recession usually always accompanied with implant restoration. In our studies changes of gums before treatment, and 3 - 6 - 12 months after treatment were respectively $0,36 \pm 0,04$ mm, $0,40 \pm 0,05$ mm, $0,48 \pm 0,05$ mm, $0,55 \pm 0,05$ mm. Changes were statistically significant ($p < 0,001$) and amounted to $0,55 \pm 0,05$ mm in one year. The loss of soft tissue by 1 mm for 1 year observed Bengazi et al [6,7]. Studies of Small and Tarrow [5, 8] found that recession after implantation was 0.85, medial papilla loss at 12 months was 0.47 mm, and distal - 0.78 mm.

Almost all successful implantation statistics based on radiographic measurements while the implant itself is used as an internal standard. An analysis of radiograph images at 3 months after surgery and implantation at the mandible in patients of both researched groups found not high bone resorption level ($0,18 \pm 0,04$ and $0,35 \pm 0,04$ mm, $P < 0,01$). On the upper jaw these measurements were almost 2 times higher. In II group, where was held immediat-implantation protocol, atrophy of the marginal mandibular bone after one year from the medial side of the implant was $0,22 \pm 0,04$ mm, and from distal - $0,26 \pm 0,04$ mm. These data are consistent with Anderson et. al., who observed such effect of marginal bone changes at early loading in 88% of cases.

Long-term prognosis of implantation depends on the integration of implants with bone and soft tissues. Although the average bone resorption of 0.2 mm in the area of integrated

implant considered to be physiological, however late resorption does not necessarily occur in the area of each implant. Late bone resorption is the gradual resorption in the area of the implantation after integration that may eventually lead to the disintegration of the implant. The most likely etiological factors are periimplantitis and occlusal overload. However, literature data can not provide an unambiguous conclusion about the clinical significance of factors affecting late resorption. This determined the feasibility of a meta-study called to evaluate significance of clinical and periodontal impacts on bone resorption in periimplant area. Results of conducted meta-analysis are summarized in Table 1.

Table 1. Effect of clinical and periodontal impacts on bone resorption in periimplant area

Factors	N	Year average resorption M±m, mm	Mombelli hygiene index	Shyller-Pisarev test
Bone type				
type D ₁	35	0,13±0,02	1,22±0,05	2,14±0,09
type D ₂	76	0,13±0,01	1,21±0,04	2,12±0,07
type D ₃	83	0,14±0,03	1,26±0,06	2,21±0,08
type D ₄	56	0,19±0,04	1,51±0,07	2,28±0,09
Implant topography				
Frontal region	43	0,13±0,02	1,32±0,07	2,11±0,06
Lateral region	207	0,14±0,02	1,34±0,06	2,32±0,11
Maxilla	115	0,14±0,02	1,15±0,06	2,14±0,08
Mandible	135	0,13±0,02	0,56±0,07	2,21±0,09
Length:				
<10 mm	17	0,19±0,03	1,40±0,08	2,18±0,08
>10 mm	233	0,12±0,01	1,28±0,03	2,14±0,07
Diameter:				
standard 3,75-4 mm	159	0,14±0,01	1,32±0,07	2,11±0,08
wide 4,5-5 mm	91	0,17±0,07	1,31±0,13	2,24±0,11
Antagonists:				
natural teeth	84	0,08±0,02	1,18±0,12	2,11±0,09
composite	82	0,15±0,02	1,33±0,08	2,21±0,08
ceramics	84	0,15±0,02	1,31±0,07	2,19±0,05

Year average resorption was $0,14 \pm 0,01$ mm, which is consistent with other researches. It was found that the average bone resorption around the implants was greater in the lateral regions, at the upper jaw, in the area of short implants and implants with large diameter ($p < 0,05$). The analysis found that the length of the implant is preventive key of late resorption. When using long implants (length > 10 mm), the average bone resorption was significantly less than in the case of short implants (length < 10 mm) ($P < 0,05$). It is believed that short implants installed in more lateral sides, because of difficult access, the increased value crowns and implant, poor bone quality and anatomical constraints. Pronounced occlusal loading in the side area of posterior

teeth leads to a significant bending moment, which can lead to severe marginal bone resorption. It is also proved that the quality of bone and loading conditions have a significant influence on the success of implantation.

Mandible has thicker cortical layer compared to maxilla, and sponge bone of jaws becomes more loose in the direction from frontal to distal areas. In our study marginal resorption was less in the area of the lower jaw implants and implants in the frontal section, which is consistent with the results of earlier studies.

Interestingly, we found no relationship between the state of soft tissue and bone level change in the area of the implant. In clinical periodontics, on the contrary, a great expression of gingivitis and plaque accumulation is often associated with severe of integration. Our results are consistent with results of Salcetti et al. [9], which demonstrated that plaque and bleeding indices can not be used to evaluate the soft tissues around implants. Therefore, interpretation of clinical data and its impact on marginal bone level change should be made cautiously and final conclusions on this matter requires additional clinical studies.

Obtained data, in our opinion, has significant value because it improves the understanding of factors that influence the late bone resorption in the area of implants and prosthetic efficiency results of treatment with fixed structures. Arguably, the average bone resorption is greater in the area of short implants and implants of large diameter. The most important factors that have influence on the value of resorption appeared to be length and design features of the Zircon Prior implant intraosseus part, and the type of bone in the area of implantation. We have not found a clear relationship between early periimplant pathology and periodontal indications. According to some researchers, only with the express periimplant inflammation could be found some correlation between the periodontal indexes and periimplant bone defects.

Measurements of depth test ranged from 1 to 7 mm, 95.7% of sites had <4 mm. In seven areas identified PD - 5 mm, in five areas - 5 - 6 mm, and in two areas - 7 mm. The average value in the medial area was $2,9\pm 0,7$ mm, buccal - $2,2\pm 0,8$ mm, distal - $2,8\pm 0,9$ mm, lingual - $2,3\pm 0,7$ mm. In 51% of surveyed plots the measurement results were affected by bleeding. Size of plaque was $0,29\pm 0,07$. At 71.9% were found no accumulation of plaque, and in 24.4% the index ranged 1.9, in 2.5% - 2.0.

The implants around which in a term of five years were marked inflammatory phenomena, coupled with the loss of periimplant bone (different peiimplantitis by Jovanovich) amounted to 12.3%. Patients assigned to the group "unsuccessful" implants, depending on the stage of peiimplantitis were provided with proper therapy aimed to stop the progression of bone loss through the control of "plaque" and by the observance of safety measures and the elimination of implant-gingival pockets. In some cases with the periimplantitis of 3-4 class, we managed to restore lost bone using regenerative surgical procedures.

In modern dentistry implant treatment can not be considered successful if the patient is not satisfied with it, even when considering the clinician achieved perfect function and aesthetics. According to Smith and Zarb, «implant should not disturb the establishment of prosthetic restoration, the exterior of which satisfies both the dentist and the patient." Therefore, we conducted a survey of patients who underwent orthopedic treatment based on dental implants. The analysis profiles are presented in Table 2 and Figure 4.

Table 2. Overall satisfaction with implant treatment

Criteria	Excellent	Good	Satisfactory	Unsatisfactory
Comfort	87,0	11,6	1,4	-
Ability to speak	85,5	11,6	2,9	-
Layout	79,7	17,4	2,9	-
Ability to chew	78,3	14,5	7,2	-
Ease of implants cleaning	49,3	37,7	11,6	1,4
Overall satisfaction	81,2	17,4	1,4	-

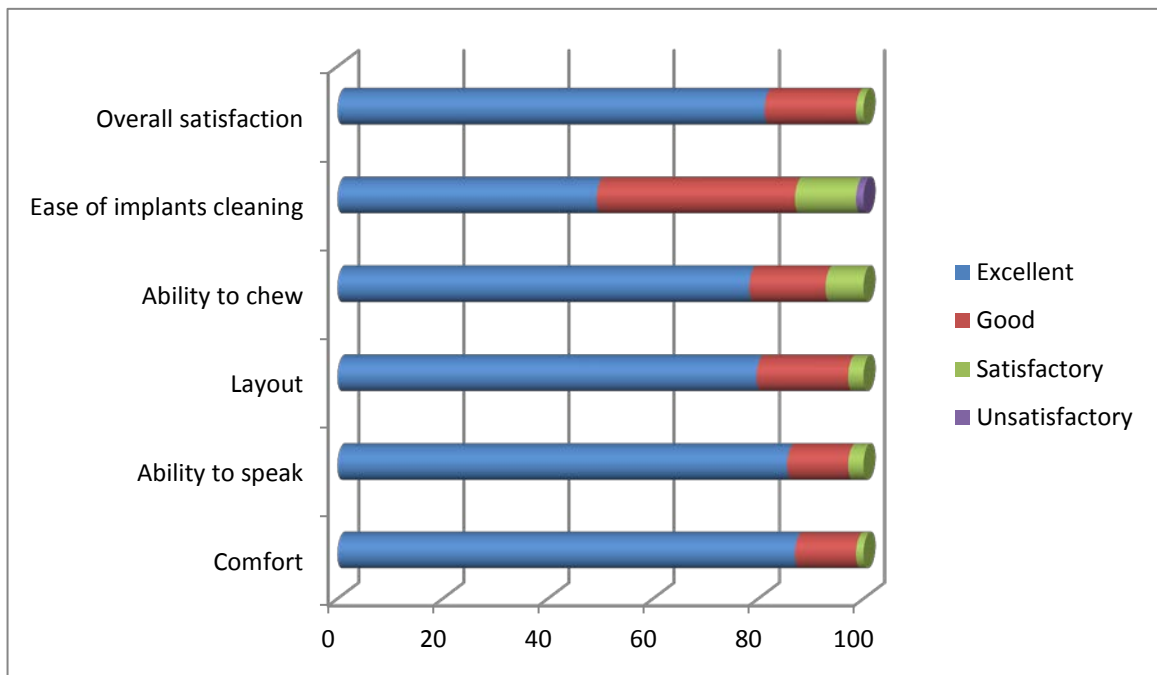


Figure 4. Overall satisfaction with implant treatment.
69 patients completed the questionnaire

The analysis of the survey results showed that the vast majority of patients were satisfied with the treatment, 81.2% rated it as "excellent", 17.4% instill "good." One of the patients assessed as "satisfactory" (1.4%), unsatisfactory ratings were not found. The highest satisfaction fell on factors such as comfort (1.16) and the ability to speak (1.17), followed by layout (1.26), the ability to chew (1.29), ease of cleaning implants was in last place (1.64). Less than 50% of patients given "excellent" evaluation for ease of implants care. In our study, most patients (98.6%) rated the implant treatment as "excellent" or "good." A more detailed analysis of the questionnaires showed that the care of implants is a problem in 10% of cases. Similar results were obtained in the study done by Pjetursson et al [10], where 17% of patients complained of difficulty of implants hygiene.

Conclusion. Immediate installation of Zircon Prior screw implants in tooth socket after extraction provides effective cosmetic result by forming appropriate structure and architecture of

alveolar bone and correct soft tissue contour. Early implant loading and restoration of dentition defect eliminates psychological and emotional trauma, linked to the lack of teeth in an aesthetically significant area, and eliminates the need for temporary removable prosthesis.

Implants, around which at the first year was marked inflammatory phenomena, coupled with the loss of periimplant bone of different severity were presented by 12.3%. Patients assigned to the group "unsuccessful" implants, depending on the stage of pathology were provided with proper implant therapy, while in some cases, even with 3-4 class of periimplantitis, we managed to restore lost bone using regenerative surgical procedures. It was also established that the most important factors that have influence on the value of late bone resorption appeared to be length and design features of the intraosseus part of Zircon Prior implant, and the type of bone in the area of implantation, rather than periodontal parameters. In general, according to the survey, the majority of patients (98.6%) rated the prosthetic treatment supported by Zircon Prior dental implants as "excellent" or "good."

LITERATURE

1. Potapchuk A.M., Sharkany J. P. et al. Biocompatible gradient ceramic coatings for metal implants //6th Annual International Symposium on NDE for Health Monitoring and Diagnostics. – International Society for Optics and Photonics, 2001. – С. 219-223.
2. Потапчук А. М. Фактори ризику дентальної іммедіат-імплантації //Науковий вісник Ужгородського університету. Сер.: Медицина. – 2010. – №. 39. – С. 224-229.
3. Kan J. Y. K. et al. Dimensions of peri-implant mucosa: an evaluation of maxillary anterior single implants in humans //Journal of periodontology. – 2003. – Т. 74. – №. 4. – С. 557-562.
4. Kan J. Y. K. et al. Clinical methods for evaluating implant framework fit //The Journal of prosthetic dentistry. – 1999. – Т. 81. – №. 1. – С. 7-13.
5. Goodacre C. J. et al. Clinical complications with implants and implant prostheses //The Journal of prosthetic dentistry. – 2003. – Т. 90. – №. 2. – С. 121-132.
6. Bengazi F., Wennström J. L., Lekholm U. Recession of the soft tissue margin at oral implants. A 2-year longitudinal prospective study //Clinical Oral Implants Research. – 1996. – Т. 7. – №. 4. – С. 303-310.
7. Bengazi F. et al. Osseointegration of implants with dendrimers surface characteristics installed conventionally or with Piezosurgery®. A comparative study in the dog //Clinical oral implants research. – 2014. – Т. 25. – №. 1. – С. 10-15.
8. Small P. N., Tarnow D. P. Gingival recession around implants: a 1-year longitudinal prospective study //The International journal of oral & maxillofacial implants. – 1999. – Т. 15. – №. 4. – С. 527-532.
9. Salcetti J. M. et al. The clinical, microbial, and host response characteristics of the failing implant //The International journal of oral & maxillofacial implants. – 1996. – Т. 12. – №. 1. – С. 32-42.
10. Pjetursson B. E. et al. Comparison of survival and complication rates of tooth-supported fixed dental prostheses (FDPs) and implant-supported FDPs and single crowns (SCs) //Clinical Oral Implants Research. – 2007. – Т. 18. – №. s3. – С. 97-113.