

MINISTRY OF EDUCATION AND SCIENCE OF UKRAINE
State Higher Educational Institution
“UZHGOROD NATIONAL UNIVERSITY”
MEDICAL FACULTY
DEPARTMENT OF OBSTETRICS AND GYNECOLOGY

Authors: As.Prof. Lemish N.Y.
Ph.D, prof. Korchinska O.O.

Topic: Diseases of the female reproductive system. Part I.

*Methodical development for practical lessons of gynecology for students of the 5th
course of medical faculty*

2

Uzhgorod - 2015

ABBREVIATIONS

MC – Menstrual cycle
FSH - Follicle Stimulating Hormone
AMN - Anti –Mullerian Hormone
LH – Luteinizing hormone
DUB – dysfunctional uterine bleeding
D&C – dilatation and curettage
PCOS – Polycystic ovarian syndrome
PMS – premenstrual syndrome
COC- combined oral contraceptives

CONTENS

Abbreviations

1. Preface.....	5
2. The subject of obstetrics and gynecology. Organization of obstetric care in Ukraine.....	6
3. Clinical anatomy and physiology of female genitalia.....	16
4. Disorders of the menstrual cycle. Neuroendocrine syndromes in gynecological practice.....	28
5. Endometriosis. Gynecological diseases of children and teens. Abnormalities of female genitalia position and development.....	38
6. Benign diseases of female reproductive organs. Gynecological aspects of mammary glands diseases.....	52

PREFACE

According to the conception of state program “Reproductive health of nation for 2006-1015 years” the low level of birth level and the high level of total mortality push forward the problem of reproductive health and the duration of life in the rank of nationwide, and the preservation of the reproductive health goes far beyond the ranks of pure medical issues and is becoming a national, cross-sectoral issue. The preservation of the reproductive health is established on the global level by the WHO as a priority branch according to the resolution of the World Assembly of health care of UN from 1995.

The knowledge of the basis of gynecological diseases, methods of their investigation, differential diagnosis and treatment is needed for every practical doctor. The relevance of this topic is based on the fact that only early diagnosis and treatment may prevent the development of further complications and preserve the reproductive health of the future mother.

The subject of obstetrics and gynecology. Organization of obstetric care in Ukraine.

Obstetrics (from the Latin *obstare* - "to stand by" or from the France *accoucher* – to take delivery) is the health profession or medical specialty that deals with pregnancy, childbirth, and postpartum period (including care of the newborn). It encompasses a variety of health care practices evolved to maintain and restore health by the prevention and treatment of illness in human beings. In addition to being a medical specialty, obstetrics is the study of the reproductive process within the female body, including fertilization, pregnancy and childbirth.

Gynaecology or gynecology is the medical practice dealing with the health of the female reproductive system (vagina, uterus and ovaries) and the breasts. Literally, outside medicine, it means "the science of women". Its counterpart is andrology, which deals with medical issues specific to the male reproductive system. The word "gynaecology" comes from the Greek *gyne* - "woman" and *-logia* - "study."

Almost all modern gynecologists are also obstetricians. In many areas, the specialties of gynecology and obstetrics overlap.

History

Prior to the 18th century, caring for pregnant women in Europe was confined exclusively to women, and rigorously excluded men. The expectant mother would invite close female friends and family members to her home to keep her company. Skilled midwives managed all aspects of the labour and delivery. The presence of physicians and surgeons was very rare and only occurred once a serious complication had taken place and the midwife had exhausted all measures to manage the complication. Calling a surgeon was very much a last resort and having men deliver women in this era whatsoever was seen as offending female modesty.

Leading up to the 18th Century

Obstetrics prior to the 18th and 19th centuries was not recognized on the same level of importance and professionalism as other medical fields, until about two hundred years ago it was not recognized as a medical practice. However, the subject matter and interest in the female reproductive system and sexual practice can be traced back to Ancient Greece[14] and even to Ancient Egypt.[15] Soranus of Ephesus sometimes is called the most important figure in ancient gynecology. Living in the late first century A.D. and early second century he studied anatomy and had opinions and techniques on abortion, contraception –most notably *coitus interruptus*– and birth complications. After the death of Soranus, techniques and works of gynecology declined but very little of his works were recorded and survived to the late 18th century when gynecology and obstetrics reemerged.[16]

18th century

The 18th century marked the beginning of many advances in European midwifery. These advances in knowledge were mainly regarding the physiology of pregnancy and labour. By the end of the century, medical professionals began to understand the anatomy of the uterus and the physiological changes that take place during labour. The introduction of forceps in childbirth also took place during the 18th century. All these medical advances in obstetrics were a lever for the introduction of men into an arena previously managed and run by women—midwifery. The addition of the male-midwife is historically a significant change to the profession of obstetrics. In the 18th century medical men began to train in area of childbirth and believed with their advanced knowledge in anatomy that childbirth could be improved. In France these male-midwives were referred to as "accoucheurs". This title was later on lent to male-midwives all over Europe. The founding of lying-hospitals also contributed to the medicalization and male-dominance of obstetrics. These lying-hospitals were establishments where women would come

to have their babies delivered, which had prior been unheard of since the midwife normally came to home of the pregnant woman. This institution provided male-midwives or accoucheurs with an endless number of patients to practice their techniques on and also was a way for these men to demonstrate their knowledge.[18]

Many midwives of the time bitterly opposed the involvement of men in childbirth. Some male practitioners also opposed the involvement of medical men like themselves in midwifery, and even went as far as to say that men-midwives only undertook midwifery solely for perverse erotic satisfaction. The accoucheurs argued that their involvement in midwifery was to improve the process of childbirth. These men also believed that obstetrics would forge ahead and continue to strengthen.[12]

19th century

Even 18th century physicians expected that obstetrics would continue to grow, the opposite happened. Obstetrics entered a stage of stagnation in the 19th century, which lasted until about the 1880s.[11] The central explanation for the lack of advancement during this time was substantially due to the rejection of obstetrics by the medical community. The 19th century marked an era of medical reform in Europe and increased regulation over the medical profession. Major European institutions such as The College of Physicians and Surgeons considered delivering babies ungentlemanly work and refused to have anything to do with childbirth as a whole. Even when Medical Act 1858 was introduced, which stated that medical students could qualify as doctors, midwifery was entirely ignored. This made it nearly impossible to pursue an education in midwifery and also have the recognition of being a doctor or surgeon. Obstetrics was pushed to the side.[19]

PictureThe historic taboo associated with the examination of female genitalia has long inhibited the science of gynaecology. This 1822 drawing by Jacques-Pierre Maygnier shows a "compromise" procedure, in which the physician is kneeling before the woman but cannot see her genitalia. Modern gynaecology has shed these inhibitions.

By the late 19th century the foundation of modern day obstetrics and midwifery began develop. Delivery of babies by doctors became popular and readily accepted, but midwives continued to play a role in childbirth. Midwifery also changed during this era due to increased regulation and the eventual need for midwives to become certified. Many European countries by the late 19th century were monitoring the training of midwives and issued certification based on competency. Midwives were no longer uneducated in the formal sense.

As midwifery began to develop so did the profession of obstetrics near the end of the century. Childbirth was no longer unjustifiably despised by the medical community as it once had been at the beginning of the century. But the specialty was still behind in its development stages in comparison to other medical specialities, and remained a generality in this era. Many male physicians would deliver children but very few would have referred to themselves as obstetricians. The end of the 19th century did mark a significant accomplishment in the profession with the advancements in asepsis and anesthesia, which paved the way for the mainstream introduction and later success of the Caesarean Section.[20][21]

Before the 1880s mortality rates in lying-hospitals would reach unacceptably high levels and became an area of public concern. Much of these maternal deaths were due to Puerperal fever, at the time commonly known as childbed fever. In the 1800s Dr. Ignaz Semmelweis noticed that women giving birth at home had a much lower incidence of childbed fever than those giving birth by physicians in lying-hospitals. His investigation discovered that washing hands with an antiseptic solution before a delivery reduced childbed fever fatalities by 90%.[22] So it was concluded that it was physicians who had been spreading disease from one laboring mother to the next. Despite the publication of this information, doctors still would not wash. It was not until the 20th century when advancements in aseptic technique and the understanding of disease would play a significant role in the decrease of maternal mortality rates among many populations.

Historical Role of Gender

Women and men inhabited very different roles in natal care up to the 18th century. The role of a physician was exclusively held by men who went to university, an overly male institution, who would theorize anatomy and the process of reproduction based on theological teaching and philosophy. Many beliefs about the female body and menstruation in the 17th and 18th centuries were inaccurate; clearly resulting from the lack of literature about the practice.[27] Many of the theories of what caused menstruation prevailed from Hippocratic philosophy.[28] Midwives of this time were those assisted in the birth and care of both born and unborn children, and as the name suggests this position held mainly by women.

During the birth of a child, men were rarely present. Women from the neighborhood or family would join in on the process of birth and assist in many different ways. The one position where men would help with the birth of a child would be in the sitting position, usually when performed on the side of a bed to support the mother.[29]

Men were introduced into the field of obstetrics in the nineteenth century and resulted in a change of the focus of this profession. Gynecology directly resulted as a new and separate field of study from obstetrics and focused on the curing of illness and indispositions of female sexual organs. This had some relevance to some conditions as menopause, uterine and cervical problems, and childbirth could leave the mother in need of extensive surgery to repair tissue. But, there was also a large blame of the uterus for completely unrelated conditions. This led to many social consequences of the nineteenth century.[27]

Historical Positions

The process in the past of birthing a child began with very little preparation; improvisation was the rule of thumb. Dilation was determined mostly by touch and described by obstetricians and midwives very differently. Midwives would refer to the dilation of the cervix by comparing it to body parts, such as the palm of the hand, a finger, or even a fist. Obstetricians, usually men who had experience with using coins would refer to the dilation by relation to the size of currency.[6] The woman birthing the child would have topical remedies available to calm her nerves, ease pain and encourage her to deliver the baby hastily. The birthing mother was also able to decide her position of delivery as opposed to the standard laying down practice today. There were two main categories of positions, vertical and horizontal. These are expanded upon below.

Crouching

An instinctive position, this ensured full use of gravity to the mother's advantage, and if the child appears suddenly, ensures safety from falling from a height and being injured. This position was most common when a woman was unattended and essentially without help. If necessary, the mother could watch her perineum and disengage the head of the baby herself. Common practice in many cultures apparently thought it essential to lay the newborn upon the ground as a connection to the earth and this position allowed the child to arrive with immediate contact with the ground. Downsides of this position are it requires great stamina and that the woman be fully nude below the waist.[6]

Kneeling

This position was common in the nineteenth century French provinces and by peasant women. The position called for knee protection and upper limb support, involving possibly a cushion and chair back or by being suspended between two chairs backs if alone.

Downsides to this position were that it caused back aches and cramps. Also, doctors considered it inferior due to the baby being received behind the mother. When a fetus underwent malpresentation (misalignment of the fetus, with the head not exiting the womb first) or when the womb was extremely protruding or comparatively large to the woman, she may have knelt on the ground with hands placed on the ground in front of her. Doctors of the enlightenment period thought this 'on all fours' position was too animalistic and indecent, and should be avoided.[6]

Sitting

A sitting position would be used in some cases for women who could not squat for extended periods of time. It was reinvented with the creation and use of the birthing stool. Contrary to the name, this could be either a stool or a chair with a large hole in the seat to use gravity to align

and birth the child while supporting the weight of the mother. With the stool variation and the side of the bed position, another person would be used to support the mother's upper body.[6]

Standing

Accidentally happening or deliberate, this position was rarely used due to the stamina required to do so as well as the tendency for mothers to teach their daughters how to birth otherwise.

Daughters who hid their pregnancy could be caught standing and having their water break, instinctively these girls would brace themselves against a wall, table, chair and with the inability to move would deliver the baby there, allowing it to fall on the ground. This, of course, was extremely dangerous although in the seventeenth and eighteenth centuries, various textbooks show the persistence of the standing position with it persisting until the beginning of the twentieth century in some areas of France.[6]

Horizontal

Compared to the other four vertical positions, this was certainly believed not instinctive and did not provide the labour with the necessary conditions to birth. Today we also know this position is inferior to the vertical positions as it increases the change of fetal distress as malpresentation. It also decreases the space available in the pelvis, as the sacrum is unable to move backwards as it does naturally during labour. This method of childbirth developed after the introduction of the birthing stool and with the change in concentration of births in homes to hospitals. This position was used for women who had some difficulty in bringing the fetus to birth. Women only resorted to lying down especially on the bed because it would mean that the bedclothes would be soiled in the process. It was also avoided because it showed determination and was significant in showing difference from animals that lay down to give birth. This is similar to the resistance to giving birth on all fours.[6]

A sixth position was used in some instances of a poor household, in the countryside and during the winter. It was a combination of the sitting position and laying position usually by a combination of small mattress and a fallen chair used as a backrest. This method was also greatly avoided and only used at the request of the mother because it required that the person helping birth the child—usually an obstetrician and not a midwife at this point—to crouch on the ground, working at nearly ground level.[6]

The Birthing Stool

The birthing stool—sometimes known as a birthing chair—was introduced in the seventeenth and the use of it was encouraged into the eighteenth century by the doctors and administrators who used it to control the child being birthed. The stool was usually very expensive and came in two types. The more expensive and heavier variety was used by wealthy families as a family heirloom—and typically was adorned with decoration or expensive materials. The second variety was used by village midwives as was lighter and portable so the midwife could carry it from home to home. It became popular in the French territory of (mostly German speaking) Alsace-Lorraine. At the beginning of the 19th century, the birthing stool's use changed, as increased weight restricted its use to medical facilities. It, perhaps indirectly, evolved into the modern delivery table. This contributed to the transition to the modern day hospital setting.[7] This was usually not the method of choice for many mothers, as the stool was very revealing, cold, and later became associated with the pain of childbirth. To decrease the draft on a woman's genitals as she sat on the birthing stool, fabric was draped around the seat. This also provided a bit of privacy and respected the modesty of the mother.

Examination

In Ukraine, women must first see a general practitioner (GP; also known as a family practitioner (FP)) prior to seeing a gynecologist. If their condition requires training, knowledge, surgical procedure, or equipment unavailable to the GP, the patient is then referred to a gynecologist. In Ukraine, however, law and many health insurance plans allow gynecologists to provide primary care in addition to aspects of their own specialty. With this option available, some women opt to see a gynecological surgeon for non-gynecological problems without another physician's referral.

As in all of medicine, the main tools of diagnosis are clinical history and examination. Gynecological examination is quite intimate, more so than a routine physical exam. It also requires unique instrumentation such as the speculum. The speculum consists of two hinged blades of concave metal or plastic which are used to retract the tissues of the vagina and permit examination of the cervix, the lower part of the uterus located within the upper portion of the vagina. Gynecologists typically do a bimanual examination (one hand on the abdomen and one or two fingers in the vagina) to palpate the cervix, uterus, ovaries and bony pelvis. It is not uncommon to do a recto-vaginal examination for complete evaluation of the pelvis, particularly if any suspicious masses are appreciated. Male gynecologists may have a female chaperone for their examination. An abdominal and/or vaginal ultrasound can be used to confirm any abnormalities appreciated with the bimanual examination or when indicated by the patient's history.

Organization of obstetric care in Ukraine

General principles of obstetric and neonatal care are based on the concept of WHO for rational management of labor (1996), the concept of safe motherhood and on the basis of the state to implement an active demographic politics.

Organization of obstetric care in Ukraine consists of three major stages:

1. The organization of family planning services as the basis of formation reproductive health;
2. The organization of obstetric care based on the principles of safe motherhood;
3. The organization of gynecological care based on the principles of rehabilitation reproductive health as an essential prevention factor of oncological diseases.

The system of **family planning (FP)** in Ukraine belongs to one of the youngest subsystems of healthcare in Ukraine.

11 Family planning is the planning of when to have children, and the use of birth control and other techniques to implement such plans. Other techniques commonly used include sexuality education, prevention and management of sexually transmitted infections, pre-conception counseling and management, and infertility management.

Family planning is sometimes used as a synonym or euphemism for the use of birth control, however, it often includes a wide variety of methods, and practices that are not birth control. It is most usually applied to a female-male couple who wish to limit the number of children they have and/or to control the timing of pregnancy (also known as spacing children). Family planning may encompass sterilization, as well as abortion.

Family planning services are defined as "educational, comprehensive medical or social activities which enable individuals, including minors, to determine freely the number and spacing of their children and to select the means by which this may be achieved".

The organization of structural units of the family planning system is carried out in accordance with the level to provide consultative medical care. Maternity care includes pregnancy (antenatal) care, labour and birth (intrapartal) care, and care following birth (postnatal). Care can be provided in a number of settings, these being:

- as an outpatient in a hospital or community clinic
- as an in-patient through hospital admission
- in the community
- in the home.

Care in pregnancy and childbirth is provided by a range of health care professionals (both public and private) including general practitioners, obstetricians, midwives as well as maternal and child health nurses provided by local government.

Labour, birth and postnatal services include:

- a. all primary maternity care from the time of established labour, from initial assessment of the woman at her home or at a maternity facility, and regular monitoring of the progress of the woman and baby,
- b. management of the birth,
- c. all primary maternity care until 2 hours after delivery of the placenta, including updating the care plan, attending the birth and delivery of the placenta, suturing of the perineum (if required), initial examination and identification of the baby at birth, initiation of breast feeding (or feeding), care of the placenta, and attending to any legislative requirements regarding birth notification by health professionals.

Primary Health Care (PHC)

The strategy for achieving the goal of "Health for All" emerged in 1978 at an historic conference in Alma-Ata in the former Soviet Union. The conference was sponsored by the United Nation Children's Fund (UNICEF) and WHO. Prior to the Alma-Ata Conference, WHO had identified eight components common to nine successful health programs. The code words "Primary Health Care" (PHC) were selected to describe the following eight components in combination:

- education about common health problems and what can be done to prevent and control them;
- maternal and child health care, including family planning;
- timely identification of pregnant women and the dynamic control of them in cooperation with the obstetrician-gynecologist;
- prevention and control of sexually transmitted diseases;
- organization of preventive examinations of female population;
- basic sanitation;
- timely identification of women with severe pathology for which pregnancy threatens the health or life, for the purpose of directing them to a higher health care level;
- appropriate treatment for common diseases and injuries.

12

Level I includes - midwifery and first aid stations, district hospitals, outpatient clinics and family doctor ambulatory.

At the primary health care level in rural areas and cities, it is necessary to determine units that are to provide the primary medical care. Primary health care (PHC) refers to "essential health care" that is based on scientifically sound and socially acceptable methods and technology, which make universal health care universally accessible to individuals and families in a community. It is through their full participation and at a cost that the community and the country can afford to maintain at every stage of their development in the spirit of self-reliance and self-determination". In other words, PHC is an approach to health beyond the traditional health care system that focuses on health equity-producing social policy. PHC includes all areas that play a role in health, such as access to health services, environment and lifestyle. Thus, primary health care and public health measures, taken together, may be considered as the cornerstones of universal health systems.

Secondary health care level (SHC)

Secondary Maternity Services are those provided where women and / or their babies experience complications that need additional maternity care involving Obstetricians, Pediatricians, other Specialists and secondary care teams.

At the secondary health care level the network of central district and regional hospitals, central municipal, municipal and district hospitals and independent municipal clinics should be designed in accordance with the needs of the population, territorial accessibility, disease incidence and other criteria. It is reasonable to create a multi-field hospital of intensive treatment that will ensure the provision of specialized medical care as well as entire medical assistance throughout the region.

The secondary Medicare in towns is provided by the city many-types incorporated hospitals and medical sections, in villages there are central district and district hospitals. The secondary

specialized treatment-prophylactic aid to the rural population is given in district medical establishments, municipal family planning offices, antenatal clinics (women's consultations), obstetric and gynecological departments, maternity hospitals, services for Child and Adolescent Gynecology, children's clinics.

Secondary and tertiary maternity facilities will have sufficient assessment, antenatal, birth and postnatal rooms for the population serviced by the secondary and tertiary maternity services, and for the level of service provided. Facilities should also have sufficient assessment, antenatal, birth and postnatal rooms for primary births that take place in the secondary and tertiary facilities.

The leading establishments are central district hospitals that also carry out a role of organizationally medical centers in organization and quality of giving the Medicare.

The basic tasks of CDH are:

- direct giving of primary ambulatory-policlinic aid to the population of district centre and attached area;
- giving of the specialized ambulatory-policlinic aid to all the population of the district;
- giving of the specialized stationary aid to all the population of the district;
- providing quick and urgent Medicare to population;
- introduction into the practice of the district's TPE* (treatment-prophylactic establishments) of work modern methods and facilities of prophylaxis, diagnostics and treatment;
- organization of consultative aid;
- organizationally-methodical guidance of the work of all district's TPE, and also control work of their activity;
- development and introduction of measures which are directed to upgrade the quality of medical providing;
- development, organization and realization of measures which can raise qualification of medical personnel; rational usage of medical personnel's and materially-technical resources;
- planning, financing and organization of the materially-technical support of the district's health care establishments;
- qualification raising of medical staff of the district and section TPE.

**TPE - treatment-prophylactic establishments*

City hospitals provide about the third part of given Medicare.

Greater part of the city station establishments is united with policlinics, but the independent specialized hospitals also exist.

The main tasks of city hospital are:

- giving of the specialized round-the-clock stationary aid in a sufficient quantity;
- approbation and introduction of modern methods of diagnostics, treatment and prophylaxis;
- complex treatment;
- examination of disabled;
- hygienically education of population.

The facilities will include adequate space, equipment and consumables for:

- LMCs to undertake acute clinical consultations and examinations including antenatal cardiotocographs (CTGs) or other clinical examinations for assessment
- monitoring progress of labour and assisting with facilitating births
- equipment and services for caesarean section and assisted vaginal deliveries
- emergency resuscitation and care of mother
- emergency resuscitation and care of the newborn until transfer of care to neonatal services, if necessary
- newborn hearing screening.

Every stationary department consists of chambers and other premises for medical and economic aim (operating block, bandaging, cabinet for manipulations, intern, cabinets of the Head of the

department and of the senior nurse. In order to isolate patients in the infectious hospitals the boxes are prepared.

In the induction center a doctor get acquainted meets with the facts of medical documents, makes an examination, gives necessary urgent aid and sends a patient to the proper department. The induction center provides the order of direction to permanent establishment and conducts:

- registration of patients, that come to permanent establishment and leave it, filling the passport part of the in-patient card;
- establishing of diagnosis;
- substantiation of hospitalizations;
- giving the urgent (aid) aid if it is necessary;
- sanitary treatment;
- taking the material for laboratory researches, express-diagnostics, roentgen- and functional researches; determination of type of the specialized department;
- registration of refusals in hospitalization with determination of reasons;
- giving the additional information for the hospitalized patients.

Except of chamber, the following posts of such nurses are set:

- operating-room;
- bandaging;
- of the dietary feeding;
- medical sister for organization of individual care of seriously sacking;
- procedural cabinet;
- physiotherapy, massage.

Tertiary health care level

14

WHPO gives to it such determination: it is the aid, that needs highly skilled service, which as a rule can be given only in the centers and hospitals which passed the proper specialization and are specially equipped to that aim.

According to the „Bases of Ukrainian legislation of health care” the tertiary medically-sanitary aid (MSA) is given by a doctor or a group of doctors who have the proper preparation in the field of diseases which are difficult for diagnostics and treatment, in the case of treatment of illnesses which need the special methods of diagnostics and treatment. And also with the purpose of establishment of diagnosis and conducting of treatment of diseases which are rarely met.

At the tertiary health care level a highly specialized health care level should function, which will be ensured by regional hospitals, higher medical education institution departments and institutes for scientific research. Specialist hospitals (also known as tertiary hospitals) provide statewide services for women with complex or high risk pregnancies.

Two functions of these establishments are considered to be basic:

- organizationally-methodical guidance of the secondary level of MSA;
- giving to the patients highly skilled and strictly specialized Medicare.

Women are best supported when they receive maternity care close to their home and for some women this will mean birthing in a tertiary hospital. Women requiring higher levels of care will be referred to an appropriate service by their general practitioner or hospital and this may require women to travel.

Eligible women and their babies assessed as needing additional care during the antenatal, labour and birth, and postnatal period until six weeks after the birth, will have access to the secondary and / or tertiary services that are clinically indicated for their individual need. Eligible women who do not require secondary or tertiary services may access secondary or tertiary facilities for labour and birth, and the postnatal period. You will ensure that these women receive primary maternity services, as secondary and / or tertiary services are not clinically indicated.

Consultative policlinic is the separate structural subsection of establishment of tertiary MSA.

The narrow specialized departments of permanent establishment, auxiliary treatment-prophylactic subsections, clinical, biochemical and bacteriological laboratories, separations of

functional diagnostics, path anatomical, physical therapy and radiological departments) are obligatory.

Secondary and Tertiary Maternity Services:

a.) during specified times during normal working hours, a non-acute outpatient service for the assessment, diagnosis and treatment of women and their babies who are referred to the secondary or tertiary maternity service;

b.) a 24 hour / day Outpatient service for the acute assessment, diagnosis and treatment of women and their babies who are referred to the secondary or tertiary maternity service in accordance with the Maternity Referral Guidelines;

c.) a 24 hour/day, Inpatient service for women and their babies whose care is transferred to the secondary or tertiary maternity service;

d.) a follow up service providing consultation with a Specialist, where appropriate until 6 weeks after birth.

The service includes, but is not limited to:

a. the assessment, diagnosis and treatment of women who require a consultation with an Obstetrician or other Specialist and who are referred to the secondary or tertiary service;

b. the assessment, diagnosis and treatment of women whose care is transferred to the secondary or tertiary maternity service;

c. provision of, or facilitation of access to, amniocentesis or chorion villus procedure and tests where there is an increased risk assessment / screening result;

d. authorising, giving advice on, and performing inductions ;

e. anaesthesia services for consultation relating to analgesia in labour which might include administration of epidural analgesia and its ongoing management, care and follow up of the woman;

f. all care in association with complicated deliveries, including operative vaginal deliveries and caesarean sections;

g. midwifery care for woman and her baby when clinical responsibility is with the secondary or tertiary maternity services team, including in cases where the clinical responsibility for the woman's care has been transferred to the secondary or tertiary team;

h. assessment, diagnosis and treatment of pregnant women and / or newborn babies who require a consultation with the neonatal service;

i. lactation advice from a lactation consultant midwife in line with referral criteria.

The following services are to be provided as an integral part of these services:

- professional services – medical, nursing and allied health
- pathology services, including referrals to private laboratories by hospital medical practitioners
- diagnostic imaging services, including referrals to private diagnostic imaging services by hospital medical practitioners
- other diagnostic services referred to by hospital medical practitioners, eg,
- cardiography, spirometry, audiology, neurological testing
- operating theatres
- anaesthetic services
- sterile supply services
- pharmacy services
- nuclear medicine
- coronary care
- intensive care
- blood transfusion services
- supply or loan of equipment to support treatment, rehabilitation or aid mobility
- infection control

The department of urgent and planly-consultive aid is other important structural unit of the regional hospital. In its structure there is a 24-hour's dispatcher service of reception and registration of calls from the hospitals of districts and cities of the region. The specialists of regional hospital and other TPE regions employees of higher medical institutes, research institutes are attracted, to the giving of urgent and planly-consultive aid on the agreement with the corresponding establishments and institutions. To engage into this work employees, the special order is given out at the Management of health care.

Clinical anatomy and physiology of female reproductive system. Methods of gynecological investigation.

Amount of hours: 4 hours in practical classes

The topic includes the learning of: anatomy of external genitalia, vagina, uterus and its parts, uterus function, ovaries and their function. Suspensory ligaments of the uterus. Blood supply and lymphatic system. Physiological changes in female reproductive organs at different ages. Modern knowledge about the menstrual function. Neuroendocrinological regulation of the female reproductive system function. Role of hormones and biological active substances. General and special methods of gynecological investigation: bimanual, vaginal, rectal, speculum. Peculiarities of gynecological history taking. Methods of diagnosing the functional state of the ovaries. Biopsy. Culdocentesis. Endoscopic methods of investigation. Colposcopy, hysteroscopy, cystoscopy, laparoscopy. Laboratory diagnostics.

Questions for the modular control:

1. General and specific methods of examination of gynecological patients.
2. Bimanual, vaginal and rectal examinations. Speculum examination.
3. Methods of diagnosing the functional state of the ovaries.
4. History taking, estimation of the laboratory investigations (general and biochemical blood tests, urine blood coagulation, etc.)
5. Taking material from the vagina, urethra and cervical canal.
6. Evaluate the results of colpocytological study.
7. Evaluate the results of colposcopy.
8. Evaluate the diagnostic tests of the ovaries function.
9. Evaluate the results of the cytological, histological and bacteriological investigation.
10. Evaluate results of X-ray of female genitalia.
11. Estimate results of pelvic sonography.
12. Plan the investigations of patients with various gynecological diseases.

The external genitalia include: pudendal cleft, mons pubis, labia majora, labi minora, clitoris, Bartholin's gland. Internal genitalia include: vagina, uterus, fallopian tubes and ovaries.

The perineum consists of muscles, that may be divided into 3 layers.

- The 1st or superficial layer consists of m. m. ischiocavernosus, m. bulbocavernosus, m. constrictor cuni, m. sphincter ani externum, m. transversus perinei superficialis.
- The 2nd layer is called diaphragm urogenitale consists of m. sphincter urethrae, m. transversus perinei profundus.
- The 3rd, inner layer is called diaphragm pelvis consists of m. levator ani, that has three parts - m.pubococcygeus, m.ischiococcygeus, m.ileococcygeus

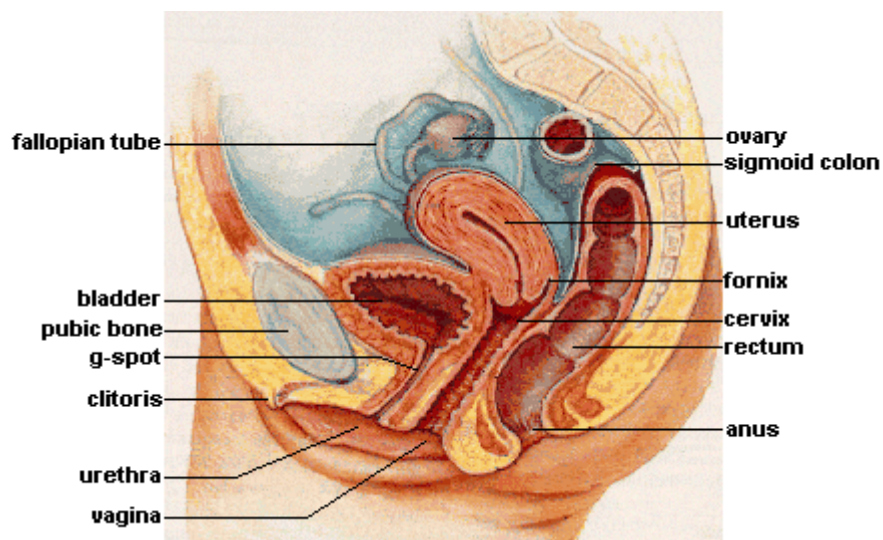
Mons pubis. Is formed by the prominent parts of the tubercles of the pubis bones with well developed subcutaneous adipose tissue and hairy part in the shape of triangle (the female type of hair distribution).

Labia majora. The two thick cutaneous creases with very well developed subcutaneous fat tissue. The external part is covered with hair, the inner part contain sweat and sebaceous glands.

Labia minora. Cutaneous creases, that are similar to mucosa layer. In front they proceed into clitoris, from behind they join with labia majora. Labia minora do not have hair, neither sweat, nor mucosa glands. They are covered with stratified squamous epithelium.

Bartholin's glands are two pea sized compound racemose glands located slightly posterior and to the left and right of the opening of the vagina, they secrete mucus to lubricate the vagina, their duct length is 1.5 to 2.0 cm and open into navicular fossa. Inflammation of these glands can be caused by but not limited to gonorrhoeal and chlamydial infections and is called bartilinitis.

Clitoris. In humans, the visible button-like portion is near the front junction of the labia minora, above the opening of the urethra, the clitoris is the human female's most sensitive erogenous zone and generally the primary anatomical source of human female sexual pleasure, is comparable to the penis in males.



18

Vagina. The vagina is an elastic, muscular tube that connects the cervix of the uterus to the exterior of the body. It is located inferior to the uterus and posterior to the urinary bladder. At the vulva, the vaginal orifice may be partly covered by a membrane called the hymen, while, at the deep end, the cervix bulges through the anterior wall of the vagina. The wall of the vagina from the lumen outwards consists firstly of a mucosa of non-keratinized stratified squamous epithelium with an underlying lamina propria of connective tissue, secondly a layer of smooth muscle with bundles of circular fibers internal to longitudinal fibers, and thirdly an outer layer of connective tissue called the adventitia. The mucosa forms folds or rugae, which are more prominent in the caudal third of the vagina; they appear as transverse ridges and their function is to provide the vagina with increased surface area for extension and stretching. Where the vaginal lumen surrounds the cervix of the uterus, it is divided into four continuous regions or vaginal fornices; these are the anterior, posterior, right lateral, and left lateral fornices. The posterior fornix is deeper than the anterior fornix. The functions are: serves as the birth canal, is the place where semen from the male penis is deposited into the female's body at the climax of sexual intercourse, a phenomenon commonly known as ejaculation, during menstruation, the menstrual flow exits the body via the vagina.

Uterus. Is a pear-shaped muscular organ 7.6 cm long, 4.5 cm broad (side to side) and 3.0 cm thick (anteroposterior). The uterus is divided into 4 parts: the fundus, corpus, cervix and the internal os. From outside to inside, the path to the uterus is as follows: cervix uteri, external

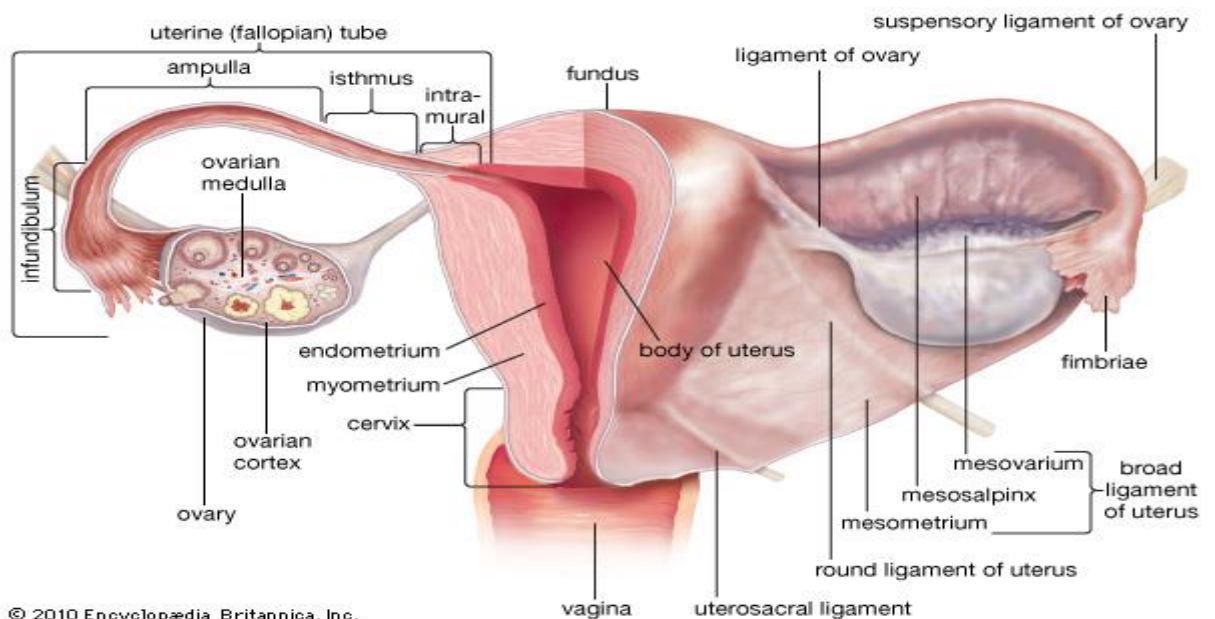
orifice of the uterus (external os), cervical canal, internal os, cavity of the uterus body, fundus of the uterus. The lower end of the cervix bulges into the anterior wall of the vagina, and is referred to as the vaginal portion of cervix (or ectocervix), the rest of the cervix above the vagina is called the supravaginal portion of cervix. The mucosa lining the cervical canal is known as the endocervix and the mucosa covering the ectocervix is known as the exocervix. Vaginal portion of the uterus as the mucosa layer of the vagina are covered with squamous epithelium. The mucosa layer of the cervical canal is covered by one layer of cylindrical ciliary epithelium, contain a lot of glands, that produce thick mucous. The external os in the nulipara woman has a round shape, in multipara – a shape of a transverse cleft. It divides the cervix into two lips – anterior and posterior.

The layers of the uterus are:

- endometrium - is covered by ciliary cylindrical epithelium with a big amount of glands, that are too covered with cylindrical epithelium. Endometrium consists of two layers: superficial or functional – that changes depending of the phase of the menstrual cycle, and profound or basal – that is closely adjacent to the basal membrane and does not change during menstrual cycle.
- Myometrium – it consists of three layers of muscles – external and internal longitudinal and middle – circular, that is most prominent.
- Perimetrium – serous layer – is the visceral fold of the peritoneum. The uterus body is covered with peritoneum, that in the front covers the bladder as a crease and covers the excavation vesicouterina. Behind the uterus, the peritoneum covers the rectum and forms the excavation rectouterina. Laterally of the uterus, the two layers of the peritoneum are called the wide ligament of the uterus and pass to the lateral pelvic wall.

19

The uterus has three suspensory ligaments: lig.latum uteri (formed as a double fold of the peritoneum) , lig.teres uteri(that goes from the horn of the uterus and passes into the inguinal canal), lig. ovarii proprium(connects the uterus end of the ovary with the uterus) and lig. Suspensorium ovarii(is the most movable part of the lig.latum uteri).



Uterus function - The uterus is essential in sexual response by directing blood flow to the pelvis and to the external genitalia, including the ovaries, vagina, labia, and clitoris, the reproductive function of the uterus is to accept a fertilized ovum which passes through the utero-tubal junction from the fallopian tube, the visceral muscles of the uterus contract during childbirth to push the fetus through the birth canal

Uterus appendages include fallopian tubes and ovaries.

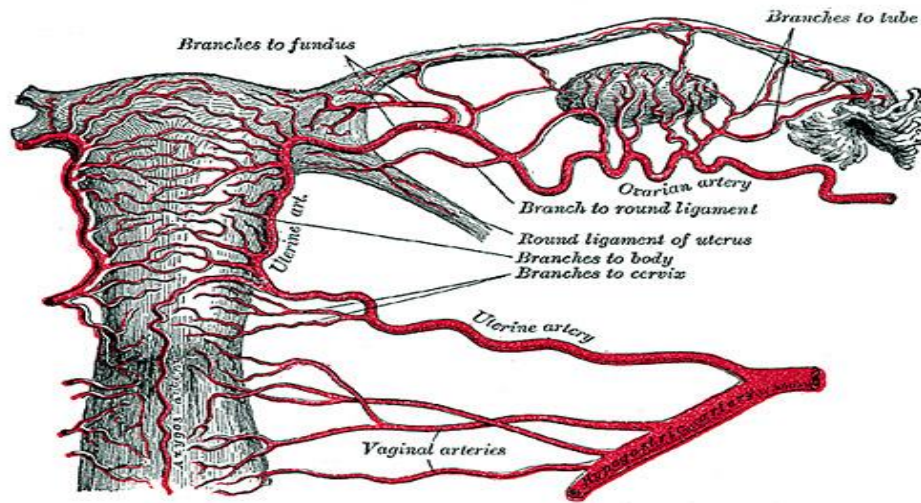
Fallopian tube. It passes in the broad ligament of the uterus. The length is 10-12 cm. It has two orifices – uterine and abdominal. The fallopian tube is divided into 4 parts: the infundibulum with its associated fimbriae near the ovaries, the ampullary region that represents the major portion of the lateral tube, the isthmus which is the narrower part of the tube that links to the uterus, and the interstitial (also known as intramural) part that transverse the uterine musculature. The fallopian tube is contracted by peristalsis movements from the ampullary part to the uterus. The wall of the tube consists of three layers: mucous membrane, that is the continuation of the mucous membrane of the uterus body, the muscular layer, formed by two layers of muscles (internal circular and external longitudinal) and serous (peritoneum).

Ovary. Is a pair gonad approximately 3 cm long and 2 cm wide and 1.5 cm thick. The end to which the fallopian tube attaches is called the *tubal extremity* and ovary is connected to it by infundibulopelvic ligament. The other extremity is called the *uterine extremity*. It points downward, and it is attached to the uterus via the ovarian ligament. The ovaries lie within the pelvic cavity, on either side of the uterus, to which they are attached via a fibrous cord called the ovarian ligament. The ovaries are uncovered in the peritoneal cavity but are tethered to the body wall via the suspensory ligament of the ovary. The part of the broad ligament of the uterus that covers the ovary is known as the mesovarium. The ovary is thus considered an intraperitoneal organ. The ovary consists of flat epithelial cells that originate from surface epithelium covering the ovary, granulosa cells - surrounding follicular cells have changed from flat to cuboidal and proliferated to produce a stratified epithelium, gametes, the outermost layer is called the germinal epithelium. The ovarian cortex consists of ovarian follicles and stroma in between them. Included in the follicles are the cumulus oophorus, membrana granulosa (and the granulosa cells inside it), corona radiata, zona pellucida, and primary oocyte. The zona pellucida, theca of follicle, antrum and liquor folliculi are also contained in the follicle. Also in the cortex is the corpus luteum derived from the follicles. The innermost layer is the ovarian medulla. It can be hard to distinguish between the cortex and medulla, but follicles are usually not found in the medulla. The ovary also contains blood vessels and lymphatics. Basic functions of the ovary are: production of hormones (estrogen, testosterone and progesterone) and ovarian aging

Blood supply of the female genitalia:

- The external genitalia are supplied with blood from a.pudenda interna (that is a branch of a.iliaca interna), a.pudenda externa, a.obturatoria (a branch of a.iliaca interna) and a.spermatica externa (a branch of a.iliaca externa). Identically names veins go in parallel with the arteries.
- The internal genitalia are supplied from the vessels that come directly from the aorta (ovarian artery) and from the a.iliaca interna (uterine artery). The uterus is supplied with blood from the a.uterina and partially from a.ovarica. A. Uterina supplies blood to uterus, broad ligament of the uterus, round ligaments of the uterus, fallopian tubes, ovaries and vagina. But mainly, the blood supply of the ovaries and fallopian tubes is carried out by a. ovarica. The upper part of the vagina is supplied with blood from the descending

branches of the uterine artery, the middle part by the vaginal branches of a.vesicalis inferior and the lower part by the branches of the a.pudenda interna and a.rectalis media.



The lymphatic system of the female genitalia is a wide range of lymphatic vessels and nodes. There are profound and superficial inguinal, internal and external iliac, sacrum and paraaortic lymphatic nodes and the lymphatic nodes of the obturator foramen. From the external genitalia and the lower part of the vagina the lymph passes into the inguinal lymphatic nodes, partially there comes the lymph from the nodes of the uterus fundus. From the upper part of the vagina, cervix and lower part of the uterus, the lymph passes through the vessels into the sacrum, obturator, internal and external iliac lymphatic nodes. From the upper part of the uterus, fallopian tubes and ovaries the lymph is collected into the lumbar lymphatic nodes.

21

The innervation of the internal genitalia is carried by the sympathetic and parasympathetic part of the autonomic nervous system. The bigger part of the nerves that go to the uterus are sympathetic, the branches of n.vagus, n.phrenicus, rami communicantes of the sacrum plexus are joined with them. The uterus body is innervated mainly by the sympathetic nervous system, the isthmus of the uterus is innervated by the pelvic plexus, the cervix mainly is innervated by the parasympathetic nerves, that pass from the uterus-vaginal plexus. The ovaries are innervated by the ovarian plexus. The branches of n.pudendus come up to the external genitalia. The fallopian tubes are innervated partially from the ovarian plexus, partially from the uterus-vaginal.

Examination of the gynecological patients. The examination of the gynecological patients include history taking, general and special methods of investigation.

When conducting the history taking the doctor should ask the passport data, complaints, working and living conditions, family history (heredity, presence of diseases such as diabetes, hypertension, ovarian cancer, breast cancer, alcoholism or drug addiction in close relatives), history of diseases (tuberculosis, syphilis, children's infectious diseases), history of gynecological diseases, allergic history, menstrual function (menarche, type of menstrual cycle, exact date of the last menses, duration of the MC, type of the blood loss, regularity of the MC), secretory function (type of vaginal discharge), sexual behavior (the age of the first sex, the number of marriages, the duration of marriage, type of contraception), reproductive function or obstetric history (information on previous pregnancies, their number and outcomes), surgical history.

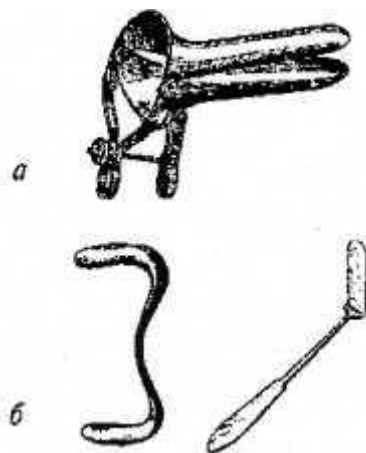
General examination includes: measuring the height, weight, vital signs (temperature, blood pressure, pulse rate, respiratory rate), general appearance, head and neck, examination of the breasts, examination of the heart and lungs (measuring BP, ECG, respiratory rate, auscultating the lungs), examination of the back and extremities (varicosities, edema, pedal pulsation, coetaneous lesion), inspection of the abdomen to notice the contour (flat, scaphoid, protuberant), distribution of hair, the presence of postoperative scars and striae , abdominal tenderness, rebound tenderness, muscle guarding, abdominal rigidity, a “doughy” abdomen in which the guarding increases gradually as the pressure of palpation is increased – hemoperitoneum, palpation of any abdominal mass.

Special methods of investigation.

While inspecting the vulva we should notice the character and distribution of hair, development or atrophy of the labia, the character of the hymen and introitus, cysts inflammation or tumors of Bartholin’s gland, visible vaginal discharge, to ask the patient to strain to elicit in order to diagnose stress incontinence or genital propapse (the descending of the vaginal walls).

Speculum examination. The speculum examination is done in all sexually active patients to visualise and inspect the vagina and vaginal portion of the cervix. There are different types of speculums used nowadays. Most often the disposed speculums are used, but still the metal ones are used to. They may be Grave’s, Cusco’s, Sims’, etc.

22

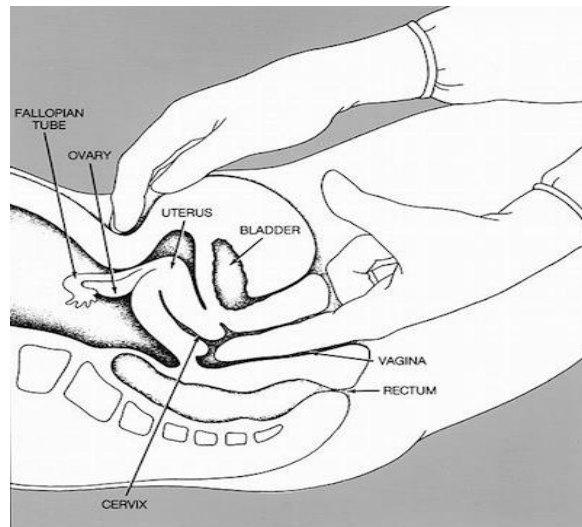


a- Cusco's

b- Sim's

The technique is: After gently spreading the labia to expose the introitus the speculum should be inserted with the blades entering the introitus transversely then directed posteriorly in the axes of vagina with pressure exerted against the relatively insensitive perineum to avoid contact with the sensitive urethra. As the anterior blade reaches the cervix the speculum is opened to bring the cervix into view. The cervix should be examined to determine its size, shape and colour. The nulliparous patients generally have a conical unscarred cervix with a circular, centrally placed os. The multiparous cervix is usually bulbous, and the os has a transverse configuration. Nabothial follicles (plugged, distended cervical glands) may be seen on the ectocervix. We inspect the squamocolumnar junction of the cervix. We take a cervical cytologic smear (PAP smear) from the squamocolumnar junction.

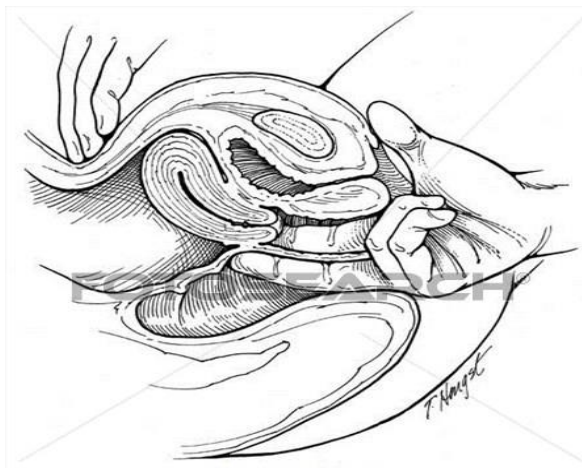
Bimanual examination is done to get information about the uterus and adnexa. Preparation – the woman should empty her bladder. Technique: the woman is placed into lithotomic position, the labia are separated and the index finger is inserted into the vagina, avoiding the sensitive urethral meatus. Pressure is exerted posteriorly against the perineum and puborectalis muscle which causes the introitus to gape somewhat thereby usually allowing the middle finger to be inserted as well. The cervix is palpated for consistency, contour, size and tenderness to motion. The uterus is evaluated by the size (is counted in size corresponding weeks of gestation), configuration, consistency and mobility. By shifting the abdominal hand to either side of the midline and gently elevating the lateral fornix up to the abdominal hand it may be possible to outline the adnexal masses. The pouch of Douglas is examined for nodularity or tenderness. It is usually impossible to feel a normal tube.



23

Rectal or rectoabdominal examination. Is done in children or adult virgins, in case of painful vaginal examination, carcinoma of the cervix to note the parametrial involvement, atresia of vagina, to diagnose rectocele and differentiate enterocele. The lower bowel should be preferably empty. The gloved vaseline smeared index finger should be inserted into the rectum. The other procedure is the same as in the bimanual examination.

Rectovaginal examination. The index finger is introduced into the vagina, the middle finger into the rectum. It helps to determine whether the lesion is in the bowel or between the rectum and vagina. This is of special help to differentiate a growth arising from the ovary or rectum.



cog03002 www.fotosearch.com

Ovarian function tests.

- Phenomenon of “pupil”. During the MC under the influence of estrogen the muscular tone of the cervix is changing together with the diameter of the external os. The dilation of the external os and the appearance of the mucous starts from the 8-9th day of the MC and up to the 14th day is dilated to the biggest diameter.(3-6 mm). The dot of mucous that comes out of the external os under the light of the background of the pink mucous layer looks like a “pupil” of the eye. During the next days the amount of the mucous decreases and up to the 18-20 day of MC this phenomenon disappears, the cervix becomes “dry”.



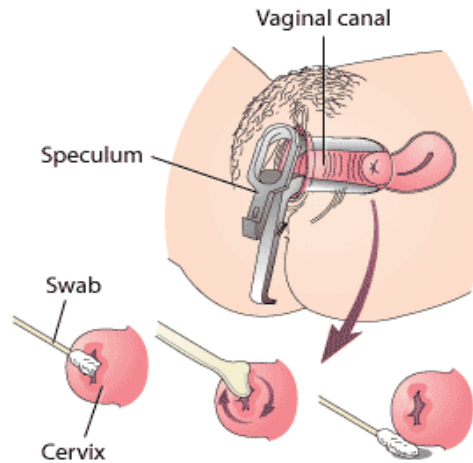
- The ferning symptom. The mucous of the cervix after drying it on the air has the ability to crystallize. The intensity of crystallization depends on the phase of the MC, that means on the level of oestrogen. The mucous is taken by the forceps, that is introduced into the cervical canal on the depth of 5 mm, then that mucous is put on the glass slide, is dried and investigated by the microscope. During the ovulation, in case of crystallization, the pattern looks like the leaves of the fern. The same character has the saliva.

- The changes of the basal temperature. Is based on the increase of the temperature under the influence of progesterone. This test is easy, affordable and relatively objective, but one needs to remember, that some of the causes of non- hormonal character may influence the results (diseases, that are accompanied by the elevated body temperature). The measurement should be done for at least 2-3 MC.

24

Nowadays, hormonal levels are widely used to investigate the function of the ovaries. They basically include the Follicle Stimulating Hormone (FSH) – FSH is a hormone that is measured by a blood test. When only a few follicles are developing, estrogen levels are lower and more FSH is produced. This leads to higher levels of FSH during the early menstrual cycle (day 2-4). FSH levels greater than 10-11 mIU/mL may be a sign of reduced ovarian reserve., anti – Mullerian Hormone (AMH) - AMH is a hormone that is measured by a blood test. AMH is produced by follicles in the ovaries and the level reflects the remaining egg supply in the ovaries. With increasing female age, the number of eggs in the ovary decreases. Likewise, the blood AMH levels decrease with age. AMH level less than 1.0 ng/ml may be a sign of reduced ovarian reserve. Antral Follicle Count (AFC) - AFC is a test that is performed by transvaginal ultrasound. The total number of small (antral) follicles in both ovaries are usually measured during the first few days of the menstrual cycle. The number of ovarian follicles visible on ultrasound decreases with age. Fewer than 10 antral follicles may be a sign of reduced ovarian reserve.

PAP smear. It is used as a screening procedure of cervical pathology. The patient is put into lithotomy position. The cervix is exposed with speculums. The cytological material from the cervix by Ayre’s spatula or cervix brush is collected from the squamo-columnar junction, and put on the glass slide. Then the material is fixed and sent to the cytological laboratory. The results according to the Papanicolaou classification are: I – normal, II- squamous atypia (basically because of inflammatory process), III- mild and moderate dysplasia, IV – severe dysplasia, CIS, V- cancer.



Colposcopy. Is a medical diagnostic procedure to examine an illuminated, magnified view of the cervix and the tissues of the vagina and vulva. It is done using a colposcope, which provides an enlarged (up to 15-40 times) view of the areas, allowing the colposcopist to visually distinguish normal from abnormal appearing tissue and take directed biopsies for further pathological examination. Colposcope is the low-power binocular microscope, mounted on a stand. The patient is placed in lithotomy position, the cervix is visualized using a Cusco's speculum. Cervix is cleared of any mucous discharge using a swab, next the cervix is wiped gently with 3 per cent acetic acid and examination repeated. Most women undergo a colposcopic examination to further investigate a cytological abnormality on their PAP smears.

25 Cervical biopsy. A cervical biopsy is a procedure performed to remove tissue from the cervix to test for abnormal or precancerous conditions, or cervical cancer. The biopsy can be made during speculum examination or under the visualization of the colposcope. Types of cervical biopsies include:

- **Punch biopsy.** A surgical procedure to remove a small piece of tissue from the cervix. One or more punch biopsies may be performed on different areas of the cervix.
- **Cone biopsy or conization.** A surgical procedure that uses a laser or scalpel to remove a large cone-shaped piece of tissue from the cervix.
- **Endocervical curettage (ECC).** A surgical procedure in which a narrow instrument called a curette is used to scrape the lining of the endocervical canal, an area that cannot be seen from the outside of the cervix.

Ultrasound. Ultrasound is a non-invasive, very widely used and informative imaging procedure. In gynecology, transabdominal sonography, transvaginal sonography, and transvaginal color Doppler sonography are used. Transabdominal ultrasound is used in cases of large uterine fibroids, in the 2nd and 3rd trimesters of pregnancy, large ovarian cysts and cystomas, narrow vagina, virgins, etc. Transvaginal sonography is more precise, as it is placed close to the target organ. Transvaginal color Doppler sonography provides additional information of blood flow, from or within an organ.

Hysteroscopy is the inspection of the uterine cavity by endoscopy with access through the cervix. The instrument is passed transcervically. Diagnostic hysteroscopy should be performed in the postmenstrual period for a better view without bleeding. It allows for the diagnosis of intrauterine pathology and serves as a method for surgical intervention (operative hysteroscopy).

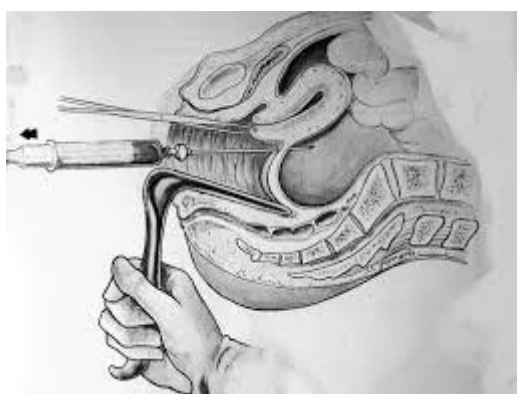
Tests for tubal patency. There are different methods to investigate the fallopian tubes for patency. They include:

- Dilation and insufflations (a dilation of the cervix and introduction of air or CO₂ into the uterine cavity. Positive test is evidenced by a hissing sound that is audible on the flank due to exit of air through the abdominal ostium).
- Hydrotubation (is the introduction of saline or other medications into the uterine cavity. Positive test – the fluid passes into the uterine cavity and onwards, the amount of injected fluid is approximately 20 ml, the patient feels a slight discomfort of the flanks, that is due to the introduction of the fluid into the abdominal cavity through the abdominal ostium of the fallopian tube).
- Hysterosalpingography (in the introduction of a contrast into the uterine cavity with following X-ray of the pelvis. In case of passable tubes, the contrast fills the uterine cavity, fallopian tubes and is seen free in the abdominal cavity).
- Laparoscopy and chromopertubation (it is a gold standard for evaluation of tubal factors of infertility.)
- Sonohysterosalpingography (a contrast is introduced into the uterine cavity with a constant investigation by the ultrasound. A positive test the contrast passes into the abdominal cavity).

All of these test are done in the proliferative phase in case of no inflammatory disease of the genitalia are present.

26 Laparoscopy. Is a technique of visualization of peritoneal cavity by means of optic endoscope introduced through the abdominal wall. The laparoscopy may be done for diagnosis (in case of infertility, chronic pelvic pain, to diagnose the nature of pelvic mass, acute pelvic lesion, ectopic pregnancy, investigation protocol of amenorrhea, uterine perforation, etc) and for operative aims (tubal sterilization, adhesiolysis, aspiration of simple ovarian cysts, ovarian biopsy, in case of ectopic pregnancy, for segmental resection, salpingoectomy, diathermy for PCOS, ovarian cystectomy, myomectomy, etc.)

Culdocentesis – is the transvaginal aspiration of the peritoneal fluid from the cul-de-sac or pouch of Douglas. Indications – suspected disturbed ectopic pregnancy, or other causes causing hemoperitoneum, is suspected cases of pelvic abscess. Technique: the procedure is done under sedation, the patient is put into lithotomy position, vagina is cleaned, the speculums are inserted, the posterior lip of the cervix is fixed with the forceps and turned upwards, a needle is fitted with a syringe and is inserted at a point 1 cm below the cervico-vaginal junction in the posterior fornix. After inserting the needle to a depth of about 2 cm, suction is applied as the needle is withdrawn.



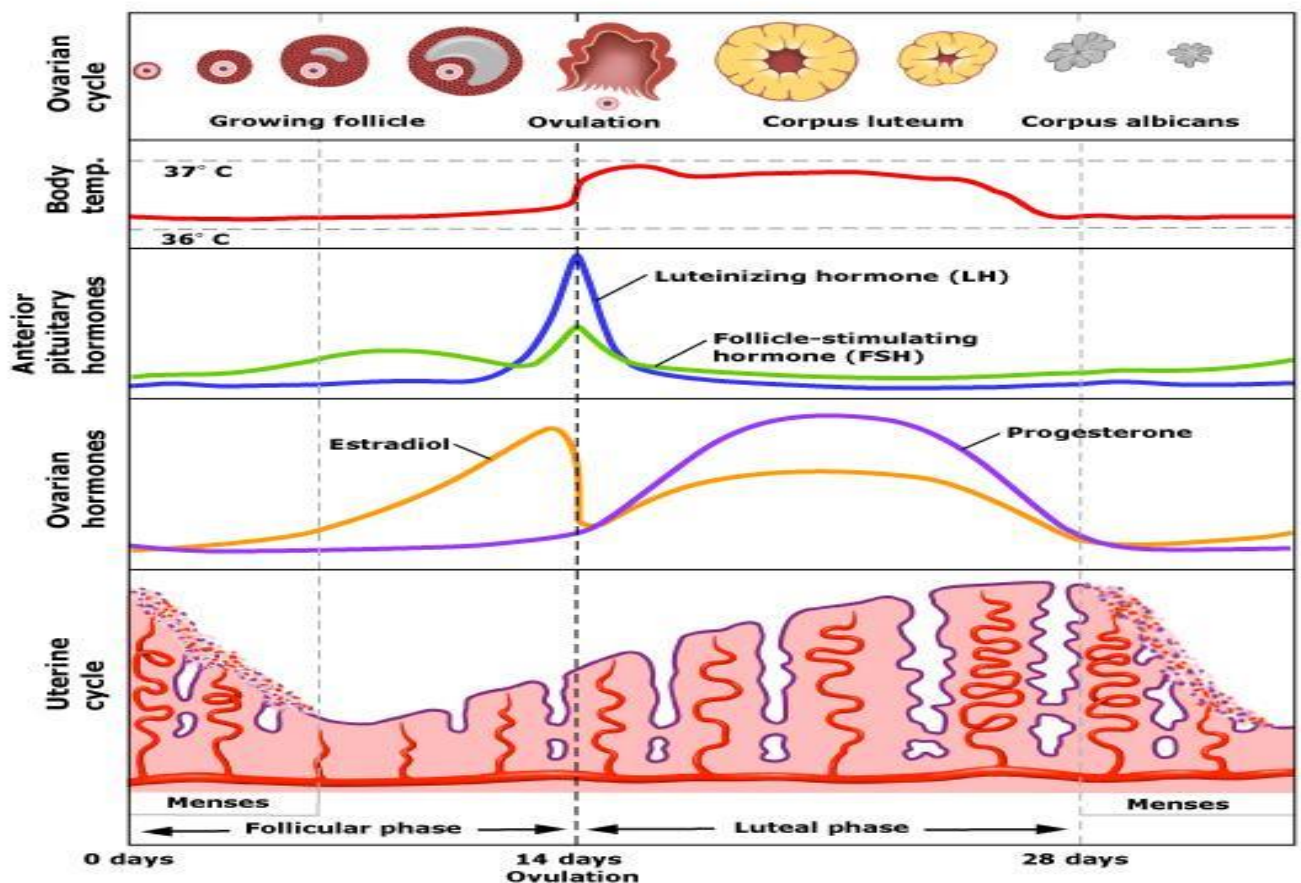
Modern knowledge about the menstrual cycle.

Menstrual cycle (MC)- is the cycle of natural changes that occurs in the uterus and ovary as an essential part of making sexual reproduction possible. It is a visible manifestation of cyclic physiologic uterine bleeding due to shedding of the endometrium. For the menstruation to occur, the axis must be actively coordinated, endometrium must be responsive to the ovarian hormones and the outflow tract must be patent. The period extending from the beginning of a period to the beginning of the next is called menstrual cycle. The MC begins when a girl reaches the age of puberty. The average age of menarche(first menses) is 12-15 (8-16) years. It continues cyclically at intervals of 21-35 days with a mean of 28 days. Physiologically it is kept in abeyance due to pregnancy and lactation. The duration of menses is about 4-5 days (up to 7 days) and the amount of blood loss is 20-80 ml. The average age of menopause is 52 (45-55) years.

There are cycles and phases that occur in the ovaries, uterus, and other reproductive organs as vagina, cervix, mammary glands,

- Ovarian cycle (follicular phase, ovulation, luteal phase)
- Uterine cycle (menstruation, regeneration, proliferative phase, secretory phase)
- Cyclic changes in other reproductive organs(cervix, vagina, etc.)
- Begins with the first day of menstrual bleeding

27



Ovarian cycle. Follicular phase. Lasts 13-14 day The main event – the development of follicles in the ovary. There is slight increase of production of the follicle-stimulating hormone and the growth of 3-30 follicles, each containing an egg. Only 1 of these follicles (dominant follicle) continues to grow. The follicle that reaches maturity is called tertiary or Graafian follicle. The

phase ends when the increase of the level of luteinising hormone The surge results in release of the egg.

Ovulation. The dominant follicle shortly before ovulation reaches the surface of the ovary LH surge 10-12 before the breakdown of the follicle and lasts for approximately 48 hours The mature egg is released from the ovarian follicles to the oviduct. Following ovulation, the follicle is changed to corpus luteum. The ovum is picked up into the Fallopian tube and undergoes either degeneration or further maturation, if fertilization occurs. The duration is approximately 16-32 hours.

Luteal phase. Begins after ovulation, lasts about 14 days. FSH and LH cause ruptured follicle closes and forms a corpus luteum, which produces increasing quantities of progesterone. The progesterone prepares the uterus in case an embryo is implanted. Increased level of progesterone induces the production of estrogen. These hormones suppress the production of the FSH and LH, the levels of which fall quickly over time, and the corpus luteum atrophies. Falling levels of progesterone trigger menstruation to begin.

Uterine phase. Menstruation = menstrual bleeding, menses, catamenia or a period. It is essentially degeneration and casting off an endometrium prepared for a pregnancy. Regression of corpus luteum with fall in the level of oestrogen and progesterone is an invariable preceding feature. As a result of withdrawal of hormonal support, there is retrogressive changes in the endometrium. Eumenorrhea – normal regular menstruation that lasts approximately 3-5 (2-7) days. Average blood loss is 10-80 ml.

28

Regeneration. Regeneration of the endometrium starts even before the menstruation ceases and it completed 2-3 days after the end of menstruation. The thickness averages 2mm.

Proliferation. This stage is observed from 5th or 6th day of MC to 14th day. Due to oestrogen there is proliferation of all the elements – the glands become tubular, the epithelium becomes columnar, the spiral vessels extend.

Secretory phase. The changes are due to the combined effects of oestrogen and progesterone, liberated from the corpus luteum after ovulation. The progesterone can only act on the endometrium previously primed by oestrogen. It begins from the 15th day and ceases 5-6 days prior to menstruation. The glands increase in size. The lining epithelium become taller, there is appearance of vacuoles due to secretion of glycogen between the nuclei and basal membrane. The blood vessels undergo marked spiraling, the thickness of the endometrium reaches its highest. The regressive changes in the endometrium are pronounced 24-48 hours prior to menstruation.

Changes in other reproductive organs: cervix- during follicular phase there is marked an increase of the cervical vascularity and oedema and cervical mucus quantity, elasticity and salt concentration. The external os opens slightly, the external os fills with mucus at ovulation. During the luteal phase the cervical mucus thickens and becomes less elastic decreasing success of sperm transport. Vagina during the early follicular phase – the vaginal epithelium is thin and pale, later the squamous cells mature and become cornified, causing epithelial thickening During the luteal phase the number of precornified intermediate cells increases, the number of leukocytes and amount of cellular debris increase as mature squamous cells are shed.

Disorders of the menstrual cycle. Neuroendocrine syndromes in gynecological practice.

Amount of hours: 2 hours of lecture, 4 hours in practical classes

The topic includes the learning of Classification of the menstrual function disturbances. Amenorrhea. Ovulatory and non-ovulatory dysfunctional uterine bleedings. Algodysmenorrhea. Neuroendocrine syndromes in gynecology. Modern method of treatment, the role of endoscopic methods in diagnosis and treatment.

Questions for the modular control

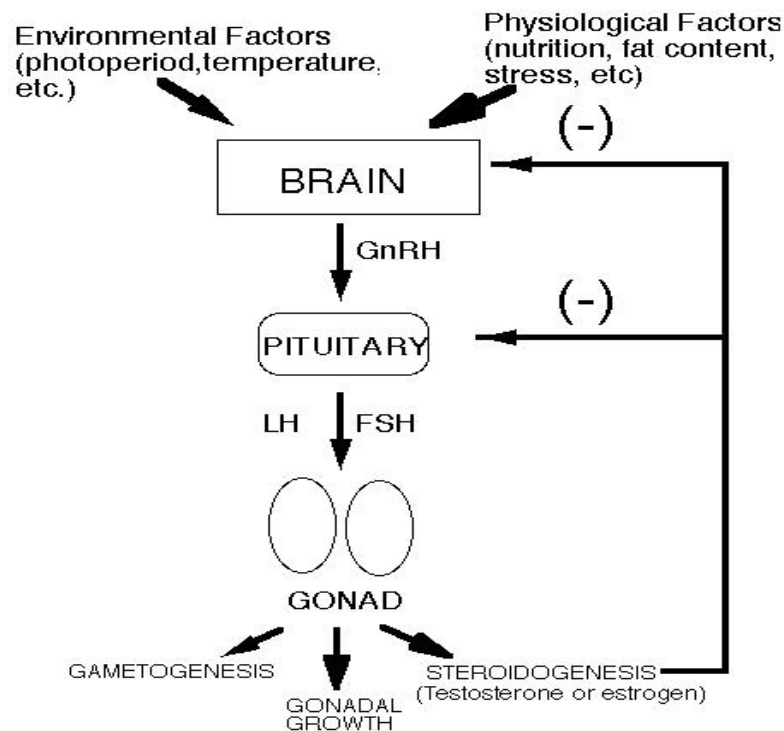
1. Classification of the menstrual function disorders.
2. Amenorrhea.
3. Dysfunctional uterine bleeding. Classification. Methods of diagnostic and treatment.
4. Juvenile uterine bleeding. Etiology, symptomatic diagnosis and treatment.
5. Postmenopausal uterine bleeding. Etiology< symptomatic, diagnosis and treatment.
6. Algodismenorrhea. Symptomatic, diagnosis and treatment.
7. Neuroendocrine syndromes in gynecology.

29 Eumenorrhea – is a menstruation with the duration of menses is about 4-5 days (up to 7 days) and the amount of blood loss is 20-80 ml, the duration of the MC is 21-35 days with a mean of 28 days.

Classification of the menstrual disorders:

1. Disorders of ovulation:
 - Oligoovulation – is infrequent or irregular ovulation (usually defined as cycles of ≥ 36 days, or < 8 cycles a year)
 - Anovulation – is absence of ovulation, when it would be normally expected (in a post-menarcheal, premenopausal woman) Anovulation usually manifests itself as irregularity of menstrual periods, that is unpredictable variability of intervals, duration, or bleeding. Anovulation can also cause cessation of periods (secondary amenorrhea) or excessive bleeding
2. Disorders of menstrual flow:
 - Hypomenorrhea is abnormally light menstrual periods.
 - Menorrhagia (meno = month, rrhagia = excessive flow/discharge) is an abnormally heavy and prolonged menstrual period. If there is excessive menstrual and uterine bleeding other than that caused by menstruation, menometrorrhagia (meno = prolonged, metro = uterine, rrhagia = excessive flow/discharge) may be diagnosed. Causes may be due to abnormal blood clotting, disruption of normal hormonal regulation of periods or disorders of the endometrial lining of the uterus.
 - Depending upon the cause, it may be associated with abnormally painful periods (dysmenorrhoea).
3. Disorders of cycle length:

- Polymenorrhea is the medical term for cycles with intervals of 21 days or fewer.
- Irregular menstruation is where there is variation in menstrual cycle length of more than approximately eight days for a woman. The term metrorrhagia is often used for irregular menstruation that occurs between the expected menstrual periods.
- Oligomenorrhea is the medical term for infrequent, often light menstrual periods (intervals exceeding 35 days).
- Amenorrhea is the absence of a menstrual period in a woman of reproductive age. Physiologic states of amenorrhoea are seen during pregnancy and lactation (breastfeeding).



30

Dysfunctional uterine bleeding (DUB) is defined as excessive, prolonged, unpatterned endometrial bleeding in the absence of organic disease. After pathologic abnormalities, systemic disorders, or iatrogenic causes have been ruled out, functional (endocrinologic) causes are then considered, and resultant uterine bleeding is described by the term dysfunctional uterine bleeding.

Classification:

- Anovulatory ("not ovulating"), caused by a low level of the hormone progesterone. Progesterone is necessary for the ovary to regularly release an egg (ovulation), as well as for regulating menstrual bleeding. Low progesterone causes irregular and heavy menstrual bleeding. This type of dysfunctional uterine bleeding is common before age 20 and after age 40 (perimenopause). During these times of transition into and out of the fertile years, it's normal for progesterone levels to be variable.
- Ovulatory. As many as 10% of ovulating women have dysfunctional uterine bleeding despite having normal levels of progesterone and other hormones. In these cases, no hormonal or other cause can be found. Experts do not fully understand this type of dysfunctional uterine bleeding and its causes.
- DUB or reproductive age
- Juvenile DUB

- Perimenopause DUB

Symptoms:

- Menstrual bleeding that occurs more often than every 21 days or farther apart than 35 days (a normal menstrual cycle is 24 to 35 days long)
- Menstrual bleeding that lasts longer than 7 days (normally 4 to 6 days)
- Blood loss of more than 80 mL each menstrual cycle (normally about 30 mL). Large clots or soaking a large pad per hour for 8 hours, the bleeding is considered heavy.

Diagnosis - DUB is a "diagnosis of exclusion." This means that your health professional has ruled out other medical causes of vaginal bleeding such as miscarriage, pregnancy complications, or disease, and common and less serious causes such as adenomyosis and uterine fibroids.

Additional testing – transvaginal sonography.

Treatment of DUB or reproductive and premenopausal age:

1. stage – hemostasis - surgical hemostasis – dilation and curettage of the cervical canal and uterine cavity – the most effective therapeutical and diagnostic method. Diagnostic curettage is the main method of hemostasis in women of reproductive and climacteric period, taking into account an increase in the frequency of endometrial cancer. In case the D&C was performed less than 3 months ago, than hormonal hemostasis is possible. For hormonal hemostasis combined oral contraceptives are used. Surgical methods of treatment – ablation of endometrium (by laser, either resectoscope or loop, or ball electrode under the control of hysteroscopy), hysterectomy) radical method of treatment is case of ineffective other method and finished reproductive function.

Conservative treatment includes- progesterone – that prevents overgrowth of the endometrium, Non-steroidal anti-inflammatory drugs (NSAIDs) such as ibuprofen, can curd heavy uterine bleeding, use of levonorgestrel IUD, which releases a progesterone-like synthetic hormone into the uterus. This reduces bleeding while preventing pregnancy, hormone treatment.

2. stage – Prevention of reoccurrence – hormonal therapy, vitamin therapy, NSAIDs, etc.

Dilation and curettage . Technique: the woman should empty her bladder. The procedure is made with general anesthesia. The external genitalia are wiped. The cervix is visualized by speculum, the anterior lip is taken with forceps, the cervical canal is dilated with Hegar's dilators, the cervical canal and uterine cavity is cutteted by a sharp currete. The material is sent for histological investigation. The antibiotics are prescribed for prophylaxes of possible inflammatory complications.

Juvenile dysfunctional uterine bleeding: - is the dysfunctional uterine bleeding in the period sexual maturation (from menarche up to 18 years).

The severity of the disease is based on the:

- character of the blood loss (intensity, duration, etc.);
- the stage of post hemorrhagic anemia (mild, moderate, severe).

According to the WHO recommendations, the low grade of the normal hemoglobin in woman is 120 g/l, in teens – 130 g/l.

Three stages of amenia are distinguished:

- mild – Hb 119-90 g/l;
- moderate- Hb 89-70 g/l;
- severe- Hb 69 g/l or less.

Factors, that may cause the occurrence of juvenile DUB:

- unfavourable course of the neonatal period;
- acute and chronic infectious diseases;
- chronic extragenital diseases;
- acute and chronic forms of stress;
- pathological states of the endocrine glands (thyroid gland, hypothalamic syndrome, etc.)

Gynecological examination (is done in the presence of mother of the patient, or close relatives):

- the examination of the external genitalia (the stage of development, the presence of congenital malformations, character of bleeding);
- rectoabdominal examination – for evaluation of the state of internal genitalia;
- the inspection by gynecological speculums in sexually active patients.

Ultrasound investigation of the pelvic organs allows to evaluate the size and structure of the uterus, the size and state of the follicular apparatus of the ovaries, the presence of endometrial hyperplasia.

Laboratory examination:

- Blood count – complete blood count, including the count of hemoglobin, hematocrit, thrombocytes, etc.;
- Biochemical analysis of blood with the evaluation of the serum iron;
- Coagulogram
- If possible – the investigation of the levels of gonadotropic hormones.

Consultations of other specialists – endocrinologist, hematologist, pediatrician , neurologist.

The treatment of the juvenile uterine bleedings consists of two stages:

I stage – hemostasis (is done in the department of pediatrics gynecology or gynecological department)

II stage – prophylaxes of the reoccurrence (is done in the outpatient care)

The algorithm of treatment of juvenile uterine bleedings in case of compensated and decompensated state – conservative treatment. Symptomatic therapy is carried out. If there is no effect, hormonal therapy is done.

In case of life-threatening condition of the girl or in case of absence of hormonal hemostasis, surgical treatment is done (curettage of the uterine cavity).

The medications used for symptomatic therapy includes the prescription of Oxytocin , Etamsilate, Vicasoli, Iron containing medications, hormonal medications.

The indications for hormonal hemostasis:

- The long and heavy hemorrhage with the presence of secondary anemia;
- The absence of effect from symptomatic therapy in case of moderate and long-lasting hemorrhage;
- Long lasting hemorrhages and the presence of endometrial hyperplasia (m-echo more than 10 mm).

The D&C for diagnosis and treatment is done in case of:

- Profuse uterine bleeding, that is life treating for the patient;
- The pronounced secondary anemia (Hb 70 g/l or less, hematocrit less than 25,0%);

- A suspicion of pathological changes of the endometrial structure (endometrial polyp diagnosed by ultrasound of the pelvic organs).

The compulsory stage of treatment of juvenile DUB is the formation of the normal MC:

- To exclude the etiological causes of the juvenile DUB;
- Normalization of the MC of the girl by the medications;
- Nutrition;
- In case of secondary anemia – the prescription of iron containing medications.

Dysmenorrhea is the medical term for the painful cramps that may occur immediately before or during the menstrual period. There are two types of dysmenorrhea: primary dysmenorrhea and secondary dysmenorrhea.

Primary dysmenorrhea is another name for common menstrual cramps. Cramps usually begin one to two years after a woman starts getting her period. Pain usually is felt in the lower abdomen or back. Pain is thought to result from uterine contractions and ischemia, probably mediated by prostaglandins (eg, prostaglandin F_{2α}, a potent myometrial stimulant and vasoconstrictor) and other inflammatory mediators produced in secretory endometrium and possibly associated with prolonged uterine contractions and decreased blood flow to the myometrium. Contributing factors may include passage of menstrual tissue through the cervix, a narrow cervical os, a malpositioned uterus, lack of exercise, and anxiety about menses. They can be mild to severe. Common menstrual cramps often start shortly before or at the onset of the period and continue one to three days. They usually become less painful as a woman ages and may stop entirely after the woman has her first baby.

33

Secondary dysmenorrhea is pain caused by a disorder in the woman's reproductive organs. These cramps usually begin earlier in the menstrual cycle and last longer than common menstrual cramps. Common causes include - endometriosis (the most common cause), uterine adenomyosis, fibroids. Less common causes include congenital malformations (eg, bicornuate uterus, subseptate uterus, transverse vaginal septum), ovarian cysts and tumors, pelvic inflammatory disease, pelvic congestion, intrauterine adhesions, psychogenic pain, and intrauterine devices (IUDs), particularly copper- or levonorgestrel-releasing IUDs. Levonorgestrel-releasing IUDs cause less cramping than copper-releasing IUDs.

Symptoms- aching pain in the abdomen (Pain can be severe at times.), feeling of pressure in the abdomen, pain in the hips, lower back, and inner thighs. When cramps are severe, symptoms may include: upset stomach, sometimes with vomiting, loose stools.

Treatment. Underlying disorders are treated. Symptomatic treatment begins with adequate rest and sleep and regular exercise. A low-fat diet and nutritional supplements such as ω-3 fatty acids, flaxseed, magnesium, vitamin E, zinc, and vitamin B1 are suggested as potentially effective. Women with primary dysmenorrhea are reassured about the absence of structural gynecologic disorders. If pain persists, NSAIDs (which relieve pain and inhibit prostaglandins) are typically tried. NSAIDs are usually started 24 to 48 h before and continued until 1 or 2 days after menses begin. If the NSAID is ineffective, suppression of ovulation with a low-dose estrogen/progestin oral contraceptive may be tried. Other hormone therapy, such as danazol, progestin (eg, levonorgestrel, etonogestrel, depot medroxyprogesterone acetate), gonadotropin-releasing hormone agonists, or a levonorgestrel-releasing IUD, may decrease dysmenorrheal symptoms. Periodic adjunctive use of analgesics may be needed. Hypnosis is being evaluated as treatment. Other proposed nondrug therapies, including acupuncture, acupressure, chiropractic therapy, and transcutaneous electrical nerve stimulation, have not been well-studied but may benefit some patients. For intractable pain of unknown origin, laparoscopic

presacral neurectomy or uterosacral nerve ablation has been efficacious in some patients for as long as 12 mo.

Amenorrhea – the absence of menses during 6 months or more.

Classification:

- Primary amenorrhea
- Secondary amenorrhea
- True amenorrhea
- False amenorrhea

Primary amenorrhea – is the absence of menses by the age 16 in a woman who has normal growth and secondary sexual characteristics or absence of menses by the age 14 in woman who does not have normal growth and secondary sexual characteristics. The extragonal causes of primary amenorrhea are: adrenogenital syndrome – karyotype 46XX, hypothyroidism, defect in the hypothalamic-hypophysal region.

Secondary amenorrhea – is the absence of menses for 6 months in women who have been previously menstruating.

False amenorrhea – is the absence of menses in case there are cyclic changes in the hypothalamus-hypophysal system, but because of the pathological changes mainly in the external genitalia the blood does not come out.

True amenorrhea – the absence of cyclic changes in the hypothalamus-hypophysal system. The true amenorrhea may be physiological in case of pregnancy, lactation postmenopause and before the onset of puberty and pathological in case of gonadal agenesy (the gonad may be absent or may contain Y chromosome), the syndrome of testicular feminization (false male hermaphroditism- karyotype 46XY), primary ovarian failure(loss of ovarian activity before age 35).

Secondary amenorrhea according to the pathological changes in each part of the hypothalamic-hypophysal system may be divided into:

1. Hypothalamic:
 - Psychogenic amenorrhea
 - Anorexia nervosa
 - False pregnancy
 - Galactorrhea-amenorrhea
2. Hypophyseal:
 - Shikhan's (Simmond's) syndrome
 - Cushing disease
3. Ovarian:
 - Polycysticovarian syndrome (PCOS)
 - Androgen producing tumors of the ovaries
4. Uterine:
 - Tuberculous endometritis
 - Asherman syndrome

Examination.

History of present illness includes whether menses have ever occurred (to distinguish primary from secondary amenorrhea) and, if so, how old patients were at menarche, whether periods have ever been regular, and when the last normal menstrual period occurred. History should also include duration and flow of menses; presence or absence of cyclic breast tenderness and mood changes; and growth, development, and age at thelarche (development of breasts at puberty).

Review of systems should cover symptoms suggesting possible causes, including galactorrhea, headaches, and visual field defects (pituitary disorders); fatigue, weight gain, and cold intolerance (hypothyroidism); palpitations, nervousness, tremor, and heat intolerance (hyperthyroidism); acne, hirsutism, and deepening of the voice (androgen excess); and, for patients with secondary amenorrhea, hot flushes, vaginal dryness, sleep disturbance, fragility fractures, and decreased libido (estrogen deficiency). Patients with primary amenorrhea are asked about symptoms of puberty (eg, breast development, growth spurt, presence of axillary and pubic hair) to help determine whether ovulation has occurred.

Past medical history should note risk factors for functional hypothalamic anovulation, such as stress; chronic illness; new drugs; a recent change in weight, diet, or exercise intensity; and, in patients with secondary amenorrhea, risk factors for Asherman syndrome (eg, D & C, endometrial ablation, endometritis, obstetric injury, uterine surgery).

Drug history should include specific questions about use of drugs that affect dopamine (eg, antihypertensives, antipsychotics, opioids, tricyclic antidepressants), cancer chemotherapy drugs (eg, busulfan, chlorambucil, cyclophosphamide), and sex hormones that can cause virilization (eg, androgens, estrogens, high-dose progestins) and questions about recent use of contraceptives.

Family history should include height of family members and any cases of delayed puberty or genetic disorders in family members.

Physical examination:

Clinicians should note vital signs and body composition and build, including height and weight, and should calculate body mass index (BMI). Secondary sexual characteristics are evaluated; breast and pubic hair development are staged using Tanner's method. If axillary and pubic hair is present, adrenarche has occurred. With the patient seated, clinicians should check for breast secretion by applying pressure to all sections of the breast, beginning at the base and moving toward the nipple. Galactorrhea (breast milk secretion not temporally associated with childbirth) may be observed; it can be distinguished from other types of nipple discharge by finding fat globules in the fluid using a low-power microscope. Pelvic examination is done to detect anatomic genital abnormalities; a bulging hymen may be caused by hematocolpos, which suggests genital outflow obstruction. Pelvic examination findings also help determine whether estrogen has been deficient. In postpubertal females, thin, pale vaginal mucosa without rugae and pH > 6.0 indicate estrogen deficiency. The presence of cervical mucus with spinnbarkeit (a stringy, stretchy quality) usually indicates adequate estrogen.

General examination focuses on evidence of virilization, including hirsutism, temporal balding, acne, voice deepening, increased muscle mass, clitoromegaly (clitoral enlargement), and defeminization (a decrease in previously normal secondary sexual characteristics, such as decreased breast size and vaginal atrophy). Hypertrichosis (excessive growth of hair on the extremities, head, and back), which is common in some families, is differentiated from true hirsutism, which is characterized by excess hair on the upper lip and chin and between the breasts. Skin discoloration (eg, yellow due to jaundice or carotenemia, black patches due to acanthosis nigricans) should be noted.

Treatment is directed at the underlying disorder; with such treatment, menses sometimes resume. For example, most abnormalities obstructing the genital outflow tract are surgically repaired.

If a Y chromosome is present, bilateral oophorectomy is recommended because risk of ovarian germ cell cancer is increased.

Problems associated with amenorrhea may also require treatment, including

- Inducing ovulation if pregnancy is desired

- Treating symptoms and long-term effects of estrogen deficiency (eg, osteoporosis)
- Treating symptoms and managing long-term effects of estrogen excess (eg, prolonged bleeding, persistent or marked breast tenderness, risk of endometrial hyperplasia and cancer)
- Minimizing hirsutism and long-term effects of androgen excess (eg, cardiovascular disorders, hypertension)

Neuroendocrine syndromes in gynecological practice.

The main syndromes in gynecological practice are:

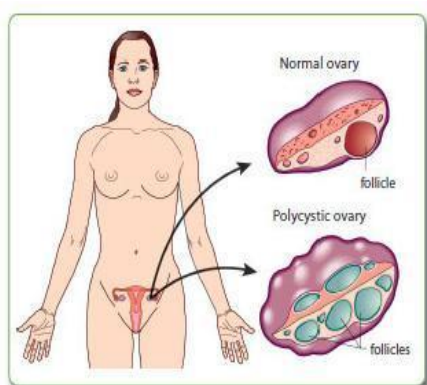
- Polycystic ovarian syndrome
- Climacteric syndrome
- Premenstrual syndrome
- Sheehan's syndrome
- Climacteric syndrome

Polycystic ovarian syndrome (PCOS) affects 4% to 12% of women of reproductive age. Despite being heterogeneous in nature, the hallmarks of the disease are hyperandrogenism and chronic anovulation. Since its description in 1935 by Stein and Leventhal, much has been learned about the pathophysiology of PCOS from its neuroendocrine underpinnings to an ever-growing understanding of the link between obesity, insulin resistance (IR) and PCOS.

Common symptoms of PCOS include the following:

- Menstrual disorders: PCOS mostly produces oligomenorrhea (few menstrual periods) or amenorrhea (no menstrual periods), but other types of menstrual disorders may also occur.
- Infertility: This generally results directly from chronic anovulation
- High levels of masculinizing hormones: The most common signs are acne and hirsutism (male pattern of hair growth), but it may produce hypermenorrhea (heavy and prolonged menstrual periods), androgenic alopecia (increase hair thinning or diffuse hair loss), or other symptoms.
- Metabolic syndrome: This appears as a tendency towards central obesity and other symptoms associated with insulin resistance

36



1990 NIH diagnostic criteria include both 1 and 2 – chronic anovulation, clinical and/or biochemical hyperandrogenism. 2003 Rotterdam diagnostic criteria (two out of three): oligo- or anovulation, clinical and/or biochemical hyperandrogenism, polycystic ovaries.

The treatment includes lowering of insulin resistance levels (in case of excessive body weight – weight loss) , restoration of fertility, treatment of hirsutism or acne , restoration of regular menstruation, and prevention of endometrial hyperplasia and endometrial cancer.

Premenstrual syndrome (PMS, premenstrual tension (PMT)) - a collection of emotional symptoms, with or without physical symptoms, related to a woman's menstrual cycle. In particular, emotional symptoms must be present consistently to diagnose PMS. Three most prominent symptoms: irritability, tension, dysphoria (unhappiness), Emotional and non-specific symptoms: stress, anxiety, insomnia, headache, fatigue, mood swings, increased emotional sensitivity, changes in libido. Physical symptoms: bloating, abdominal cramps, constipation, swelling or tenderness of the breasts, cyclic acne, joint or muscle pain.

The management depends of the severity of the symptoms, age of the patient and desire to fulfill the reproductive function. Conservative treatment includes the prescription of dietary supplements , vitamin E, B6, magnesium, manganese, tryptophan. Supportive therapy includes evaluation, reassurance, and informational counseling, and is an important part of therapy in an attempt to help the woman regain control over her life. Non steroidal anti-inflammatory drugs, clonidine and diuretics are widely used. Hormonal treatment includes the prescription of hormonal contraception, progesterone, gonadotropin-releasing hormone agonists.

Menopausal syndrome. Menopausal syndrome refers to the symptoms experienced by women during menopause, the transition period in a woman's life when her ovaries stop producing eggs, her body produces less estrogen and progesterone, and menstruation becomes less frequent, eventually stopping altogether. Symptoms of menopause include: hot flashes, night sweats, skin flushing, hair loss, poor sleep (insomnia), decreased interest in sex, possibly decreased response to sexual stimulation, forgetfulness (in some women), headaches, mood swings, including irritability, depression and anxiety, frequent urination or urine leakage, vaginal dryness and painful sexual intercourse , vaginal infections, joint aches and pains, irregular heartbeat. The treatment includes hormone replacement therapy for the woman without contraindications for its prescription, dehydroepiandrosterone, antidepressants, alternative medicine.

Postcastration (artificial menopause) syndrome. occurs after removal of the uterus or ovaries or in the result of destruction of follicular unit ovarian X or radium rays results in the woman's body to the phenomena typical for pathologically flowing natural menopause Expressed phenomenon of menopause is developed: hot flashes, hot sweat, and other phenomena that these patients are experiencing, especially distressing, because the body does not have time to adapt to sudden the changes. The type of treatment depends on the age of the patient, the pathology why the castration was done, the desire of the patient, the presence or absence of other extragenital diseases (liver problems, pathology of veins, etc.).

Sheehan syndrome (Simmond syndrome, postpartum hypopituitarism or postpartum pituitary gland necrosis). It is a rare complication of pregnancy, usually occurring after excessive blood loss. Due to the blood loss and hypovolemic shock during and after birth the ischemic necrosis of the pituitary gland may occur, resulting hypopituitarism – decreased function of all the pituitary hormones. The symptoms include: agalactorrhea, amenorrhea or oligomenorrhea, hypopituitarism (tiredness , intolerance to cold , constipation, weight gain , hair loss, slowed thinking, a slowed heart rate, low blood pressure), secondary adrenal insufficiency(fatigue, weight loss, hypoglycemia, anemia).

The treatment includes the hormonal replacement therapy with all the hormones of the pituitary gland.

Hyperprolactinaemia or hyperprolactinemia (HP, Chiari – Frommel syndrome).

The causes are: the Hypothalamic nuclei lesion due to rheumatism, systemic autoimmune diseases, severe infections, focal poor blood circulation of the hypothalamic area, pituitary tumors, causing excessive release of certain hormones or compression of the hypothalamic nuclei, postpartum period on the background of long-term breastfeeding. Scientists have observed that the Chiari –Frommel syndrome predominantly occurs in women with a history of childbirth.

The symptoms include: Symptoms of neurogenic character (headaches, visual disturbances, sweating, hot flashes, sleep disturbances, emotional lability, irritability), the increase of both mammary glands (it is possible to palpate enlarged lobules), galactorrhea (the discharge of milk from the breast that is not associated with breast-feeding, maybe both moderate and abundant), the absence of menstrual function and menstruation, obesity of different degree or, conversely, lack of body weight, hirsutism - excessive hair growth, reduced pigmentation areola area of the nipple, atrophic changes in the mucous membranes and the entire structure of the external genitalia, infertility.

The investigations should include: X-ray examination or any kind of tomography of the skull (the focus is on the area of sella, where the pituitary gland and the hypothalamus is located), ultrasound examination of pelvic organs and breasts, cytological and histological examination of vaginal and uterine smears, Blood analysis for levels of sex hormones (FSH, LH, prolactin-releasing hormone, estrogen, progesterone), urine for the of sex hormones and their metabolites.

38

Treatment: In case the cause is the pituitary tumor the surgical treatment is needed, if the disease appeared in the classic version and is associated with the destruction of the primary nuclei of the hypothalamus, such patients are subject of conservative medical correction by hormones. For the treatment of infertility special measures are not required because, in case the hyperprolactinemia is treated the ability to fertilize is restored.

Endometriosis. Gynecological diseases of children and teens. Abnormalities of female genitalia position and development.

Amount of hours: 4 hours in practical classes

The topic includes etiology and pathogenesis. Classification. Diagnosis. Symptoms. Modern methods of treatment. Medical rehabilitation of women with endometriosis.

Gynecological diseases of children and teens. Peculiarities of symptomatic, diagnostics and treatment of the most widespread types of gynecological pathology of young girls and teens. Hyperanteflexion, retrodeviation of the uterus. Treatment, prophylaxes. Development defects of the reproductive organs. Infantilism, impaired sexual development, gonadal dysgenesis.

Questions for the modular control:

1. Endometriosis. Etiology, pathogenesis, classification, clinical picture, diagnosis and modern treatment methods.
2. Abnormalities of genitalia position. Treatment and prevention.
3. Shortcomings in the development of female genitals. Reconstructive surgery.

39 **Endometriosis** – benign hormone-dependent disease, which is based on heterotopias of endometrium (glandular and stromal components), the signs of which are nonspecific inflammation and elevated levels of enzymes on the background of disturbances of hypothalamic-pituitary-ovarian system, immune balance in the presence of genetic predispositions. The problem of endometriosis is medical and social - a common cause of disruptions of working capacity and reproductive function of women, therapeutic and diagnostic - the complexity of early clinical diagnosis and conservative treatment in the later stages of the disease, cancer - an increasing number of observations of malignant diseases at an early stage have been diagnosed as endometriosis, The occurrence in general population - 5 - 10%, it occupies the third place in the structure of gynecological diseases after inflammation and uterine fibroids and affects, according to WHO, 25 - 30% of women of reproductive age. 27% of women who gave birth, 30 - 40% woman with infertility, 10% of girls at the age of menarche and approximately 2 - 5% of women in menopause are diagnosed with endometriosis.

The hypothesis of origin according to P. J. Q. van der Linden, 1997 are: in situ formation, transplantation, the combination of the formation of transplantation and implantation of endometrium, embryological hypothesis, hypothesis of metaplasia due to inflammation or hormonal stimulation, immunological theory. The risk factors include: history of abnormal births, gynecological operations, abortions, hormonal disorders, the decline of immunological tolerance, hereditary predisposition, early menarche, age older than 35-45 years, reducing the length of the menstrual cycle, the increase of menstrual blood loss, inflammatory diseases of the genitalia, the first labor families in the older age, waiver of breast feeding, the abuse of alcohol, caffeine, adiposity. Factors that lower the risk are: use of hormonal contraceptives, previous use of IUD, smoking, belonging to a particular race.

Topical classification

- I. Genital endometriosis

- Internal endometriosis (adenomiosis)
 - Endometriosis of corpus uteri I,II,III stages depth of invasion into endometrium : glandular, cystic, fibrous (focal, nodular, diffuse) form
 - Endometriosis of the cervical canal
 - Endometriosis of the isthmic part of the fallopian tubes

- External endometriosis
 - Peritoneal endometriosis
 - ✓ of ovaries (infiltrative and tumor forms)
 - ✓ of fallopian tubes
 - ✓ of pelvic peritoneum (red, black, white form)
 - Extraperitoneal endometriosis
 - ✓ vaginal part of cervix
 - ✓ of vagina, vulva
 - ✓ retrocervical
 - ✓ of uterine ligaments
 - ✓ Parametrial, paravezical, paravaginal tissue with or without invasion into the bladder, rectum

- External-internal endometriosis
- Combinations of endometriosis (genital or extragenital pathology)

- Extragenital endometriosis (gastrointestinal tract, urinary organs, skin, navel, postoperative wounds, lungs, pleura, etc.

Symptoms include: pain (pelvic pain, algomenorrhea, dyspareunia), infertility, hemorrhagic syndrome, long ineffective treatment of chronic genital inflammation, mental disorders, impaired function of adjacent organs, absence of symptoms. Typical symptoms include: dysmenorrhea, dyspareunia (sexual disorders), infertility, pelvic pain. Less typical symptom - dyschezia (disturbance of bowel movements), dark bloody discharges before and after menses, dysfunctional uterine bleeding, dysuria. More rare symptoms are frequent urge to urination, haematuria, bleeding from the rectum. Very rare symptoms are haemoptysis (bloody cough), intestinal obstruction, edema of the kidney and ureter, skin nodes.

Chronic pelvic pain. This is the most common symptom of endometriosis. The intensity depends on localization of ectopy (especially pronounced in endometriosis of isthmus, sacro-uterine ligaments, nodular form), the extent of the process, duration of disease, individual characteristics. Menstrual cycle disturbances include progressive algomenorrhea, menometrorrhagia, bloody discharges before and after menstruation, contact bloody discharges, irregular menstruation. The disease for a long time may be hiding under the mask of various pathological processes.

Special methods of diagnosis include: X-ray examination, ultrasound, endoscopic methods including hysteroscopy and oth., CT, MRI (fiber – accuracy of diagnostics - 98-100%), cytological, histological (diagnostic accuracy 98-100%), determination of the levels of tumor markers (CA-125, HE - 4) .

Hysterosalpingography The accuracy of diagnosis ranges from 33.2 to 97.4%. Its not possible to diagnose a focal or nodal form. The procedure is done 2-3 days after menstruation or 24 hours after thorough curettage of the uterus, or 6-8 days after endometrial curettage because of the best penetration of contrast in endometrioid moves. During the procedure aqueous solutions are preferred.

Ultrasound is the best and affordable screening method. There may be difficulties in accurate diagnosis if adhesive processes are present, it is impossible to identify depth of the lesion of external genital and extragenital endometriosis In some of the cases the evaluation and visualization is not accurate.

Hysteroscopy. This method if Miniinvasive and highly informative. During the procedure there is a high incidence of diagnosing submucous nodes, adenomyosis, chronic endometritis, hyperplasia of endometrium, polyps. The procedure is done not only for diagnosis but as a surgical method of treatment too. There is a possibility to do biopsy or curettage, remove tumors or septas, separate adhesions.

Laparoscopy has a high diagnostic accuracy with direct visualization, ability to biopsy and histological examination. If it is already diagnosed appropriate therapeutic rather than diagnostic laparoscopy is applied.

Endometriosis of vagina and perineum The symptoms are: pain in the vagina and in the pelvis from mild to severe, cyclic pain that is related to the MC, the pain may be accompanied by local itching. The diagnosis criteria are: during menses painful nodes may be palpated in the vagina, after the menstruation they decrease in size or disappear leaving scars, hystological investigation may be performed.

Endometriosis of the cervix During the speculum examination cyanotic cysts may be seen. To confirm the diagnosis colposcopy and biopsy is performed. The symptoms include dark bloody discharges from vagina before and after menses. This is the only form that the pain symptom is not present.

Endometriosis of the ovaries Emndometrial cysts of the ovaries as the small heterotopias may be either unilateral or bilateral with different diameters of the cysts (from 0.5 up to 10.0 cm in diameter). The symptoms include: pain especially before and during menses, infertility, disuria, dysheziya. In case of rupture of the cysts the pain is accompanied by vomiting, unconsciousness, elevated body temperature.

Diagnoses. Bimanual examination: One or both sides tumors are palpated in the pelvis, inactive painful especially during menstruation, with bumpy surface, located at the sides or behind the uterus, with a dense capsule, limited mobility, often along with the uterus are palpated as one conglomerate. The other diagnostic measures include ultrasound, endoscopic methods (laparoscopy)(small size cyanotic nodes or cysts of various size).

Retrocervical endometriosis occurs relatively frequently. Behind the cervix a dense bumpy, sharp pain, formation of different size, limited in mobility is palpated. The symptoms are - severe pain syndrome, difficulties of bowel movement.

Extragenital endometriosis - endometriosis of the naval, endometriosis of the postoperative scar and others.

Adenomyosis.

Pathological classification V.I.Zheleznov , AN Strizhakova

- I degree. – germination of mucosa to a depth of one field of view at low magnification of the microscope
- II degree - Germination mucosa to the middle of the wall thickness
- III degree - the entire muscle layer is involved into the pathological process

Symptoms. It is believed that the clinical manifestations occur in women with II and III degree and nodular form, whereas I degree is a histological finding during hysterectomy . The course may be asymptomatic - 19-40%, algomenorrhea - 76%, hypermenorrhea - 50-66%, "chocolate" like vaginal discharges - 56%, increased dysmenorrhea - 30% (at a depth of myometrial lesions by more than 80%) , pelvic pain, metrorrhagia, dyspareunia, infertility.

Diagnoses. Bimanual examination (a moderate increase in uterine anteroposterior size, tenderness, when nodular form dense nodes are palpated, painfulness and the value of which increase during menstruation), Ultrasound (increased antero-posterior uterine size (80%), a thickening of one of the walls of uterus (81.8%), the presence of zone of increased echogenicity, occupying more than half the thickness of the myometrium (96%), hysteroscopy, hysterosalpingography, laparoscopy.

Treatment The choice of treatment strategy depends on the age of woman, localization and extent of the disease, severity of symptoms and duration of illness, fertility and the need to restore fertility, the effectiveness of previous treatment, presence of comorbidity, common therapeutic approaches. The methods of treatment include surgical therapy, hormonal therapy, during menopause if minimal manifestations of the disease are present expectant management, auxiliary (for all symptoms) therapy, IVF if infertility

Conservative therapy includes hormonal therapy, non-specific anti-inflammatory therapy, medications that affect the central nervous system, immunomodulators, antioxidants, vitamin, medications that support the function of gastrointestinal and hepatobiliary systems, physiotherapy treatment, treatment of comorbidity.

According to the consensus for the treatment of chronic pelvic pain syndrome and endometriosis (2002) the first line of treatment include Monophasic COC + nonsteroidal anti-inflammatory therapy if treatment failure. The second line of treatment is surgery (laparoscopic or laparotomy) treatment. In our country the second-line treatment should be considered a destination of agonist of gonadotropin-releasing hormone after failure are surgical treatment is performed. If untreated, the disease progresses with the development of common tumor forms, malignant degeneration.

Indications for surgical treatment of endometriosis are

- internal endometriosis combined with hyperplastic processes of ovaries and / or endometrial precancerous
- adenomyosis (diffuse or nodular form) accompanied by hyperplasia of endometrium
- Endometrial ovarian cysts (larger than 5 cm)
- No effect of conservative treatment, which was carried out continuously for 6 months
- pathological involvement of other organs and systems with violation of their functions
- purulent lesions of the uterus, affected by endometriosis
- endometriosis of navel

- adhesions of the fallopian tube in ampullar departments with infertility
- endometriosis of the postoperative scar
- presence of somatic pathology, which precludes long-term hormone therapy

With the ineffectiveness of hormone therapy, infertility, malignant forms of internal endometriosis, suspected malignancy In reproductive age – organ retaining surgery by laparotomy or laparoscopy access, conservative treatment, treatment of infertility, in perimenopause – radical surgery.

Development abnormalities

-is usually a congenital lesion

-can be accompanied by abnormalities of rectum and urinary tract

Genital infantilism

-as usual is connected with hypoproduction of releasing hormones of hypothalamus, pituitary gonadotropins and genital ovarian hormones

-genital infantilism is usually accompanied by infantilism of the female organism

Etiology

1. Hypovitaminosis
2. Chronic sepsis and psychiatric trauma, hard physical work
3. Harmful influence of physical and chemical substances of the environment and industry
4. Tobacco smoking, alcohol, drug use
5. Disturbances of endocrine glands

43

Symptoms:

1. Poor hair growth on mons pubis
2. Hypoplasia of the labia minora and majora, of mammary glands
3. Involved perineum
4. Short and narrow vagina, the fornix is not deep
5. Cervix is long, conical
6. Corpus uterus is small

Treatment:

1. Eliminate the influence of the harmful substances
2. Good nutrition
3. Eliminate physical and psychiatric stresses
4. Hormonal correction of the of the pituitary function (parlodel) and the stimulation of the ovarian function by using FSH (klostilbegit) , estrogens
5. Physical methods, biostimulators and vitamins
6. Unsaturated fatty acids and phospholipids

Underdevelopment of the uterus

The cause is the decreased production of the pituitary and ovarian hormones, especially estrogens of girls of female.

Classification

The most widespread form is hypoplasia uterinae. There are two forms: hypoplastic uterus (uterus hypoplasticus) and childrens' uterus (uterus infantilisis).

Hypoplastic uterus has two times longer corpus than the cervix, childrens' uterus has a very long cervix (two times longer than the corpus), the vaginal portion of the cervix is narrow, conical, with a small external os.

There are 3 degrees : the length of the uterus cavity is 1st- 5-7 cm, 2nd- 3,5-5 cm, 3rd- less than 3,5 cm.

Symptoms

1. oligomenorrhea
2. dysmenorrhea
3. infertility
4. low libido

Treatment

1. pituitary and genital hormones
2. sports, accurate work and relax
3. physiotherapy
4. gynecological massage

Gynatresia

Gynatresia – impaired patency of any part of the vagina and uterus

Congenital gynatresia and acquired (in children's' age because of inflammatory processes or in adolescent age because of sepsis or after a rough curettage.

Hymen atresia

Is usually diagnosed during the first menses, when the blood is accumulated in the vagina, causing cramps and tension in the hymen area, often dysuria and fatigue is observed. Sometimes the menstrual blood that does not fit in the vagina causes haematometra and haematosalpinx. The blood in the vagina can fester. Examination- the development of the external genitalia is normal, but when the labia are taken apart the introitus vaginae is not seen, the hymen may be protruded. The rectal examination - a quite soft formation is palpated, without clear boundaries, painful, that is located in the area of the vaginal tube, the uterus isn't palpated.

The treatment is surgical. The hymen is cut crosswise, the blood comes out, for the prophylaxes of reoccurant atresia the stitches are put on the edges of the section.

Atresia of the vagina

Mostly atresia of vagina is diagnosed by transverse septa or complete closure of the vagina.

Atresia of the vagina may vary by classified the location (in the upper, lower or medium part of the vagina) and the length even total atresia.

Menstrual blood is accumulated higher than the place of atresia, and hematometrae is more often diagnosed compared with the girls with gynatresia.

Basic symptoms are amenorrhea and impaired sexual life

The treatment is surgical. In case of partial atresia splitting with further application of ointment tampons is done. In case of big atresia or total atresia plastic operation with formation of an artificial vagina is performed

Atresia of the cervical canal

Is mostly found in the isthmus part or in the os.

Causes – rough curettage or electro coagulation.

Treatment - careful bouginage of the cervical canal.

Uterus atresia

The main symptom is amenorrhea. Menstrual blood is accumulated in the uterus cavity, uterus is enlarged, becoming a round elastic formation – haematometra, than the blood passes into the cavity of the fallopian tubes and into the abdominal cavity. If the ampullary part of the Fallopian tubes are impassable, the tubes are filled with blood – haematosalpinx.

Dangerous complication is the possible rupture of the uterus wall or the uterus tube with the pass of the blood into the abdominal cavity.

Treatment in case of haematometra and haematosalpinx is surgical. Plastic operations are done, in some cases supravaginal amputation of the uterus together with the changed fallopian tubes.

Aplasia vaginae

Is more widespread than the uterus aplasia and may be primary and secondary. Primary is developed because of congenital causes, often the uterus is underdeveloped too. Secondary – because of the inflammatory processes, or hard postpartum diseases and traumas.

Symptoms – inability of sexual intercourse, amenorrhea, infertility

Treatment is only surgical

Aplasia uteri

Is a rare disease. Is often accompanied by the vaginal aplasia. The only symptom is amenorrhea, that makes the girl’s parents to see a doctor. Often the ovaries are developed normally, not rarely regular ovulations are observed. Secondary sexual characteristics are normal. During ovulation the girls complain of cramps, breast engorgement. The ultrasonography does not reveal an uterus and only a rudiment is seen.

Treatment – plastic operations to form an artificial vagina.

Bifurcation of the vagina and uterus

The most pronounced form is total bifurcation of the uterus and vagina (uterus didelphys). So two uteruses are formed, each having one fallopian tube, two cervixes, two vaginas.

More widespread forms are – uterus duplex, vaginae duplex (2 half uteruses and two vaginas).

Other forms are – uterus bicornis, uterus arcuatus, uterus subseptus, vagina subseptus.

Bifurcation of the uterus and vagina, in case of normal development of the at least one of the uteruses menstrual and sexual functions can be normal, but sometimes spontaneous abortions or preterm labor is observed.

In cases of uterus bicornis and uterus arcuatus transverse position of the fetus is observed.

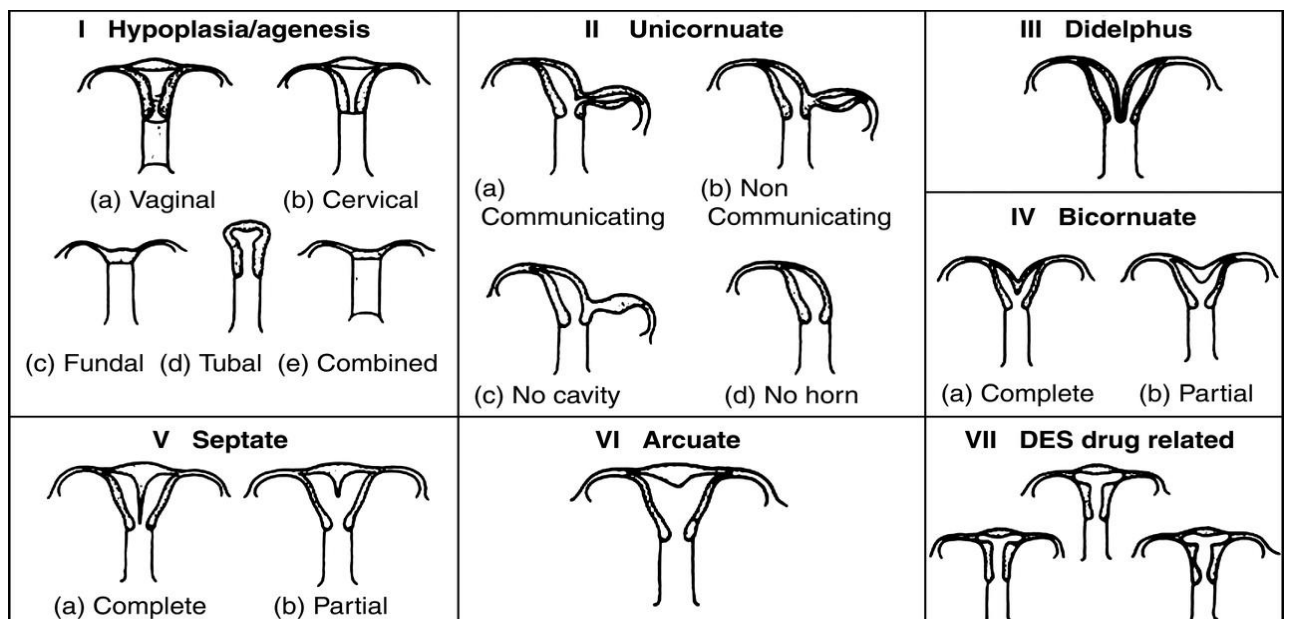
In case of bifurcation of the uterus and vagina along with the underdevelopment of uterus and ovaries the symptoms of hypofunction of the ovaries are observed (late menses, disturbances of the menstrual cycle, infertility).

Diagnoses in severe cases is not difficult. It is done by bimanual and speculum examination, sometimes hysterosalpingography sounding the uterus is done.

Treatment

It doesn’t need to be treated if not causing disruptions of menstrual sexual and childbearing functions. Surgical treatment is needed in cases of accumulation of the menstrual blood in the rudimental corn of the uterus or in the vaginal atresia and the suppuration of the haematoma. Septums in the vagina that prevent eviction of the fetus are cut. Surgical treatment in case of uterus bicornis along with septums in the cavity is done only if needed (spontaneous abortions, preterm labor, etc.). Metroplastics is done.

45



Abnormalities of the gonads

Aplasia ovariorum Is observed only in fetuses that are non-viable
Aplasia of one ovary is observed in one corn uterus, the ovary is absent, where a half of the uterus is not formed. Though in case of unicorn uterus both of the ovaries are present.

Additional ovaries. It is usually placed on the stem that connects it with the basic ovary. It doesn't have any practical significance.

Hypoplasia of the ovaries. Reduction or lack of development of ovarian stroma. Is commonly found along with underdevelopment of the uterus. Ovaries are small in size, fallopian tubes are thin, tortuous, often elongated. Secondary sexual characteristics are mild, amenorrhea or hypomenstrual syndrome, menstrual cycle is anovulatory, infertility. Treatment is the same as the treatment of the underdevelopment of the uterus.

Hyperplasia of the ovaries – hypertrophy of the ovarian stroma. Is observed rarely, genital function is not influenced. Doesn't need to be treated.

Gonadal dysgenesis – malformation of ovarian germ in the early stages of embryonic development. Ovaries consist of connective tissue stroma within which besides vessels, nerves follicles of varying degrees of development are found. The uterus is often rudimentary external genitalia are underdeveloped.

Typical form is the Turner's syndrome karyotype 45XO. External genitalia are infantile. Children have short neck, very low border of hair spread on the neck, low height, impaired intellectual development, absence of sexual development, primary amenorrhea and underdevelopment of the secondary sexual characteristics.. Ovaries are represented by white strands cerebral tissue without follicles

46

Pure form of gonadal dysgenesis_Mostly genetic disease, probably a cause of infection or effect of toxic factors. Karyotype 46XX or 46 XY. Patients who have female type of the external genitalia development see the doctor because they do not have sexual maturation, secondary sexual characteristics are absent, amenorrhea. Uterus is rudimentary, the ovaries are represented by two white laminae, no follicles are present.

Mixed form of gonadal dysgenesis. The patients have normal height, intersexual body structure, elements of female development of the external genitalia : the clitoris is enlarged, sometimes the persistency of the urogenital sinus. Somatic abnormalities are observed as in patients with Turner's syndrome.

Subclinical form of gonadal dysgenesis_ Mostly mosaic karyotype is observed 45XO/46XX

Treatment: patients with karyotype 46XY or with mosaic karyotype with the presence of fragments of Y chromosome have to undergo surgical treatment with the removal of the gonads, because of the high risk of malignisation. Patients with 46 XX karyotype are treated by hormonal therapy. The treatment is started with estrogens, continuing with estrogens and progesterones.

Hermaphroditism (testicular feminization) It is the presence of individual male and female gonads in the same organism. There is true and false hermaphroditism. True hermaphroditism – the same person has two functioning gonads of both sexes.

False hermaphroditism- in the same person has gonads of one sex and external sexual characteristics and secondary sex signs of a strong resemblance with the other sex. There is male and female pseudohermaphroditism, which is determined by the character of the gonads.

There are the following types of female hermaphroditism:

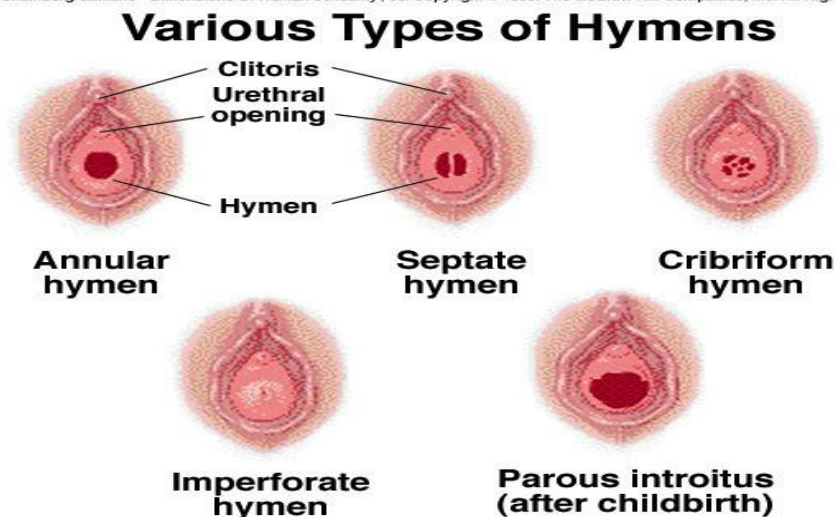
- 1 Congenital adrenogenital syndrome
2. Induced false hermaphroditism
3. Women pseudohermaphroditism caused by a tumor of adrenal glands and ovaries.

Pediatric gynecology

Pediatric gynecology is an emerging subspecialty involving the collaborative efforts of health professionals from gynecology, pediatrics, and urology. From birth through the first 8

weeks of life, the female infant is under the influence of maternal estrogen. This has a profound effect on the appearance of the female genitalia. The labia majora appear full and puffy and there is a significant thickening and enlargement of the labia minora. Maternal estrogen exposure may stimulate a mucoid discharge or a small amount of bloody vaginal discharge but these effects begin to recede in ~2 weeks. Estrogen levels continue to fall until about 1½ to 2 years of age, although gonadotropins continue to cause some ovarian stimulation and endogenous production of estrogen during this time. From the age of 3 until 8 or 9 years the estrogen levels are at their lowest and the appearance of the female genitalia is very different. Surrounding the mouth of the vaginal orifice is the rim of tissue called the hymen. The once thick, redundant hymen becomes thin and translucent with varying configurations. The hymen may be annular, crescent-shaped, redundant, and irregular or teardrop-shaped

Byer/Shainberg/Galliano *Dimensions Of Human Sexuality*, 5e. Copyright © 1999. The McGraw-Hill Companies, Inc. All Rights Reserved.



47

Some less common variations of the hymen include the imperforate hymen, microperforate, and the septated hymen. In most instances, correction of these variations is not necessary until the girl reaches puberty.

The pH of the vagina is alkaline and consists primarily of columnar epithelium. Examination of the child with gynecologic complaints should begin with plotting the height and weight on a growth chart. Starting with less-threatening portions of the exam, such as checking the ears, neck, heart, and lungs, may help to reassure the child. Evaluating the sexual developmental stage of the breasts is an important part of any prepubertal exam. Inspection and palpation of the breasts to evaluate breast tissue or enlargement of the areola may be an early indication of puberty. An abdominal examination generally is met with little resistance.

The genital examination should be performed in the presence of the child's mother or close relative. The doctor if male should be accompanied by a doctor of female gender. The genital examination should be performed in a methodical manner with careful visualization of the genital structures described earlier, with careful notation of abnormalities or variations. In older females, the focus of the examination is to evaluate the cervix and internal genital structures but with the prepubertal female, the external visualization of the genitalia can diagnose the majority of the problems that will be discussed later in this chapter. Rarely is there a need to perform an internal examination unless specific problems such as vaginal bleeding, recurrent or unresponsive vaginal discharge, suspected foreign body, or suspected vaginal tumor require further evaluation. The preferred means to evaluate these problems is to do a rectal examination

orn examination under anesthesia to do it using a fiberoptic vaginoscope, hysteroscope, pediatric cystoscope, or endoscope with irrigating properties.

The common diseases include:

Labial adhesion. Reported to occur in 1.4% of infants, labial adhesions may result in partial to complete fusion of the labia minora. The agglutination usually begins posteriorly and extends upward toward the clitoris, leaving a small opening anteriorly in most cases. The fused portion of the labia is usually identified by a thin line of demarcation or raphe. Extreme cases include nearly complete labial closure with resultant urinary retention and/or infection. The etiology has been postulated as estrogen deficiency and inflammation with thinning of the superficial mucosal layers. Treatment is not always necessary as resolution has been known to occur spontaneously at puberty once estrogen is produced. However, therapy is quite simple and efficacious, consisting of applying estrogen cream to the fine thin raphe twice a day for 2 weeks followed by once daily application for 2 weeks.

Imperforate hymen (see the page 47).

Vulvitis. Prepubertal females may occasionally complain of vulvar discomfort or itching. Persistent symptoms noted by the parent/caregiver or the child often raise great concern. The first step is to take a careful history in regards to any possible irritants. Questions should be directed to the level of hygiene, urinary incontinence, frequency of diaper changes, and bathing habits. Common organisms causing prepubertal vulvitis are candida, pinworms, and group A β -hemolytic streptococcus. In case of candidosis the treatment consists of antifungal creams such as clotrimazole, miconazole, or butaconazole applied twice a day to the affected area for 10 to 14 days or until rash is cleared. Bacterial causes of vulvitis such as group A β -hemolytic streptococcus should be treated with an appropriate antibiotic for 2 weeks and occasionally for longer periods of time (up to 4 weeks). Additional therapy may consist of sitz baths with baking soda or colloidal oatmeal added one to two times daily. Soap should be avoided and the area can be dried thoroughly with a hair dryer on low heat or cool air. Hygiene must be emphasized along with thorough hand washing before and after using the toilet.

Non specific vulvovaginitis. Several instigating factors that can contribute to nonspecific vulvovaginitis include: poor hygiene practices at home or daycare program, inadequate front-to-back wiping, smaller labia minora, which are less protective of the vestibule, with a short distance from the anus to vagina, vulvovaginal epithelium that is not well estrogenized and thus thinner and more prone to irritation, foreign body such as toilet paper, small toys, or pieces of cloth, which may be inadvertently inserted in the vagina by the child, chemical irritants such as bubble baths, shampoos, or bath oils, and certain deodorant soaps, dermatologic conditions such as eczema and seborrhea, chronic disease and altered immune status, sexual abuse. Symptoms of nonspecific vulvovaginitis include itching, dysuria, and discharge. In these instances, routine vulvar hygiene measures as listed below, are followed. Recommended vulvar hygiene measures include: use front-to-back wiping with warm water after a bowel movement, avoid deodorant soaps, bubble baths, or lotions, wear only white cotton underwear or if still in diapers, change soon after each urination or bowel movement, use unscented toilet paper, keep vulvar area clean and dry, wash hands prior to and following use of toilet, use mild bath soap (e.g., Dove, Neutrogena, Basis, Oilatum, or Cetaphil), remove wet bathing suits soon after exiting pool area

Condyloma accuminata. Condyloma acuminata, or "genital warts," caused by human papilloma virus (HPV) is seen in the prepubertal child more often today than in the past). Condyloma resembles fleshy tumors in the unestrogenized vulvar mucosa but may have the more verrucous characteristics of adult lesions on the perineum and perianal areas. Condyloma usually

present as asymptomatic lesions noted by the parent or caregiver. Large lesions, however, may present with a child complaining of pain on urination or defecation. more recently the advent of imiquimod cream (Aldara), an immune response modifier supplied in a cream base, has eased and revolutionized therapy for external genital warts. A thin layer of cream is applied to the wart(s) at bedtime and left on for 6 to 10 hours, after which it is washed off. Therapy is for 3 days a week (i.e., Monday, Wednesday, and Friday) and continued until the warts are completely gone, or up to 16 weeks.

Abnormalities of female genitalia position

Uterus should be located in the center of small pelvis at the same distance from its walls, pubic center and sacrum. The organ is attached to the walls of small pelvis by ligamentous apparatus. At normal location, uterine body and cervix form an obtuse angle, which is directed forward.

Version causes changing of proportions between body and cervix.

Sometimes version is not manifested by any symptoms, but patients may have complains about lower back pain, which enhance during menstruation, sense of pressure in lower abdomen, dysuria, and in some cases – about pain during sexual intercourse.

Anteversio – normal position of the uterus (tilted forward).

Retroversio – tilted posteriorly.

Dextroversio – tilted to the right.

Sinistroversio – tilted to the left.

49 Etiology. Typically, this pathology is caused by past inflammation processes of the reproductive system internal organs, weakness of ligaments that fix the uterus, frequent constipations, difficult labor, abortions, which have complicated by inflammations, uterine tumors (myoma, fibroid,)ovarian cysts.

Flexio is an angulation of uterus. There are the following forms of flexio: anteflexio – bend forward and retroflexio – bend backwards.

Anteflexio is a normal position. There is an obtuse angle opened anteriorly, formed between uterine body and cervix.

In pathological cases – anteflexio – when the angle between the body and cervix is escalating, there is observed a version.

Retroflexio is a bending of the uterus backwards, at which the angle between body and cervix is reverted. With this type of flexio body of the organ is reflexed, while cervix is directed anteriorly.

Retrodeviation of the uterus

Retroflexio and retroversio is called retrodeviation.

- 1st degree the uterus is tilted posteriorly but anteflexio is preserved.
- 2nd- the uterus is tilted posteriorly without a distinguished angle between uterus body and cervix
- 3rd – uterus is tilted posteriorly with retroflexio.

Generally, the majority of women suffering from a retroverted uterus experience no symptoms. However, if symptoms do present, the two most commonly-occurring symptoms include: pain during sexual intercourse, particularly vaginal intercourse (dyspareunia), pain during menstruation (dysmenorrhea).

Diagnosis usually consists of:

- a pelvic exam
- an abdominal ultrasound

Most of the women do not experience discomfort because of the retroverted uterus, but in case there are complains, the possible treatment may be following:

- Exercises: Women can perform knee-to-chest exercise in order to encourage the uterus to slip back into its proper place. Unfortunately, this tends to be a temporary solution for the problem.
- Pessaries: A pessary is a plastic device that is worn inside of the vagina. It helps to support the uterus in the proper position. However, these devices can only be worn in the short term because of the risk for developing a vaginal infection.
- Surgery: Surgery for a retroverted uterus is available. Known as the UPLIFT procedure, this procedure works to reposition the uterus by cutting and shortening the ligaments that support it. UPLIFT is a laparoscopic surgery that is performed with the aid of a small camera.
- Reposition of the uterus.

Uterine displacement

Displacement of the uterine body and cervix with respect to the pelvic midline – uterine disposition.

The displacement can be directed:

- anteriorly;
- posteriorly;
- laterally.

At the same time, the organ itself can be mobile or fixed with adhesions to the walls of small pelvis and to the adjacent organs.

Vertical displacement:

- elevated uterus;
- descent of walls;
- prolapse of uterus from vagina.

Uterine walls descent

Weakness of muscles and small pelvis structures, due to which uterus descends below the normal level, but does not protrude from vulvar slit. Uterine walls descent often occurs in women after childbirth.

Quite often women confuse this pathology with a tumor or cancer. At the advanced stage it is difficult not to notice cervical prolapse, when uterus goes beyond vulvar slit. This pathology is diagnosed in 25% of women at the age of 30-45 years, and at an older age – in every third.

Etiology: congenital defects of pelvic organs, connective tissue disorders, affection of small pelvis muscles, their weakening;

Symptoms: feeling of pressure in the lower abdomen, dragging pain in vagina, later there may occur pain in sacrum, and sometimes in lower back, frequent or difficult urination, stress urinary incontinence, vaginal discharges sometimes spotting, foreign body sensation in vagina.

Treatment: the small degree should prevent from further development of the disease. They

should be recommended to avoid heavy lifting and hard physical exercises, carry out prevention of constipations, to wear a bandage, application of uterine rings, to perform special exercises. If the surgical treatment is contraindicated then vaginal tampons and pessaries (rubber rings) are recommended. The surgical treatment most commonly includes the intravaginal surgeries.

Uterine prolapse

Uterine prolapse is a displacement downwards; upon this, the cervix completely or partially protrudes beyond the genital slit.

Classification:

- Partial prolapse – uterine body is located outside the genital slit, only the vaginal part of the cervix comes out the genital slit. Due to elongation of uterine cervix, with partial uterine prolapse, ratio of the body and cervix sizes may be affected.
- Complete prolapse – uterine body and cervix are located below the genital slit. In the case of complete prolapse of the uterus, usually it is not elongated; body and cervix dimensional ratio is preserved.

The symptoms are similar to the symptoms of the descent of the vaginal walls.

Treatment:

1. Non-surgical options

- Exercise – Special exercises, called Kegel exercises, can help strengthen the pelvic floor muscles. This may be the only treatment needed in mild cases of uterine prolapse. To do Kegel exercises, tighten your pelvic muscles as if you are trying to hold back urine. Hold the muscles tight for a few seconds and then release. Repeat 10 times. You may do these exercises anywhere and at any time (up to four times a day).
- Vaginal pessary – A pessary is a rubber or plastic doughnut-shaped device that fits around or under the lower part of the uterus (cervix), helping to prop up the uterus and hold it in place. A health care provider will fit and insert the pessary, which must be cleaned frequently and removed before sex.
- Estrogen replacement therapy (ERT) – Taking estrogen may help to limit further weakness of the muscles and other connective tissues that support the uterus. However, there are some drawbacks to taking estrogen, such as an increased risk of blood clots, gallbladder disease and breast cancer. The decision to use ERT must be made with your doctor after carefully weighing all of the risks and benefits.

2. Surgical options

- Hysterectomy – Uterine prolapse may be treated by removing the uterus in a surgical procedure called hysterectomy. This may be done through an incision made in the vagina (vaginal hysterectomy) or through the abdomen (abdominal hysterectomy). Hysterectomy is major surgery, and removing the uterus means pregnancy is no longer possible.
- Uterine suspension – This procedure involves putting the uterus back into its normal position. This may be done by reattaching the pelvic ligaments to the lower part of the uterus to hold it in place. Another technique uses a special material that acts like a sling to support the uterus in its proper position. Recent advances include performing this with minimally invasive techniques and laparoscopically (through small band aid sized incisions) that decrease post operative pain and speed recovery.

Rotation of the uterus – it's a rotation of uterus with the cervix around its vertical axis from left to the right or conversely.

Torsio uteri – rotation of the uterus without cervix around its vertical axis

Inversio uteri - Uterine inversion is a potentially fatal childbirth complication with a maternal survival rate of about 85%. It occurs when the placenta fails to detach from the uterus as it exits, pulls on the inside surface, and turns the organ inside out. It is very rare.

Benign diseases of female reproductive organs.

Gynecological aspects of mammary glands diseases

Amount of hours: 2 hours of lecture, 4 hours in practical classes

The topic includes Benign diseases of female reproductive organs. Benign diseases of the ovaries: epithelial, sex cord stromal tumors, germ cell and lipid cell tumors. The concept of cysts and cystome.

Benign diseases of the uterus. Uterus fibroid. Symptoms, diagnosis and treatment.

Questions for the modular control:

1. The concept of cysts and cystoma. Classification of the ovary tumors. Symptomatic, diagnosis and treatment.
2. Uterus fibroid. Classification, symptoms and diagnosis.
3. Conservative and surgical methods of fibroid treatment. Indications for surgical treatment.

Benign lesion of the uterus.

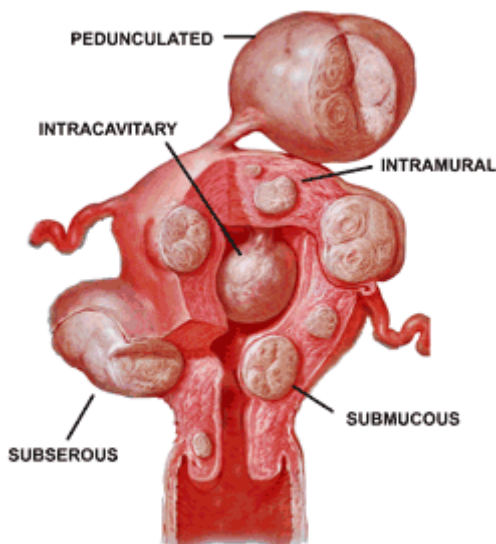
Fibroid is a commonest benign tumor of the uterus and also the commonest benign solid tumor in female. Histologically tumor is composed of smooth muscle and fibrous connective tissue, so named as uterine leiomyoma, myoma or fibromyoma.

Incidence – at least 20 per cent of women at the age of 30 have got fibroid in their wombs. The incidence of symptomatic fibroid in hospital outpatient is about 3 per cent.

Etiology still remain unclear. The prevailing hypothesis is that, it arises from the neoplastic single smooth muscle cell of myometrium. The possible causes are: chromosomal abnormality (rearrangements, deletions), role of polypeptide growth factors, a positive family history is often present. The growth is predominantly oestrogen-dependent tumour. Increased risk factors include nulliparity, obesity, hyperoestrogenic state, black woman, reduced risk multiparity, smoking.

Classification:

- The fibroid of the uterus body
- The fibroid of the cervix
 - Anterior
 - Posterior
 - Lateral
 - Central



Depending on the location of the nodes the fibroid are divided into:

- Interstitial or intramural (about 70%)
- Subperitoneal or subserous (15%, may be subserous, pedunculated, or broad ligament fibroid)
- Submucous (5%) - it produces maximum symptoms

Symptoms:

- Asymptomatic (75%). They may be accidentally discovered by the physician during routine examination or at laparotomy or laparoscopy.
- Menstruation abnormalities. Menorrhagia is the classic symptom of symptomatic fibroid,
- Metrorrhagia or irregular bleeding.
- Dysmenorrhea
- Infertility
- Pain in the lower abdomen
- Abdominal swelling (lump)
- Pressure symptoms
- Abdominal enlargement
- Recurrent pregnancy loss (miscarriage, preterm labour)

Diagnosis:

1. Abdominal examination – if the uterus body is enlarged up to 12 weeks of pregnancy, the uterus body may be palpated through the abdomen. It feels firm, more towards hard, surface in nodular, mobility is restricted.
2. Percussion – the swelling is hard on percussion
3. Pelvic examination: the swelling of the uterine. The size of the uterus is evaluated in weeks, according to size corresponding the gestational term. The uterus is not felt separated from the swelling, the cervix moves with the movement of the tumour felt per abdomen, with the exception subserous pedunculated fibroid. The doctor should evaluate the size, motility, nodularity.
4. Ultrasound and Colour Doppler: uterine contour is enlarged and distorted, may be hypoechoic or hyperechoic. Transvaginal ultrasound can accurately assess the myoma location, dimensions and volume, is mostly done in case of fibroids less than 12 weeks of gestation.
5. Saline infusion sonography
6. Magnetic resonance imaging – not used routinely for the diagnosis
7. Laparoscopy – it may differentiate a pedunculated fibroid from ovarian tumour not revealed by clinical examination.
8. Hysteroscopy is of help to detect submucous fibroid in unexplained infertility and repeated pregnancy wastage.
9. Uterine curettage – in the presence of irregular bleeding, to detect any co-existing pathology and to study the endometrial pattern, curettage is helpful. It additionally helps to diagnose a submucous fibroid by feeling a bump.

Cervical fibroid. . The symptoms are due to pressure effect on the surrounding structures. Anterior cervical –bladder symptoms, posterior cervical – rectal symptoms in the form of constipations, lateral cervical – vascular obstruction, that may lead to haemorrhoids and oedema legs, central cervical – predominantly bladder symptoms. Treatment – myomectomy, hysterectomy

Differential diagnosis. The fibroids should be differentiated from pregnancy, full bladder, adenomyosis, myohyperplasia, ovarian tumour.

Complications of the fibroids:

- Persistans menorrhagia, metrorrhagia or continued vaginal bleeding that leads to severe anaemia
- Severe intraperitoneal haemorrhage due to rupture of veins over subserous fibroid
- Ischemia or necrosis of the fibroid nodes, leading to peritonitis
- Sarcoma (malignant changes in the uterus)

Polyps is a clinical entity referring a tumour attached by a pedicle.

Classification:

- Benign

- Mucous
- Fibroid
- placental
- Malignant
 - De novo
 - Secondary changes of benign polyp

Mucous. The commonest type of benign uterine polyp. It may arise from the body of the uterus or from the cervix. Risk factors – hormone replacement therapy, tamoxifen therapy, diabetes, hypertension, obesity, etc. During speculum examination a small polyp approximately 1-2 cm in size, looks reddish and feels soft is seen in the cervical canal. The pedicle may be at times long enough to make the polyp protruded from the cervix. Predictors of malignancy – more than 10 mm in size, postmenopausal status and abnormal uterine bleeding. Symptoms: asymptomatic, irregular uterine bleeding, contact bleeding, excessive vaginal discharge.

Fibroid polyp. May arise from the body of the uterus or from the cervix. Is almost always due to extrusion of a submucous fibroid into the uterine cavity.

Cervical fibroid polyp. Symptoms include intermenstrual bleeding, colicky pain in the lower abdomen due to uterine contractions, excessive vaginal discharge, sensation of something coming down. Speculum examination – the polyp is visualized, the color, size, the attachment of the pedicle and the part of the uterus the pedicle is attached to is inspected. Bimanual examination – the uterus is often bulky, the cervix may be patulous the polyp is felt distinctly outside the external os.

Placental polyp. A retained bit of placental tissue when adherent to the uterine wall gets organized with the surrounding blood clots. Symptoms – a history of recent childbirth, irregular vaginal bleeding, offensive vaginal discharge.

Treatment of polyps. The polyps should be removed using either hysteroscopy or by performing dilatation and curettage. All the polyps are sent to histological investigation. After the operation the antibiotics are prescribed.

The probable causes of recurrent polyps may be – inflammatory diseases, not complete removal of the poly, malignancy.

Medical management:

1. Non-hormonal therapy – mostly symptomatic treatment: medications for haemostasis, non-steroidal anti-inflammatory drugs, antispasmodics, treatment of the states, that can cause the growth of the fibroid (thyroid pathology, inflammatory processes of the genitalia), normalization of metabolism (antioxydants, antiagregants, polyvitamins, fitotherapy).
2. Hormonal treatment – COC, progestagens, agonists of gonadotropin releasing hormone, progestages releasing IUD.

Surgical treatment

The type of operation depends on the age of the women, the course of the disease, the need to preserve the reproductive function, the location and number of nodes.

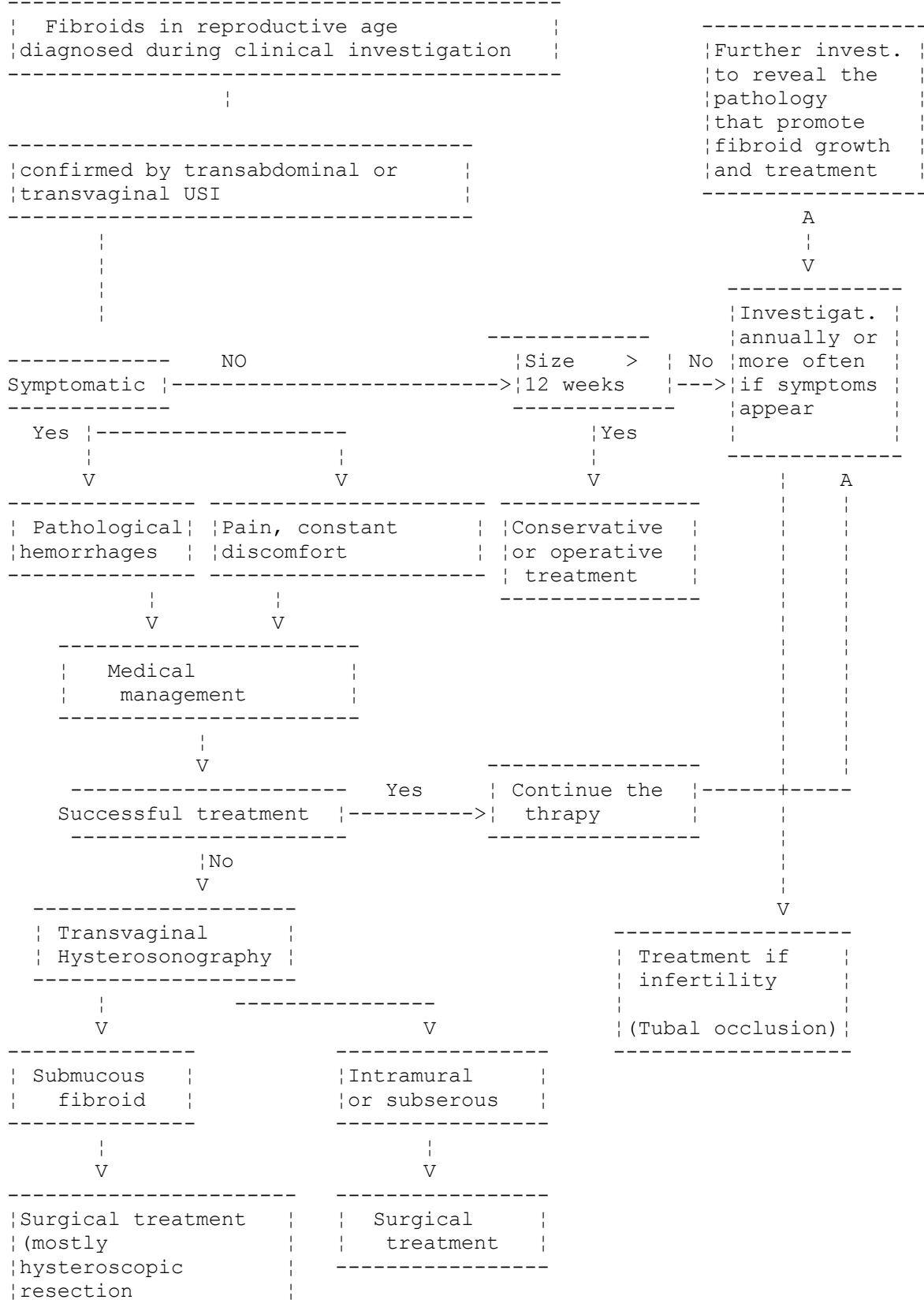
Indications for surgical treatment:

1. Symptomatic fibroid (with heamoragic and pain syndrome, anemia, symptoms of the compression of the adjacent organs)
2. The size of the uterus 13-14 weeks of gestation and more
3. A submucous node
4. A suspicion of a node malnutrition
5. A subserous pedunculated node (because of the risk of torsion)
6. Rapid growth of the fibroid (4-5 weeks during a year or more) or resistancy to GnRH agonists therapy
7. Fibroid accompanied by premalignant pathology of endometrium and ovaries

- 8. Infertility because of the fibroid
- 9. Appehdages commorbidity

Management of fibroids

Fibroid management algorithm



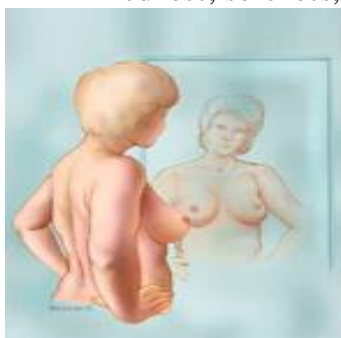56

Investigation and diseases of the mammary glands

The self examination of the mammary glands include:

Step 1: Begin by looking at your breasts in the mirror with your shoulders straight and your arms on your hips.

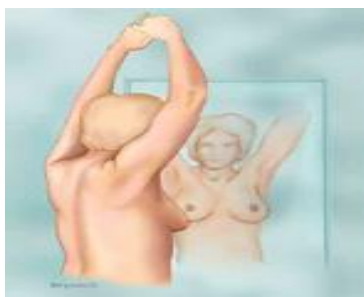- ✗ Here's what you should look for:
- ✗ Breasts that are their usual size, shape, and color
- ✗ Breasts that are evenly shaped without visible distortion or swelling
- ✗ If you see any of the following changes, bring them to your doctor's attention:
- ✗ Dimpling, puckering, or bulging of the skin
- ✗ A nipple that has changed position or an inverted nipple (pushed inward instead of sticking out)
- ✗ Redness, soreness, rash, or swelling



57

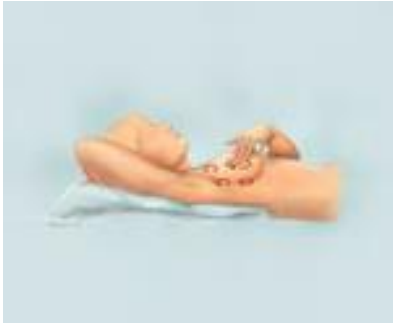Step 2: Now, raise your arms and look for the same changes.

Step 3: While you're at the mirror, look for any signs of fluid coming out of one or both nipples (this could be a watery, milky, or yellow fluid or blood).

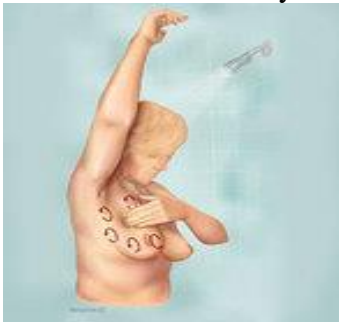

Step 4: Next, feel your breasts while lying down, using your right hand to feel your left breast and then your left hand to feel your right breast. Use a firm, smooth touch with the first few finger pads of your hand, keeping the fingers flat and together. Use a circular motion, about the size of a quarter.

- ✗ Cover the entire breast from top to bottom, side to side — from your collarbone to the top of your abdomen, and from your armpit to your cleavage.
- ✗ Follow a pattern to be sure that you cover the whole breast. You can begin at the nipple, moving in larger and larger circles until you reach the outer edge of the breast. You can also move your fingers up and down vertically, in rows, as if you were mowing a lawn. This up-and-down approach seems to work best for most women. Be sure to feel all the tissue from the front to the back of your breasts: for the skin and tissue just beneath, use light pressure; use medium pressure for tissue
- ✗ in the middle of your breasts; use firm pressure for the deep tissue in the back. When you've reached the deep tissue, you should be able to feel down to your ribcage.



Step 5: Finally, feel your breasts while you are standing or sitting. Many women find that the easiest way to feel their breasts is when their skin is wet and slippery, so they like to do this step in the shower. Cover your entire breast, using the same hand movements described in step 4.



Clinical breast exam: A clinical breast exam is performed by a healthcare professional who is trained to recognize many different types of abnormalities and warning signs. This in-office exam will most likely be completed by your family physician or gynecologist at your annual exam, whereas your breast self-exam is something every woman should do at once at month at home.

A visual check of skin and tissue: During a clinical breast exam, your healthcare provider checks your breasts' appearance. You may be asked to raise your arms over your head, let them hang by your sides, or press your hands against your hips. These postures allow your healthcare provider to look for differences in size or shape between your breasts. The skin covering your breasts is checked for any rash, dimpling, or other abnormal signs. Your nipples may be checked to see if fluid is expressed when lightly squeezed.

A manual check for unusual texture or lumps. Using the pads of the fingers, the doctor inspects entire breast, underarm, and collarbone area for any lumps or abnormalities. It is worth noting that some women have breast tissue that appears to be full of tiny fibrous bumps or ridges throughout the breast tissue, known as fibrocystic breasts. A suspicious lump—the type your physician is checking for—is generally about the size of a pea before anyone can feel it in the breast tissue. The manual exam is done on one side and then the other. Your healthcare provider will also check the lymph nodes near the breast to see if they are enlarged.

An assessment of any suspicious area. If a lump is discovered, the doctor should note its size, shape, and texture, ability to move. Benign lumps often feel different from cancerous ones, but any lump found will likely need to be examined with further diagnostic measures. It may be helpful to know that lumps that appear soft, smooth, round, and movable are likely to be either benign tumors or cysts. A lump that is hard and oddly-shaped and feels firmly attached within the breast is more likely to be cancer, but further tests are needed to diagnose the problem.

History taking: The number and date of labor and abortions, disorders of the menstrual cycle, onset (acute, chronic), the nature of pain (single, bilateral, continuous or connected with menses), presence of abnormal discharge from the nipple and their nature, loss of weight, anemia, age over 35 years, family history, the presence of cancer pathology in relatives, age of menarche to 12 years, first birth after age 30, menopause after age 55, the results of previous

atypia in biopsy material, alcohol abuse (use of more than 100 ml of spirits or wine 200 ml per day), the use of exogenous hormones - continuous use of COCs and HRT - more than 10 years.

Diagnostic measures: mammography, ultrasound, MRI, biopsy

The American Cancer Society's current Breast Cancer Screening Guidelines recommend:

- ✗ Yearly mammograms at age 40 and continuing for as long as a woman is in good health
- ✗ Breast exam about every 3 years for women in their 20s and 30s and every year for women 40 and over
- ✗ All women should know how their breasts normally look and feel and should report ANY breast change promptly to their doctor or nurse. Breast self-exam (BSE) is an option for women starting in their 20s.

Screening methods according to the Ukrainian guidelines:

- ✗ Self exam- after 20 years monthly
- ✗ Clinical exam of a general doctor – all age groups – annually
- ✗ Mammography – after 40 years annually

Ultrasound is used in case of screening for breast cancer in young women (under 40), monitoring breast state in women taking hormones (progestins, COC HRT), the interpretation of mammography data to identify patterns of formations, dynamic monitoring of size of tumors in young women, control examination after biopsy and surgery on the breast.

Instrumental methods of investigations: mammography, cytological examination of pathological secretions of the mammary glands, puncture (aspiration) biopsy, galactography - contrast study of the milk ducts, transillumination - translucence the breast.

Classification of benign diseases of mammary gland:

- ✗ Epithelial (adenoma, fibroadenoma, adenofibroma, papilloma of the milk ducts);
- ✗ Nonepithelial (fibroma, lipoma, chondroma, osteoma, angioma);
- ✗ Cystic (lactic cysts, mastopathy).

✗ Adenoma: glandular tumor size 1-3 cm in diameter, lobular, painless, mobile, has a capsule, located on the periphery of the gland easily determined by palpation.

Consistency is close to the consistency of the breast.

✗ Fibroadenoma: tumor composed of glandular and large amounts connective tissue, a capsule. Fibroadenoma makes up the bulk of benign tumors, appear mostly in girls and young women. Consistency is denser than in adenomas. The tumor is clearly separated from the surrounding tissue, mobile, painless. Size varies, usually 1-2 cm in diameter.

✗ Fibroma - connective tissue tumor of hard consistency, rounded shape.

✗ Lipoma - a tumor of adipose tissue.

✗ Chondroma and osteoma are characterized by high firmness and special histological structure.

✗ Angiomas. Angiomas localized deep in the gland have a practical significance. Grow slowly.

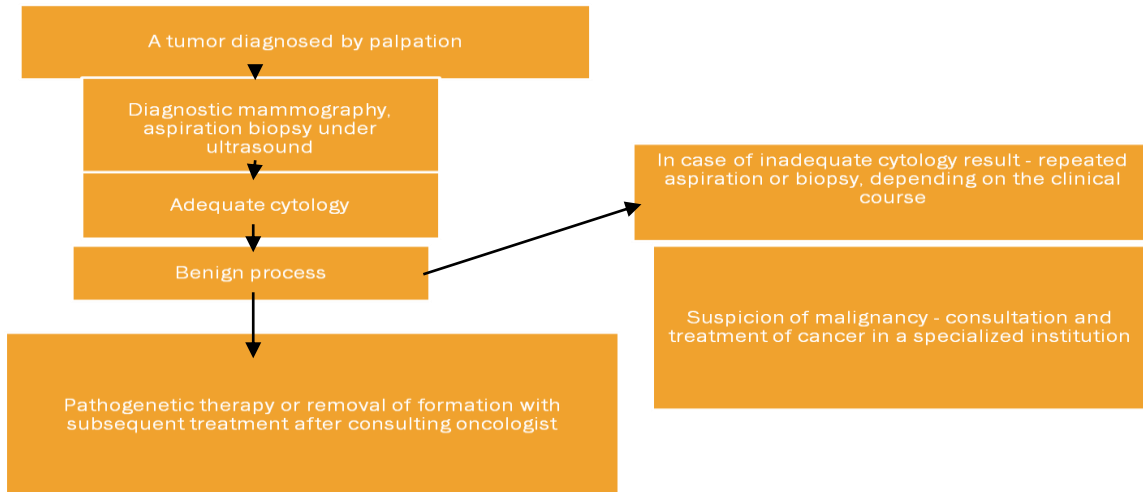
✗ Mastopathy. benign breast tumors caused by proliferative changes in gland tissues that develop during the menstrual function. Mastopathy often develops in the age of 30-50 years. Classification. Based on the clinical features distinguish the following forms mastopathy:

- ✗ Nodal
- ✗ 2. Diffuse.

✗ Papillomas of milk ducts(Mintz disease) represent single or multiple papillary proliferation of the epithelium, often localized in the region of the sinus ducts have a soft consistency and small size (0.5-0.6 cm). Grow slowly for a long time do not manifest themselves. The presence of bleeding from the nipple is often the only symptom that brings the patient to the doctor.

- ✘ Milk cysts (halaktotsele). Formed in the mammary gland during lactation by type of retention cysts as a result of obstruction of milk ducts after suffering from mastitis or undetectable inflammation of its wall.

Algorithm of management if diagnosed with a tumor in the mammary gland.



60

Medications that are recommended for patients with dyshormonal disorders of the reproductive system in order to prevent the development of breast cancer in Ukraine:

- ✘ Anti-stress drugs
- ✘ Vitamins, antioxidants
- ✘ Immunomodulators, adaptogens
- ✘ Medications that improve the function of the gastrointestinal tract
- ✘ Hormone and hormone like medications

Benign disease of the ovaries

The benign diseases of the ovaries include ovarian cysts and cystomas.

Each month during your menstrual cycle, a follicle grows on your ovary. A follicle is where an egg developing. Most months, an egg is released from this follicle. This is called ovulation. If the follicle fails to break open and release an egg, the fluid stays in the follicle and forms a cyst. This is called a follicular cyst.

Another type of cyst occurs after an egg has been released from a follicle. This is called a corpus luteum cyst. Such cysts often contain a small amount of blood. Ovarian cysts are more common from puberty to menopause. This period of time is known as the childbearing years. Ovarian cysts are less common after menopause.

Classification of the benign tumors of the ovaries.

- The World Health Organization Histological Classification for ovarian tumors separates ovarian neoplasms according to the most probable tissue of origin: surface epithelial (65%), germ cell (15%), sex cord-stromal (10%), metastases (5%), miscellaneous
- Surface epithelial tumors are further classified by cell type (serous, mucinous, endometrioid, etc) and atypia (benign, borderline [atypical proliferation, low malignant potential] or malignant; malignant may be invasive or non-invasive)

- Most malignant tumors are surface epithelial (90%)

Surface epithelial - stromal tumors

- **Serous tumors:**
 - Benign (cystadenoma)
 - Borderline tumors (serous borderline tumor)
 - Malignant (serous adenocarcinoma)
- **Mucinous tumors, endocervical-like and intestinal type:**
 - Benign (cystadenoma)
 - Borderline tumors (mucinous borderline tumor)
 - Malignant (mucinous adenocarcinoma)
- **Endometrioid tumors:**
 - Benign (cystadenoma)
 - Borderline tumors (endometrioid borderline tumor)
 - Malignant (endometrioid adenocarcinoma)
- **Clear cell tumors:**
 - Benign
 - Borderline tumors
 - Malignant (clear cell adenocarcinoma)
- **Transitional cell tumors:**
 - Brenner tumor
 - Brenner tumor of borderline malignancy
 - Malignant Brenner tumor
 - Transitional cell carcinoma (non-Brenner type)
- **Epithelial-stromal:**
 - Adenosarcoma
 - Carcinosarcoma (formerly mixed Muellierian tumors)

Sex cord - stromal tumors

- **Granulosa tumors:**
 - Fibromas
 - Fibrothecomas
 - Thecomas
- **Sertoli cell tumors:**
 - Leydig cell tumors
- Sex cord tumor with annular tubules
- Gynandroblastoma
- Steroid (lipid) cell tumors

Germ cell tumors

- **Teratoma:**
 - Immature
 - Mature
 - Solid
 - Cystic (dermoid cyst)
- Monodermal (e.g., struma ovarii, carcinoid)

- Dysgerminoma
- Yolk sac tumor (endodermal sinus tumor)
- Mixed germ cell tumors

Malignant, not otherwise specified

- **Metastatic cancer from nonovarian primary:**
 - Colonic, appendiceal
 - Gastric
 - Breast

1. Non-neoplastic non-proliferative ovarian tumours

Ovarian cyst - a cavity filled with liquid contents, which occurs as a result of delays and excessive secretion of fluid. Most cysts are localized in the ovary (follicular cysts, corpus luteum cysts, theca lutein cysts dermoid cyst) and appendage located above the ovary (paraovarian cysts).

Follicular cyst of the ovary

Follicular cyst of ovary - a single-capillary tumor formation of elastic consistency with transparent content, which is caused by accumulation of fluid in the cystic atretic follicle. It can occur at any age, most often - due after inflammation. In such formations is non-neoplastic process is observed.

Clinic. The main symptom - pain at the bottom of the abdomen, more rarely - menstrual irregularities. Cyst determined at the side or in front of the uterus. The consistency is elastic, not very painful during palpation, its diameter less than 10 cm. Often accompanied by inflammation of the appendages.

Treatment. Observations within 2-3 menstrual cycles. If the tumor lesion does not resolve, the surgery is recommended - resection or oophorectomy. This is necessary because before the operation it is hard to differentiate cysts from serous cystoma of the ovary. In menopause and postmenopause hysterectomy with appendages is performed.

Corpus luteum cyst

It happens relatively rare (2-5% in respect of all ovarian tumors). Corpus luteum cyst - a retention lesion diameter up to 8 cm, filled with light transparent liquid, sometimes mixed with blood. The walls of the cyst are thick. It is observed in women aged from 16 to 55 years.

Clinic. The main complaint - pain in the lower abdomen due to the accompanying inflammation of appendages. There are no specific clinical signs. The complications are - bleeding into the cyst cavity. Corpus luteum cyst often palpable at the side of the uterus, has an uneven texture. Often occurs during pregnancy, after the interruption of which quickly resolves.

Treatment. If you suspect a corpus luteum cyst should conduct surveillance for 2-3 menstrual cycles because it can dissolve. If it didn't resolve, the surgery is needed, since before surgery the presence of a true tumor of the ovary can not be excluded. Paraovarian cyst

Paraovarian cyst - a single-lesion retention between the leaves of the broad ligament of the uterus, which comes from above the ovary appendage. Usually observed in women aged 20-40 years. This is because in reproductive age the appendages reach their highest development and atrophy in older women. Paraovarian cyst in childhood happens very rarely. It has elastic texture, smooth surface, round or oval, filled with a transparent liquid contents. Cysts can be both small and gigantic, often their diameter is 8-10 cm. The wall is thin, transparent, with vascular network.

Clinic. Pain at the bottom of the abdomen and back. For large tumor size, symptoms of compression of adjacent organs. When torsion of the cyst happens the clinical picture of acute abdomen is observed. Surgical treatment - removal of the cyst. Theca lutein cysts. They are also referred to as retention cysts of the ovaries. They may dissolve on their own as a result of

treatment of the underlying disease - Hydatidiform mole or choriocarcinoma. It is appropriate to emphasize that retention cysts occur mainly in younger women. With great care the diagnosis can be set for women in menopause, after excluding a true ovarian tumor. For the purpose of diagnosis ultrasound and laparoscopy can be conducted. Patients diagnosed with ovarian cysts should be on the dispensary. Retention cysts of small size may dissolve under the influence of anti-inflammatory therapy. Therefore permissible to treat them to 4-6 weeks. Please remember that timely diagnosis and treatment retention cysts ultimately is the prevention of ovarian cancer. True ovarian tumor is found in every third or fourth female patient diagnosed with retention cysts. Therefore, it is advisable to timely raise the issue of surgery.

Non-functional ovarian cysts.

Dermoid cyst of the ovary

A bizarre tumor, usually benign, in the ovary that typically contains a diversity of tissues including hair, teeth, bone, thyroid, etc. A dermoid cyst develops from a totipotential germ cell (a primary oocyte) that is retained within the egg sac (ovary). Being totipotential, that cell can give rise to all orders of cells necessary to form mature tissues and often recognizable structures such as hair, bone and sebaceous (oily) material, neural tissue and teeth. Dermoid cysts may occur at any age but the prime age of detection is in the childbearing years. The average age is 30. Up to 15% of women with ovarian teratomas have them in both ovaries. Dermoid cysts can range in size from a centimeter (less than a half inch) up to 45 cm (about 17 inches) in diameter. These cysts can cause the ovary to twist (torsion) and imperil its blood supply. The larger the dermoid cyst, the greater the risk of rupture with spillage of the greasy contents which can create problems with adhesions, pain etc. Although the large majority (about 98%) of these tumors are benign, the remaining fraction (about 2%) becomes cancerous (malignant). Removal of the dermoid cyst is usually the treatment of choice. This can be done by laparotomy (open surgery) or laparoscopy (with a scope). Torsion (twisting) of the ovary by the cyst is an emergency and calls for urgent surgery. Dermoid cysts of the ovary are also called simply dermoids or ovarian teratomas.

Endometrioid tumors. Endometrioid tumors are epithelial ovarian tumors formed by cells that resemble those of the internal lining of the uterus (the endometrium). They may be associated with the aberrant presence of endometrium outside the uterus (endometriosis) and with overgrowth (hyperplasia) or cancer of the endometrium. Benign endometrioid tumors occur infrequently and are predominantly cystic and unilateral. Surgical removal is curative. Borderline endometrioid tumors also are predominantly cystic and unilateral, but they often exhibit internal papillary projections. They represent one-fifth of all endometrioid ovarian neoplasms. Treatment of these tumors is surgical, and prognosis is excellent. On average, both benign and borderline endometrioid tumors are diagnosed in the sixth decade of life. Malignant endometrioid ovarian tumors may be cystic or predominantly solid. These tumors, which make up the second most common malignant ovarian surface epithelial-stromal tumor type, account for approximately 80% of all ovarian endometrioid tumors and 10–25% of all ovarian carcinomas

Neoplastic proliferative ovarian tumors (ovarian cystoma)

Serous ovarian cystoma (cilioepithelial) is a true benign epithelial tumor of the ovary, which is more often unilocular, one-sided, can reach large sizes. It contains serous fluid of yellow straw color. Tumor growth causes an increase in the size of the abdomen, dysfunction of adjacent organs. During bimanual examination a tumor is palpated at the side or behind the uterus, it is painless. Early treatment - removal cystoma. Favorable prognosis.

Papillary ovarian cystoma can be inverting (papillae grow into capsules cystoma) and everting (papillae are located on the outer surface of the capsule, and the tumor often takes the form of cauliflower) and mixed when papillae are placed on the inner and outer surfaces of the

capsule. The latter are often bilateral, occur in women of childbearing age, are accompanied by ascites, inflammation in the pelvis, the growth of papillae on the peritoneum, often degenerate into cancer. Diagnosis is based on the results of bimanual and ultrasound, laparoscopy.

Treatment operative.

Mucinous ovarian cystoma - an epithelial benign tumor that occurs in women of different age groups. Can reach a large size, sometimes multilocular, round or oval. The cavity is filled with a thick cystoma filled with mucous like content.

Clinic. Complaints are: pain, heaviness at the bottom of the abdomen, dysfunction of adjacent organs. Ascites is rare. During bimanual examination in the area of the uterus a formation of elastic consistency with a nodular surface is palpated. For diagnosis ultrasound and laparoscopy are used.

Treatment operative.

Ovarian fibroma - a benign tumor that develops from stroma of the ovary. It has a round or oval, dense, unilateral, can reach the size of the human head, occurs in women aged 40 to 50 years. Can be asymptomatic or be accompanied by ascites, hydrothorax and anemia (Meigs' syndrome).

Treatment operative.

Special investigations in case of proliferative cystomas include:

1. Sonography
2. CT or MRI
3. Serum CA-125 and HE-4
4. Fibrogastroduodenoscopy
5. X-ray of the chest
6. Ultrasound of the inner organs

The list of recommended literature:

1. Наказ МОЗ України № 582 від 15.12.2003 “ Про затвердження клінічних протоколів з акушерської та гінекологічної допомоги»
2. Наказ МОЗ України № 782 від 29.12.2005 « про затвердження клінічних протоколів з акушерської та гінекологічної допомоги»
3. Підруч. для студ. вищих мед. навч. закл. IV рівня акредитації / Н. П. Бондаренко, О. А. Бурка, І. Б. Венцківська [та ін.] ;за ред.: Б. М. Венцківського, Г. К. Степанківської, В. П. Лакатоша. - Київ : Медицина, 2012. - 352 с.
4. підруч. для студ. вищих мед. навч. закл. освіти III-IV рівнів акредитації, лікарів- інтернів та асп. / Г. К. Степанківська, О. Т. Михайленко. - К. : Здоров'я, 2000. - 741 с.
5. підруч. для студ. вищ. мед. (фармац.) навч. закл. I - III рівнів акредитації / О. В. Степанківська, М. О. Щербина. - К. : Медицина, 2010. - 432, [2] с. : іл., мал., табл. - Бібліогр.: с. 432.
6. Textbook of gynaecology including contraception/D.C.Dutta's; edited by Hiralal Konar.-London: new Central book agency (P) Ltd, 2013.-p.655
7. www.medscape.com
8. www.mercksmanuals.com
9. www.slideshare.net
10. www.webmd.com