

VOLUME LXXIV, ISSUE 4, APRIL 2021

ISSN 0043-5147
E-ISSN 2719-342X

Wiadomości Lekarskie



Official journal of the Polish Medical Association

Since 1928



INDEXED IN PUBMED/MEDLINE, SCOPUS, EMBASE, EBSCO, INDEX COPERNICUS,
POLISH MINISTRY OF SCIENCE AND HIGHER EDUCATION, POLISH MEDICAL BIBLIOGRAPHY

Wielka Księga Balneologii, Medycyny Fizykalnej i Uzdrowiskowej

Tom I
Część
ogólna

Tom II
Część
kliniczna

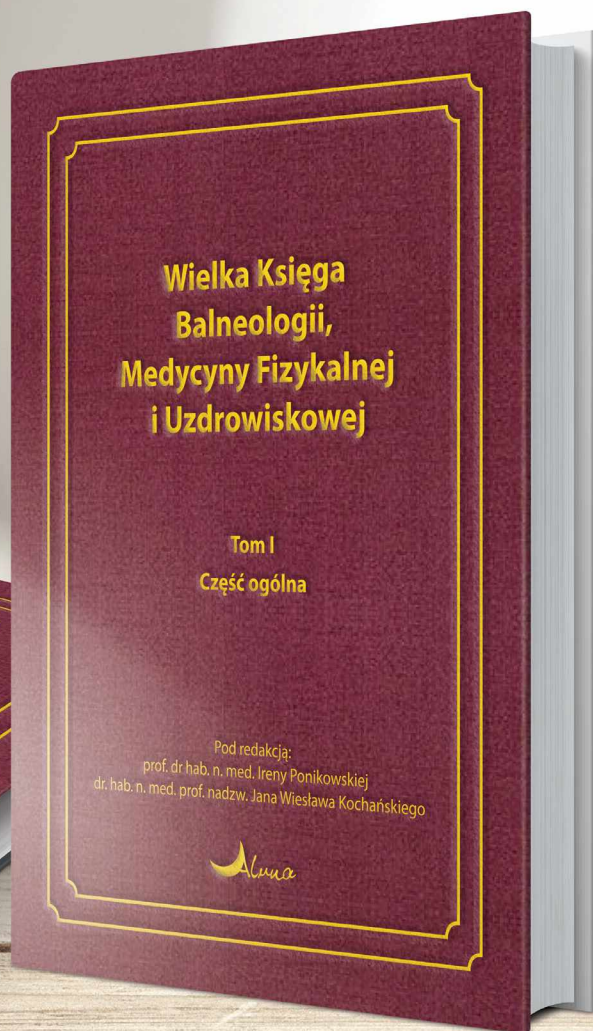

Pod redakcją:
prof. dr hab. n. med. Ireny Ponikowskiej
dr. hab. n. med. prof. nadzw. Jana Wiesława Kocharńskiego

ponad
1300
stron

50
znamienitych
autorów

Złote
tłoczenia,
oprawa
szyta nićmi

11
zagranicznych
autorów



**Szukaj
na**

www.actabalneologica.eu



Wiadomości Lekarskie

Official journal of the Polish Medical Association



Memory of
dr Władysław
Biegański

VOLUME LXXIV, ISSUE 4, APRIL 2021

Since 1928



ALUNA Publishing House

Wiadomości Lekarskie is abstracted and indexed in: PUBMED/MEDLINE, SCOPUS, EMBASE, INDEX COPERNICUS, POLISH MINISTRY OF SCIENCE AND HIGHER EDUCATION, POLISH MEDICAL BIBLIOGRAPHY

Copyright: © ALUNA Publishing House.

Articles published on-line and available in open access are published under Creative Commons Attribution-Non Commercial-No Derivatives 4.0 International (CC BY-NC-ND 4.0) allowing to download articles and share them with others as long as they credit the authors and the publisher, but without permission to change them in any way or use them commercially.

Wiadomości Lekarskie monthly journal

You can order the subscription for the journal from Wydawnictwo Aluna by:

prenumerata@wydawnictwo-aluna.pl
Wydawnictwo Aluna
Z.M. Przesmyckiego 29
05-510 Konstancin-Jeziorna
Poland

Place a written order first.

If you need, ask for an invoice.

Payment should be done to the following account of the Publisher:

account number for Polish customers (PLN):

82 1940 1076 3010 7407 0000 0000

Credit Agricole Bank Polska S. A., SWIFT: AGRIPLR

account number for foreign customers (EURO):

57 2490 0005 0000 4600 7604 3035

Alior Bank S. A.: SWIFT: ALBPPLPW

Subscription of twelve consecutive issues (1-12):

Customers in Poland: 360 PLN/year

Customers from other countries: 320 EURO/year



Wiadomości Lekarskie

Editor in-Chief:

Prof. Władysław Pierzchała

Deputy Editor in-Chief:

Prof. Aleksander Sieroń

Statistical Editor:

Dr Lesia Rudenko

Managing Editor:

Agnieszka Rosa – amarosa@wp.pl

International Editorial Office:

Lesia Rudenko (editor) – l.rudenko@wydawnictwo-aluna.pl

Nina Radchenko (editor's assistant)

– n.radchenko@wydawnictwo-aluna.pl

Polish Medical Association (Polskie Towarzystwo Lekarskie):

Prof. Waldemar Kostewicz – President PTL

Prof. Jerzy Woy-Wojciechowski – Honorary President PTL

Prof. Tadeusz Petelenz

International Editorial Board – in-Chief:

Marek Rudnicki

Chicago, USA

International Editorial Board – Members:

Kris Bankiewicz	San Francisco, USA	George Krol	New York, USA
Christopher Bara	Hannover, Germany	Krzysztof Łabuzek	Katowice, Poland
Krzysztof Bielecki	Warsaw, Poland	Henryk Majchrzak	Katowice, Poland
Zana Bumbuliene	Vilnius, Lithuania	Ewa Małeczka-Tendera	Katowice, Poland
Ryszarda Chazan	Warsaw, Poland	Stella Nowicki	Memphis, USA
Stanislav Czudek	Ostrava, Czech Republic	Alfred Patyk	Gottingen, Germany
Jacek Dubiel	Cracow, Poland	Palmira Petrova	Yakutsk, Russia
Zbigniew Gasior	Katowice, Poland	Krystyna Pierzchała	Katowice, Poland
Andrzej Gładysz	Wroclaw, Poland	Tadeusz Płusa	Warsaw, Poland
Nataliya Gutorova	Kharkiv, Ukraine	Waldemar Priebe	Houston, USA
Marek Hartleb	Katowice, Poland	Maria Siemionow	Chicago, USA
Roman Jaeschke	Hamilton, Canada	Vladyslav Smiiianov	Sumy, Ukraine
Andrzej Jakubowiak	Chicago, USA	Tomasz Szczepański	Katowice, Poland
Oleksandr Katrushov	Poltava, Ukraine	Andrzej Witek	Katowice, Poland
Peter Konturek	Saalfeld, Germany	Zbigniew Wszolek	Jacksonville, USA
Jerzy Korewicki	Warsaw, Poland	Vyacheslav Zhdan	Poltava, Ukraine
Jan Kotarski	Lublin, Poland	Jan Zejda	Katowice, Poland

Distribution and Subscriptions:

Bartosz Guterman prenumerata@wydawnictwo-aluna.pl

Graphic design / production:

Grzegorz Sztank

www.red-studio.eu

Publisher:

ALUNA Publishing House

ul. Przesmyckiego 29,

05-510 Konstancin – Jeziorna

www.wydawnictwo-aluna.pl

www.wiadomoscilekarskie.pl

www.wiadlek.pl

FOR AUTHORS

- The monthly "Wiadomości Lekarskie" Journal is the official journal of the Polish Medical Association. Original studies, review papers as well as case reports are published.
- The publication of the manuscript in "Wiadomości Lekarskie" is paid. The cost of publishing the manuscript is PLN 1,000 plus 23% VAT (for foreign authors 250 Euro). If the first author of the manuscript is a member of the Editorial Board or a team of journal reviewers, we do not charge a fee for printing the manuscript, and if she or he is the next co-author – the fee is PLN 500 plus 23% VAT. The publisher issues invoices. The fee should be paid after receiving positive reviews, and before publishing the manuscript. Membership of the Polish Medical Association with documented paid membership fees for the last 3 years is also the exempt from publication fee.
- Only papers in English are accepted for publication. The editors can help in finding the right person for translation or proofreading.
- Papers should be sent to the editor via the editorial panel (Editorial System), available on the journal's website at <https://www.wiadlek.pl>. In order to submit an article, free registration in the system is necessary. After registration, the author should follow the instructions on the computer screen.
- All editorial work is under control and using the editorial panel. This applies in particular to sending manuscripts, correspondence between the editor and author and the review process. In special cases, the editor may agree to contact outside the panel, especially in case of technical problems.
- Acceptable formats for individual elements of the article are as follows:
 - Content of the article – doc, docx, rtf, odt.
 - Tables – doc, docx, rtf, odt
 - Figures – JPG, GIF, TIF, PNG with a resolution of at least 300 dpi
 - Captions for figures and tables.
 These elements are sent to the editor separately using the editorial panel. References and article metadata such as titles, keywords, abstracts etc. are supplemented by the author manually in the editorial panel in appropriate places.
- The volume of original papers – including figures and references – must not exceed 21,600 characters (12 pages of typescript), and review papers – up to 28,800 characters (16 pages).
- The original manuscript should have the following structure: Introduction, Aims, Material and methods, Results, Discussion and Conclusions which cannot be a summary of the manuscript.
- When using abbreviations, it is necessary to provide the full wording at the first time they are used.
- In experimental manuscripts in which studies on humans or animals have been carried out, as well as in clinical studies, information about obtaining the consent of the Ethics Committee should be included.
- The Editorial Board follow the principles contained in the Helsinki Declaration as well as in the Interdisciplinary Principles and Guidelines for the Use of Animals in Research, Testing and Education, published by the New York Academy of Sciences Ad Hoc Committee on Animal Research. All papers relating to animals or humans must comply with ethical principles set out by the Ethics Committee.
- The abstract should contain 150-250 words. Abstracts of original, both clinical and experimental, papers should have the following structure: Aims, Material and methods, Results, Conclusions. Do not use abbreviations in the title or the abstract. The abstract is pasted or rewritten by the authors into the appropriate field in the application form in the editorial panel.
- Keywords (3-5) should be given according to MeSH (Medical Subject Headings Index Medicus catalogs – <http://www.nlm.nih.gov/mesh/MBrowser.html>). Keywords cannot be a repetition of the title of the manuscript.
- Illustrative material may be black and white or color photographs, clearly contrasting or drawings carefully made on a white background. With the exception of selected issues, the Journal is printed in shades of gray (black and white illustrations).
- The content of the figures, if present (e.g. on the charts), should also be in English
- Links to all tables and figures (round brackets) as well as references (square brackets) the author must place in the text of the article.
- Only references to which the author refers in the text should be included in the list of references ordered by citation. There should be no more than 30 items in original papers and no more than 40 items in review papers. Each item should contain: last names of all authors, first letters of first names, the title of the manuscript, the abbreviation of the journal title (according to Index Medicus), year, number, start and end page. For book items, please provide: author's (authors') last name, first letter of the first name, chapter title, book title, publisher, place and year of publication. It is allowed to cite websites with the URL and date of use of the article, and if possible the last names of the authors. Each literature item should have a reference in the text of the manuscript placed in square brackets, e.g. [1], [3-6]. Items should be organized as presented in Annex 1 to these Regulations.
- When submitting the article to the editor, the authors enclose a statement that the work was not published or submitted for publication in another journal and that they take full responsibility for its content, and the information that may indicate a conflict of interest, such as:
 - financial dependencies (employment, paid expertise, consulting, ownership of shares, fees),
 - personal dependencies,
 - academic and other competition that may affect the substantive side of the work,
 - sponsorship of all or part of the research at the stage of design, collection, analysis and interpretation of data, or report writing.
- The authors in the editorial panel define their contribution to the formation of scientific work according to the following key:
 - Work concept and design
 - Data collection and analysis
 - Responsibility for statistical analysis
 - Writing the article
 - Critical review
 - Final approval of the article.
- In the editorial panel along with the affiliation, the author also gives her or his ORCID number.
- The Journal is reviewed in double, blind review mode. The submitted papers are evaluated by two independent reviewers and then qualified for publishing by the Editor-in-Chief. Reviews are anonymous. The authors receive critical reviews with a request to correct the manuscript or with a decision not to qualify it for publishing. The procedure for reviewing articles is in line with the recommendations of the Ministry of Science and Higher Education contained in the paper "Good practices in review procedures in science" (Warsaw 2011). Detailed rules for dealing with improper publishing practices are in line with COPE guidelines. The publishing review rules are in the Review Rules section.
- Each manuscript is subject to verification in the anti-plagiarism system.
- Manuscripts are sent for the author's approval. The author's corrections should be sent within the time limit indicated in the system. No response within the given deadline is tantamount to the author's acceptance of the submitted material. In special cases, it is possible to set dates individually.
- Acceptance of the manuscript for publishing means the transfer of copyright to the Aluna Publishing House (Aluna Anna Łuczynska, NIP 5251624918).
- Articles published on-line and available in open access are published under Creative Commons Attribution-Non Commercial-No Derivatives 4.0 International (CC BY-NC-ND 4.0) allowing to download articles and share them with others as long as they credit the authors and the publisher, but without permission to change them in any way or use them commercially.
- The authors receive a free PDF of the issue in which their manuscript is enclosed, and on request – a printed copy. The printed copy is sent to the address indicated by the authors as the correspondence address.
- Manuscripts not concordant with the above instructions will be returned to be corrected.
- The editors do not return papers which have not been commissioned.
- The editors take no responsibility for the contents of the advertisements.

Igor S. Brodetskyi, Vladislav A. Malanchuk, Bogdan V. Sorokin, Mykhailo S. Myroshnychenko, Yuliya I. Beketova, Olena O. Dyadyk, Nataliia V. Kapustnyk, Mykhailo S. Krotevych, Sergey B. Brodetskyi TUMORS AND TUMOR-LIKE LESIONS OF THE SALIVARY GLANDS: MORPHOLOGICAL CHARACTERISTICS OF THE SURGICAL MATERIAL	929
Aidyn G. Salmanov, Alla D. Vitiuk, Oleg M. Ishchak, Kateryna S. Insarova, Serhii L. Chyrva, Marina L. Kuzomenska, Oleg V. Golianovsky SURGICAL SITE INFECTION AFTER CESAREAN SECTION IN UKRAINE: RESULTS A MULTICENTER STUDY	934
Tamara H. Romanenko, Anastasiia D. Haiduk, Svetlana V. Turbanist A STATISTICAL ANALYSIS OF WOMEN'S REPRODUCTIVE HEALTH CHARACTERISTICS AFTER INEFFECTIVE REATTEMPTS OF USING ART	940
Olesya M. Horlenko, Vasyl I. Rusyn, Viktoriya M. Studenyak, Nataliia V. Sochka, Fedir V. Horlenko, Ivan I. Kopolovets, Lyubomyra B. Prylypko INTEGRATIVE MORPHOMETRIC CHARACTERISTIC OF ENDOTHELIAL DYSFUNCTION IN THE CASES OF CHILDREN WITH ESSENTIAL ARTERIAL HYPERTENSION	948
Volodymyr B. Grytsuliak, Mariana M. Vasylechko, Oksana I., Kocherzhat, Oksana I. Hotiur HEMODYNAMIC AND CYTOLOGIC CHANGES IN PROSTATE GLAND CAUSED BY CHRONIC HEPATITIS	954
Vitalina V. Ivachevska THE EFFECT OF COMPREHENSIVE TREATMENT OF PATIENTS WITH NON-ALCOHOLIC FATTY LIVER DISEASE IN COMBINATION WITH PREDIABETES ON THE LIPID PROFILE	957
Stepan O. Karabinyosh, Galina M. Koval EPIDEMIOLOGICAL FEATURES OF SARS2 COVID-19 OUTBREAK DURING 2020 AMONG RT-PCR CONFIRMED CASES IN ZAKARPATTYA	961
Oksana Yu. Marchenko, Nadiia M. Rudenko, Volodymyr V. Vitomskyi, Bohdana M. Habida REVISITING THE VALUE OF HAEMATOLOGICAL AND BIOCHEMICAL MARKERS AND THE RATIOS IN PATIENTS WITH CORONARY ARTERY DISEASE	966
Viktoriiia V. Rodionova, Olha O. Boiko AGGRAVATING EFFECT OF ARTERIAL HYPERTENSION ON THE COURSE OF CHRONIC OBSTRUCTIVE PULMONARY DISEASE IN PATIENTS WITH COMORBID PATHOLOGY	973
Antonina V. Varvanyets, Ivan V. Chohey, Ksenia I. Chubirko, Artur V. Kurakh, Vasyl M. Voronych, Yuriy P. Skrypynets EFFECT OF PROLONGED TREATMENT WITH BIOLOGICAL THERAPY IN PATIENTS WITH ULCERATIVE COLITIS WITH CONCOMITANT JOINT DAMAGE	977
Yelyzaveta S. Sirchak, Vasiliy Ye. Barani, Olena M. Odoshevska, Oksana I. Petrichko PECULIARITIES OF DETERMINING THE GASTRIC ACID SECRETION AND DIABETIC AUTONOMIC NEUROPATHY IN PATIENTS WITH CHRONIC PANCREATITIS AND TYPE 2 DIABETES	981
Snizhana V. Feysa, Svitlana O. Rudakova INFLUENCE OF COMPLEX TREATMENT ON BIOCHEMICAL BLOOD PARAMETERS OF PATIENTS WITH NON-ALCOHOLIC FATTY LIVER DISEASE AND CONCOMITANT PRE-DIABETES	986
Anatoliy M. Potapchuk, Yevhen L. Onipko, Vasyl M. Almashi, Ninel V. Dedukh, Oleksandr Ye. Kostenko EXPERIMENTAL STUDY OF BONE REBUILDING IN THE PERIIMPLANTATION AREA UNDER IMMEDIATE LOADING ON DENTAL IMPLANTS	992
Taras I. Griadil, Ivan V. Chohey, Ksenia I. Chubirko, Mykhaylo M. Hechko, Wael Rumaneh ASSESSMENT OF CARDIOVASCULAR RISK IN PATIENTS WITH TYPE 2 DIABETES MELLITUS AND ASSOCIATED OBESITY AND WAYS OF ITS CORRECTION	998
REVIEW ARTICLES	
Maryana M. Rosul, Miroslava M. Bletska, Nataliia V. Ivano, Marina O. Korabelschykova LOOP DIURETICS IN HEART FAILURE: EVIDENCE-BASED CHOICE	1003
Tetyana V. Koval, Ivan V. Chohey, Mykhaylo M. Hechko, Artur V. Kurakh NON-ALCOHOLIC FATTY LIVER DISEASE IN THE CONTEXT OF ALTERED GUT MICROBIOTA	1007
Yana Y. Hnepa, Ivan V. Chohey, Ksenia I. Chubirko, Andriy M. Bratasyuk SHORT- AND LONG-TERM EFFECTS OF NSAIDS ON THE GASTROINTESTINAL MUCOSA: COMPLEX ANALYSIS OF BENEFITS AND COMPLICATIONS PREVENTION	1011
Yelyzaveta I. Rubtsova, Svitlana V. Oberemko, Maryana M. Rosul DYNAMICS OF DIPHTHERIA INCIDENCE IN THE TRANS-CARPATHIAN REGION OF UKRAINE IN THE VACCINATION ERA	1019
CASE STUDIES	
Ivan P. Katerenchuk, Lydia A. Tkachenko, Tatiana I. Yarmola, Victoria V. Talash MICROSCOPIC POLYANGIITIS – A VIEW OF THE PROBLEM THROUGH THE LENS OF A NEPHROLOGIST	1024
Hanna V. Palahuta, Olena Y. Fartushna, Olha G. Selina, Yevhen M. Fartushnyi, Tetiana V. Koval GLYCOGEN STORAGE DISEASE TYPE II: A NARRATIVE LITERATURE REVIEW AND A CASE REPORT OF LATE-ONSET POMPE DISEASE IN A YOUNG WHITE CHILD	1032
Denis M. Chernohorskyi, Yuriy V. Chepurnyi, Oleksandr A. Kanyura, Andriy V. Kopchak TOTAL MANDIBULAR DEFECT RECONSTRUCTION BY TOTAL TITANIUM PATIENT-SPECIFIC IMPLANT: CLINICAL EFFICACY AND LONG TERM FOLLOW UP. CLINICAL CASE	1037
Andrii A. Sherehii, Vasil V. Stoika, Vasil V. Lytvak A RARE COMPLICATION OF CALCANEAL FRACTURE – CALCANEAL NON-UNION. CASE REPORT	1042
Hanna V. Palahuta, Olena Y. Fartushna, Stanislav K. Yevtushenko, Yana Y. Hnepa ACUTE TRANSVERSE MYELITIS AS A NEUROLOGICAL COMPLICATION OF COVID-19: A CASE REPORT	1045

CASE STUDY

ACUTE TRANSVERSE MYELITIS AS A NEUROLOGICAL COMPLICATION OF COVID-19: A CASE REPORT

DOI: 10.36740/WLek202104144

Hanna V. Palahuta¹, Olena Y. Fartushna², Stanislav K. Yevtushenko³, Yana Y. Hnepa⁴¹STATE UNIVERSITY "UZHHOROD NATIONAL UNIVERSITY", REGIONAL CLINICAL CENTER OF NEUROSURGERY AND NEUROLOGY, UZHHOROD, UKRAINE²UKRAINIAN MILITARY MEDICAL ACADEMY, KYIV, UKRAINE³KHARKIV MEDICAL ACADEMY OF POSTGRADUATE EDUCATION, KHARKIV, UKRAINE⁴STATE UNIVERSITY "UZHHOROD NATIONAL UNIVERSITY", UZHHOROD, UKRAINE

ABSTRACT

We aim to report a COVID-19-related case of acute myelitis that has not been associated with any other viral infections. A 23-year-old student was admitted to the hospital within a month from the time of loss of smell and taste with features of acute-onset non-compressive myelitis with paresthesia on both sides from the Th9 level. Complex neurological, clinical, laboratory, and neuroimaging examination was performed within 24 hours of admission. MRI of the spine showed a segment of increased T2 signal in the center of the spinal cord at Th11-Th12. Elevated protein level and lymphocytic pleocytosis were detected in the cerebrospinal fluid. A serologic blood test for SARS-CoV-2 showed recent infection. PCR for other viral infections was negative. The patient was treated with injectable steroids and showed full recovery. Specific neurological features of acute myelitis associated with COVID-19 were reported, described, and analyzed. Patient was treated and recovered.

KEY WORDS: COVID-19, SARS-CoV-2, myelitis, complication, infectious diseases, spinal cord

Wiad Lek. 2021;74(4):1045-1049

INTRODUCTION

More and more data and evidence that confirm damage to the central nervous system (CNS) in the context of acute infection and post-infectious complications of COVID-19 have been reported [1-3]. It is essential to recognize the neurological manifestations and complications of COVID-19, some of which can progress rapidly and require urgent intervention.

COVID-19 DEFINITIONS

COVID-19 is a highly contagious respiratory disease in humans, caused by a new coronavirus called SARS-CoV-2. It was first identified in Wuhan city of China, in December 2019. [4] On February 11, 2020, the World Health Organization (WHO) announced an official name for the disease caused by the novel coronavirus – COVID-19. In this abbreviation, 'CO' stands for 'corona,' 'VI' for 'virus,' and 'D' for disease. Formerly, this disease was referred to as "2019 novel coronavirus" or "2019-nCoV." [5]

COVID-19 PANDEMIC HEALTH IMPACT

On March, 11, 2020, the WHO declared the ongoing outbreak of the respiratory disease, named Coronavirus disease 2019 (COVID-19), to be a global pandemic, pointing to over 3 million cases and 207,973 deaths in 213 countries and territories. [6] The morbidity and mortality of the global community due to this disease is increasing

dramatically. As of January 11, 2021, authorities in 218 countries and territories around the world have reported over 90.8 million COVID-19 cases and 1.94 million deaths since China reported its first cases to the WHO in December, 2020. [7]

COVID-19 ECONOMIC IMPACT

The COVID-19 infection has not only become a public health crisis but has also affected the global economy. The pandemic caused the largest global recession in history, with more than a third of the global population at the time being placed on lockdown. [8]

The quarantines and lockdowns that are needed to fight the COVID-19's spread are freezing the economies with unprecedented force and speed. Significant economic impact has already occurred across the globe due to reduced productivity, premature deaths, business closures, workplace absenteeism, trade disruption, decimation of the tourism industry, and reduction in productivity. It has created a negative supply shock, with manufacturing productive activity slowing down due to global supply chain disruptions and closures of factories. [9] Worldwide, 660 million workers lost their jobs, 38 million have filed for unemployment insurance during the pandemic. A record 3.28 million Americans applied for unemployment benefits, the highest number ever recorded. [10]

The COVID-19 pandemic has triggered the deepest economic recession in nearly a century, threatening health, pushing the hospital system to its capacity, disrupting economic activity, and

hurting well-being and jobs. The pandemic has created a demand shock, a supply shock, and a financial shock all at once with the global labour income losses over US\$3.5 trillion. [11, 12]

COVID-19 NEUROLOGICAL MANIFESTATIONS

As a second wave of COVID-19 occurred, it has become clear that SARS-CoV-2 may affect not only the respiratory system, but multiple parts of the body, including the nervous system. Reported neurological manifestations of COVID-19 include, but are not limited to: headache, impaired consciousness, stroke, seizure, meningitis, encephalitis, necrotizing encephalopathy, Guillain-Barré syndrome, and acute demyelinating encephalomyelitis [13-16].

Neurological complications in COVID-19 infected patients have not been widely reported. Here we report the case of a patient who presented with acute-onset non-compressive myelitis and was found to be infected with COVID-19.

The purpose of this study is to report, describe, and analyze a COVID-19-related case of acute myelitis in a young adult that has not been associated with any other viral infection. Comprehensive clinical and neuroimaging analysis follows.

CASE REPORT

A 23-year-old male student was admitted to the hospital with progressive bilateral lower extremity weakness, difficulty urinating, and constipation. A month earlier, he had a loss of taste (dysgeusia) and smell (anosmia). The symptoms disappeared on their own after 14 days. The patient was not examined for SARS-CoV-2, and therefore did not receive any treatment for COVID-19. On the 20th day from the time of loss of smell and taste, he developed weakness in his legs, and began to experience difficulty urinating. Over the next 7 days, sub-febrile conditions and pain in the lumbar and thoracic spine were noted. This was accompanied by progressive weakness of the lower extremities, difficulty walking, and constipation. He turned to the Regional Clinical Center of Neurosurgery and Neurology, Uzhorod city, Ukraine.

MEDICAL HISTORY

Patient does not smoke, does not take any recreational drugs or medications. No alcohol intake. No incidents of head or spinal injury. Denies chronic diseases and any surgical interventions. There is no family history of any neurological disorder.

VITALS UPON ADMISSION

Upon admission to the department, the patient showed a normal general condition. The respiratory rate was 16 breaths per minute, oxygen saturation was 100%, and blood pressure was 120/75 mm Hg. A heart rate of 70 beats per minute, temperature 36.7 °C.

CLINICAL EXAMINATION

Clinical neurological examination revealed decreased muscle tone, hyporeflexia, and decreased proprioception of

the lower extremities. Muscle strength in the legs was: 2.5 points on the left and 3.0 points on the right. The patient also had paresthesia on both sides from the Th9 level. No pathological reflexes were found. The patient was hospitalized for further examination and treatment.

LABORATORY AND INSTRUMENTAL EXAMINATION RESULTS

Preliminary general blood tests and X-Ray of the chest did not reveal any pathological changes. MRI of the spine showed a segment of increased T2 signal in the center of the spinal cord at the Th11-Th12 level (Figure 1). MRI of the brain and orbits did not reveal any signs of inflammatory changes to suggest a relationship with the changes in MRI seen in the spine.

Cerebrospinal fluid (CSF) showed increased protein level (1.02 g/L) and lymphocytic pleocytosis (130 cells). PCR for viral infections was negative for toxoplasma, herpes simplex viruses (types 1 and 2), and cytomegalovirus. SARS-CoV-2 (PCR) cerebrospinal fluid and oligoclonal bands were negative. A serologic blood test for SARS-CoV-2 showed recent infection (presence of SARS-CoV-2 / IgG as determined by internal immunofluorescence antibody testing). Antibodies to anti-myelin-associated glycoprotein IgM and IgG to optic neuromyelitis were negative in serum.

DIAGNOSIS

Based on initial diagnostic assessment (patient history, physical exam, evaluation of the patient's chief complaint and symptoms, differential diagnosis, and diagnostic tests and treatment results) patient was diagnosed with acute transverse myelitis at the level of Th11-Th12 (COVID-19 associated), with lower moderate paraparesis, sensitive disorders, pelvic floor dysfunction (urinary retention and constipation), and gait disorders.

DIFFERENTIAL DIAGNOSIS

The presence of transverse sensorimotor myelopathy with segmental neurological deficit necessitated a detailed neurological examination. The patient did not report significant head or spinal trauma. The progressive appearance of neurological symptoms and young age made the diagnosis of cerebrovascular accident less likely. The patient's preliminary blood count and clinical examination did not indicate a serious systemic infection. The patient's medical history does not provide further indication of any cause for the disease. Neuroimaging, including brain imaging, showed no signs of a demyelinating disease such as multiple sclerosis or Devik's optic myelitis (taking into account, among other things, the absence of antibodies to aquaporin-4). Due to the indication of recent viral infection (COVID-19) in the form of its typical manifestations, and the presence of SARS-CoV-2 IgG in the blood, we assumed the possibility of developing post-viral acute partial transverse myelitis (ARTM).

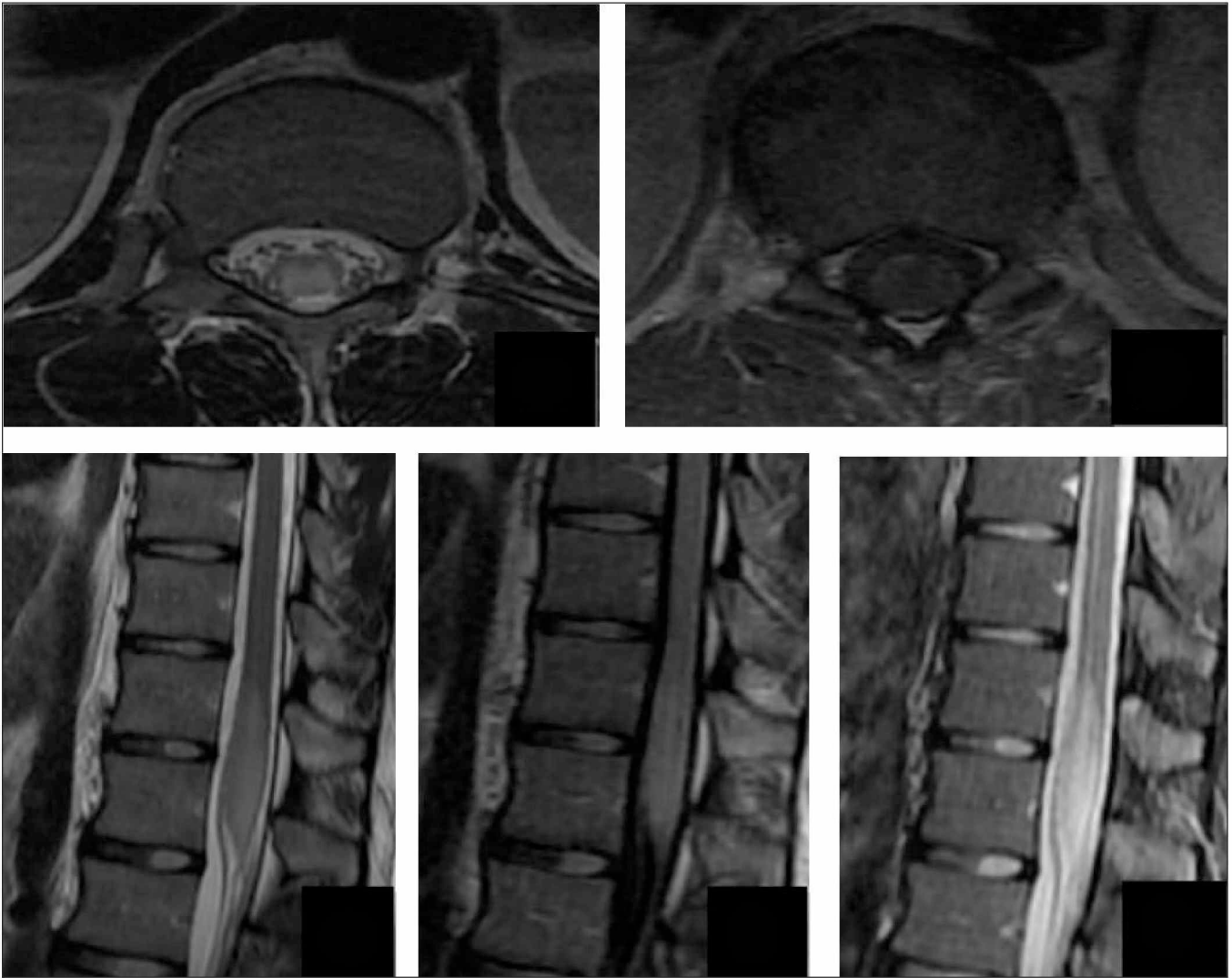


Fig 1. MRI of the patient's thoracic spine, sagittal projection (T2 FLAIR, STIR, and T2W sequences) and coronary projection (T2W).

TREATMENT

The patient was treated with methylprednisolone intravenous injections of 1 gram per day for 5 days. After that methylprednisolone was given in tablet form that was titrated, starting from 32 mg/day. No antiviral medicine, antibiotics, or immunomodulatory medicine, other than methylprednisolone, was prescribed. Neurological symptoms improved with corticosteroids treatment. The patient fully recovered motor strength in the lower extremities. Paresthesias disappeared completely and the pelvic disorders regressed. The patient was discharged home on the 8th day of hospitalization. Repeated MRI of the spinal cord was performed on day 30 and showed complete disappearance of intramedullary changes observed earlier at the Th 11-Th 12 level.

The incidence of acute myelitis associated with COVID-19 infection is not widely reported. Several reports of similar cases have been published in the literature, in which COVID-19 is associated with the onset of acute myelitis as a neurological complication. [17-21]

According to the literature, the most common symptoms associated with COVID-19 infection are fever or chills, cough, shortness of breath or difficulty breathing, fatigue, muscle or body aches, loss of taste or smell, headache, sore throat, congestion or runny nose, nausea or vomiting, and diarrhea. [2, 24]. The symptoms may appear 2-14 days after exposure to the virus. [2, 24] It is believed that anosmia and dysgeusia are due to the fact that the SARS-CoV-2 virus can directly enter the nervous system via the olfactory tract or bloodstream at a pro-inflammatory stage of the disease. [1-3]

Acute necrotizing encephalopathy has been reported following the onset of the severe acute respiratory syndrome (SARS-CoV-2) and detection of viral DNA in a nasopharyngeal swab sample. [25] In this case, the analysis of cerebrospinal fluid was not performed for technical reasons, and the diagnosis was confirmed by neuroimaging.

Viral encephalitis has been reported as another manifestation of CNS damage in the context of acute COVID-19 infection. [26] In this case, SARS-CoV-2 RNA was found

in the cerebrospinal fluid, and the brain MRI results conformed to meningitis.

Cases of Guillain-Barré syndrome associated with COVID-19 [30], as well as polyneuropathy and Miller Fisher syndrome [32] have been reported. In the indicated cases, a nasal swab for SARS-CoV-2 PCR was positive. SARS-CoV-2 was not detected in the cerebrospinal fluid.

It was suggested a hypothesis that SARS-CoV-2 can cause neural damage through hypoxic and immune-mediated pathways. [2] SARS-CoV-2 binds to ACE2 receptors, which have been described in the heart, lungs, central nervous system, and skeletal muscle. [1,2] Viral replication and increased activation of the ACE2 receptor in the CNS can induce a systemic inflammatory response leading to increased permeability of the blood-brain barrier and immune-mediated CNS inflammation. IL-6, a pro-inflammatory cytokine, is thought to mediate this response. [27-29] Increased levels of IL-6 can lead to increased production of acute-phase proteins such as CRP and fibrinogen. [27]

It has recently been highlighted that IL-6 is a potential predictor of severity, progression, and mortality from COVID-19 infection. [27-29] Elevated ferritin levels have also been associated with more severe infection and worse outcomes. Unfortunately, the determination of the level of IL-6 and ferritin in our patient was not performed.

CONCLUSIONS

Health care providers should be aware that patients with COVID-19 can present with myelitis in the acute setting and during hospitalization. We presented a case of acute partial transverse myelitis in the context of a recent COVID-19 infection. We did not find SARS-CoV-2 RNA in the cerebrospinal fluid and suggested that this case was probably associated with an immune-mediated inflammatory process, and not the direct effect of SARS-CoV-2 on the central.

REFERENCES

- Mao L., Jin H., Wang M. et al. Neurologic Manifestations of Hospitalized Patients With Coronavirus Disease 2019 in Wuhan, China. *JAMA Neurol.* 2020;77(6):683-690. doi: 10.1001/jamaneurol.2020.1127.
- Wu Y., Xu X., Chen Z. et al. Nervous system involvement after infection with COVID-19 and other coronaviruses. *Brain Behav Immun.* 2020;87:18-22. doi:10.1016/j.bbi.2020.03.031.
- Asadi-Pooya A.A., Simani L. Central nervous system manifestations of COVID-19: A systematic review. *J Neurol Sci.* 2020;413:116832. doi:10.1016/j.jns.2020.116832.
- Mackenzie J.S., Smith D.W. COVID-19: a novel zoonotic disease caused by a coronavirus from China: what we know and what we don't. *Microbiol Aust.* 2020;MA20013. doi:10.1071/MA20013.
- Eurosurveillance editorial team. Updated rapid risk assessment from ECDC on the novel coronavirus disease 2019 (COVID-19) pandemic: increased transmission in the EU/EEA and the UK. *Euro Surveill.* 2020;25(10):2003121. doi:10.2807/1560-7917.ES.2020.25.10.2003121.
- World Health Organization. WHO Director-General's opening remarks at the media briefing on COVID-19—11 March 2020. www.who.int/dg/speeches/detail/who-director-general-s-opening-remarks-at-the-media-briefing-on-covid-19---11-march-2020
- Johns Hopkins Coronavirus Resource Center. <https://coronavirus.jhu.edu/map.html>.
- Yousfi N., Bragazzi N.L., Briki W. et al. The COVID-19 pandemic: how to maintain a healthy immune system during the lockdown – a multidisciplinary approach with special focus on athletes. *Biol Sport.* 2020;37(3):211-216. doi:10.5114/biolSport.2020.95125.
- Pak A., Adegboye O.A., Adekunle A.I. et al. Economic Consequences of the COVID-19 Outbreak: the Need for Epidemic Preparedness. *Front Public Health.* 2020;8:241. doi:10.3389/fpubh.2020.00241.
- Rothwell J. The effects of COVID-19 on international labor markets: An update. *Middle Class Memos.* 2020. <https://www.brookings.edu/research/the-effects-of-covid-19-on-international-labor-markets-anupdate>.
- ILO Monitor: COVID-19 and the world of work. Sixth edition. https://www.ilo.org/wcmsp5/groups/public/---dgreports/---dcomm/documents/briefingnote/wcms_755910.pdf
- ILO Annual Meetings of the World Bank and the IMF Government economic and social policy interventions vital to tackle workplace closures and labour income losses. https://www.ilo.org/global/about-the-ilo/newsroom/statements-and-speeches/WCMS_758304/lang--en/index.htm
- Koralnik I.J., Tyler, K.L. COVID-19: A Global Threat to the Nervous System. *Ann Neurol.* 2020; 88: 1-11. doi:10.1002/ana.25807.
- Mao L., Jin H., Wang M. et al. Neurologic Manifestations of Hospitalized Patients With Coronavirus Disease 2019 in Wuhan, China. *JAMA Neurol.* 2020;77(6):683-690. doi:10.1001/jamaneurol.2020.1127.
- Moriguchi T., Harii N., Goto J. et al. A first case of meningitis/encephalitis associated with SARS-Coronavirus-2. *Int J Infect Dis.* 2020;94:55-58. doi:10.1016/j.ijid.2020.03.062.
- Poyiadji N., Shahin G., Noujaim D. et al. COVID-19-associated Acute Hemorrhagic Necrotizing Encephalopathy: Imaging Features. *Radiology.* 2020;296(2):E119-E120. doi: 10.1148/radiol.2020201187.
- Zhao K., Huang J., Dai D. et al. Acute myelitis after SARS-CoV-2 infection: a case report. *medRxiv* 2020. doi:10.1101/2020.03.16.20035105.
- Sarma D., Bilello L.A. A Case Report of Acute Transverse Myelitis Following Novel Coronavirus Infection. *Clin Pract Cases Emerg Med.* 2020;4(3):321-323. doi:10.5811/cpcem.2020.5.47937.
- Munz M., Wessendorf S., Koretsis G. et al. Acute transverse myelitis after COVID-19 pneumonia. *J Neurol.* 2020;267(8):2196-2197. doi:10.1007/s00415-020-09934-w.
- Chow C.C.N., Magnussen J., Ip J., Su Y. Acute transverse myelitis in COVID-19 infection. *BMJ Case Rep.* 2020;13(8):e236720. doi:10.1136/bcr-2020-236720.
- Valiuddin H., Skwirsk B., Paz-Arabo P. Acute transverse myelitis associated with SARS-CoV-2: A Case-Report. *Brain Behav Immun Health.* 2020;5:100091. doi:10.1016/j.bbih.2020.100091.
- Palahuta H.V., Yevtushenko S.K. A case of acute myelitis as a neurological complication of COVID-19. *International Neurological Journal.* 2020;7(16):32-35. (in Ukrainian). DOI: <https://doi.org/10.22141/2224-0713.16.7.2020.218244>.
- Fartushna O.Y., Palahuta H.V., Yevtushenko S.K. Neurological and neuropsychiatric manifestations and complications of SARS-CoV-2 infection: a narrative review and a case presentation in a previously healthy young white adult. *International Neurological Journal.* 2021;1(17):12-16.
- Phua J., Weng L., Ling L. et al. Asian Critical Care Clinical Trials Group. Intensive care management of coronavirus disease 2019 (COVID-19): challenges and recommendations. *Lancet Respir Med.* 2020;8(5):506-517. doi: 10.1016/S2213-2600(20)30161-2.

25. Poyiadji N., Shahin G., Noujaim D. et al. COVID-19-associated Acute Hemorrhagic Necrotizing Encephalopathy: Imaging Features. *Radiology*. 2020;296(2):E119-E120. doi: 10.1148/radiol.2020201187.
26. Moriguchi T., Harii N., Goto J. et al. A first case of meningitis/encephalitis associated with SARS-Coronavirus-2. *Int J Infect Dis*. 2020;94:55-58. doi: 10.1016/j.ijid.2020.03.062.
27. Zhu Z., Cai T., Fan L. et al. Clinical value of immune-inflammatory parameters to assess the severity of coronavirus disease 2019. *Int J Infect Dis*. 2020;95:332-339. doi: 10.1016/j.ijid.2020.04.041.
28. Zhou F., Yu T., Du R. et al. Clinical course and risk factors for mortality of adult inpatients with COVID-19 in Wuhan, China: a retrospective cohort study. *Lancet*. 2020;395(10229):1054-1062. doi: 10.1016/S0140-6736(20)30566-3.
29. Ruan Q., Yang K., Wang W. et al. Clinical predictors of mortality due to COVID-19 based on an analysis of data of 150 patients from Wuhan, China. *Intensive Care Med*. 2020;46(5):846-848. doi: 10.1007/s00134-020-05991-x.
30. Zhao H., Shen D., Zhou H. et al. Guillain-Barré syndrome associated with SARS-CoV-2 infection: causality or coincidence? *Lancet Neurol*. 2020;19(5):383-384. doi: 10.1016/S1474-4422(20)30109-5.
31. Gutiérrez-Ortiz C., Méndez-Guerrero A., Rodrigo-Rey S. et al. Miller Fisher syndrome and polyneuritis cranialis in COVID-19. *Neurology*. 2020;95(5):e601-e605. doi: 10.1212/WNL.0000000000009619.

ORCID and contributionship:

Hanna V. Palahuta: 0000-0001-7348-4390 ^{A,B,D,E,F}

Olena Y. Fartushna: 0000-0002-4641-0836 ^{A,B,D,E,F}

Stanislav K. Yevtushenko: 0000-0003-2528-716X ^{A,E,F}

Yana Y. Hnepa :0000-0002-0276-1466 ^{E,F}

Conflict of interest:

The Authors declare no conflict of interest.

CORRESPONDING AUTHOR**Olena Y. Fartushna**

Ukrainian Military Medical Academy
24 Melnikova St., 04050 Kyiv, Ukraine
tel: +380935488978
e-mail: olena.y.fartushna@gmail.com

Received: 12.12.2020

Accepted: 05.03.2021

A – Work concept and design, B – Data collection and analysis, C – Responsibility for statistical analysis, D – Writing the article, E – Critical review, F – Final approval of the article