

EVALUATION OF DYNAMIC CHANGES IN THE MICROCIRCULATION OF THE MUCOSA IN THE ZONE OF DENTAL IMPLANTATION WITH IMMEDIATE INTRAOPERATIVE LOAD

DOI: 10.36740/WLek202309101

Anatoliy Potapchuk¹, Yevhen Onipko¹, Vasyl Almashi¹, Yuriy Rak¹, Csaba Hegedűs², Volodymyr Kryvanych¹, Stepan Sheveria¹

¹UZHGOROD NATIONAL UNIVERSITY, UZHGOROD, UKRAINE

²UNIVERSITY OF DEBRECEN, DEBRECEN, HUNGARY

ABSTRACT

The aim: Study of the dynamics of changes in the average values of the index of mucosal microcirculation after dental implantation with immediate intraoperative prosthetics.

Materials and methods: In clinical conditions, 55 patients aged from 29 to 60 years with a diagnosis of partial absence of teeth requiring orthopedic treatment using implants on the lower jaw were treated and examined. In the course of the latest achievements, the following methods were used: clinical protocol of immediate implantation with Solidum and Simplex implants of the «ART IMPLANT» system on the lower jaw by the one-stage implantation method, with immediate intraoperative loading and the manufacture of a temporary non-removable dental prosthesis, determination of the microcirculation index in dynamics using the laser Doppler method flowmetry, statistical analysis.

Results: The obtained results indicate a pronounced reaction of microcirculation up to the 3rd day after surgery, an increase in blood perfusion of the mucous membrane by 2.7 times while maintaining vasomotor activity, which indicates adaptation to the injury and immediate loading of the denture in the postoperative period. 3 months after dental surgery and immediate intraoperative prosthetics, all indicators of microcirculation approach the initial values before surgery.

Conclusions: With the help of laser Doppler flowmetry, the fact of a sharp restoration of microcirculation after dental implantation surgery with immediate intraoperative prosthetics is confirmed.

KEY WORDS: Laser Doppler flowmetry, immediate intraoperative prosthetics, immediate implantation, indicators of microcirculation, implants of the «ART IMPLANT» system, osseointegration.

Wiad Lek. 2023;76(9):1891-1899

INTRODUCTION

As a result of monitoring and analysis of clinical and experimental studies on the success of dental implantation in the early and distant periods of observation, scientists managed to substantiate the feasibility of introducing into clinical practice not only classical, but also modified protocols of implantation with different terms of subsequent loading [1,2]. At the 6th ITI (International Team of Implantologists) Consensus Conference, held in Amsterdam in April 2018, a group of scientists led by German Gallucci developed a unified classification of dental implant installation and loading protocols for all practically possible clinical situations. Based on the analysis of the publications selected for monitoring that met the evidence criteria, the implant survival rates were calculated with the determination of success and

predictability of each protocol [3,4]. Today, there is a trend towards shortening the terms of subsequent orthopedic rehabilitation. Immediate implantation and immediate intraoperative functional masticatory load allow to reduce the duration of treatment and the volume of surgical intervention and to obtain a high functional and aesthetic result [4]. Today, there are discussions about the features of the formation and level of reduction of peri-implant bone tissue in various conditions, in particular, under load and micromobility [5]. It has been established that around loaded implants there is an increase in blood flow and vasomotor activity of the microcirculatory bed of the supporting tissues, an increase in the volume of bone tissue and an increase in torque, which is an optimal prediction of the acceleration of the rate of osseointegration [6]. The modern systematization

of views on the differentiation of the results of immediate loading and immediate implantation and their interpretation from the point of view of the modern understanding of the mechanisms of bone remodeling expands the opportunities for discussion and argumentation of the prognosis of various dental implantation protocols taking into account the initial conditions of the clinical situation [7,8]. There are a large number of methods and devices that allow you to evaluate various characteristics of the movement and distribution of blood in the body, starting from the simplest: visual observation, listening, palpation, etc. In the 17th century, Marcello Malpighi invented the liquid plethysmograph. From that moment, the era of instrumental blood circulation research began [9,10]. In domestic implantology, standard examination methods do not allow detecting disorders that occur in the mucous membrane area during dental implantation. Therefore, the use of highly informative methods of assessing hemodynamics and metabolism reveal hidden mechanisms of disease development. To date, the study of the state of microcirculation is carried out using various methods, for example, such as laser diagnostics. With the development of science and technology, new opportunities for blood flow research appeared, in particular with the help of laser Doppler flowmetry [11]. The use of laser Doppler flowmetry (LDF) to analyze capillary hemodynamics in real time made it possible to determine microcirculation changes during dental implantation, both two-stage and with immediate loading. The LDF method is based on the use of low-power helium-neon laser radiation ($\lambda = 632.8 \text{ nm}$), which penetrates well into the surface layers of tissues. When radiation is reflected from moving objects (which are erythrocytes in microvessels), there is a change in the frequency of the signal (Doppler effect). Determination of the intensity of microcirculation in tissues is based on this effect [12-16]. An early local sign of pathological disorders is vasoconstriction of arterioles, stagnation in venules and a decrease in blood flow in nutritional capillaries. At the same time, the rhythmic changes of hemodynamics in the microcirculatory channel are disturbed. Successes in the clinical application of the results of microcirculatory studies are associated with the use of capillaroscopy, assessment of microblood flow by laser Doppler flowmetry, and others. The clinical importance of studying microcirculation is determined by the possibility of early detection of tissue viability disorders [17]. Understanding the negative and early terms of implant loading under the influence of functional occlusive loading in conditions with expert analysis of hemodynamic changes in the

microcirculatory channel around implants is limited in fundamental research. Also, there is not enough convincing experimental data on the dynamics of changes in the average values of the microcirculation index (IM) after dental implant surgery and immediate intraoperative prosthetics.

THE AIM

The aim of the study was to Study of the dynamics of changes in the average values of the index of mucosal microcirculation after dental implantation with immediate intraoperative prosthetics.

MATERIALS AND METHODS

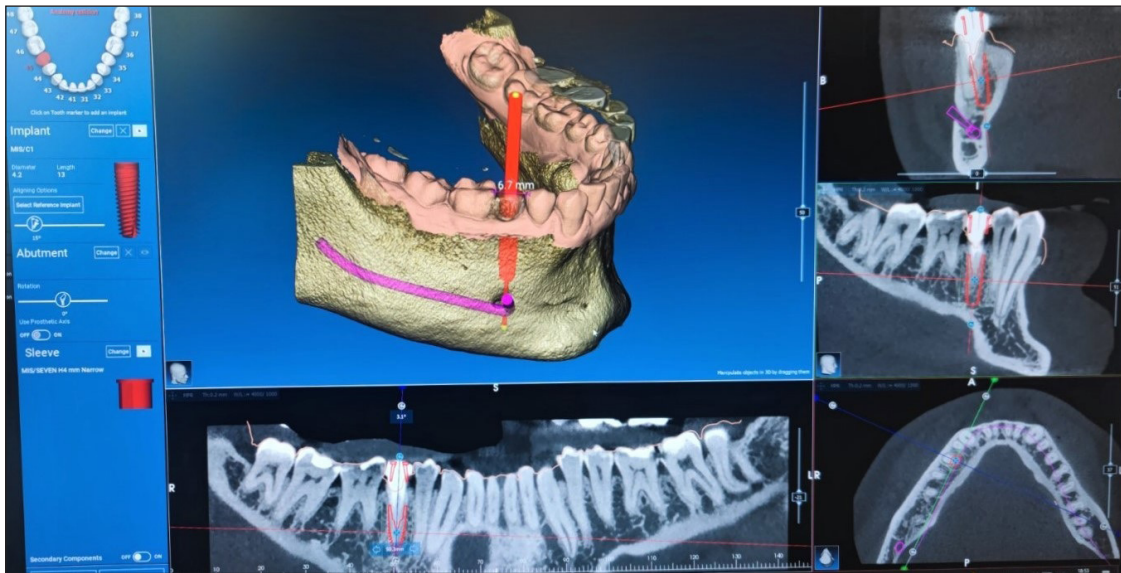
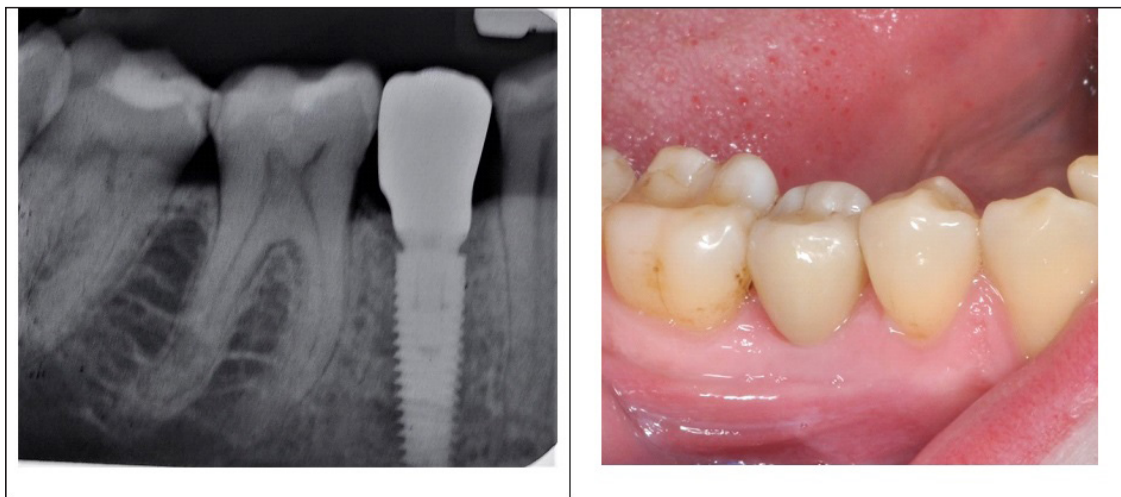
The clinical study was conducted on the basis of the Department of Post-Graduate Education Dentistry of the Uzhhorod National University, the dental clinic «Art dentistry» (Zaporizhia, Ukraine), the university dental clinic of Debrecen University (Debrecen, Hungary). The study was carried out taking into account the main provisions of the GCP ICH and the Helsinki Declaration on Biomedical Research, the Council of Europe Convention on Human Rights and Biomedicine (2007) and the recommendations of the Committee on Bioethics under the Presidium of the National Academy of Sciences of Ukraine (2002) and the positive opinion of the bioethics commission of the Uzhhorod National University .

In clinical conditions, 55 patients (25 male and 30 female patients), aged from 29 to 60 years with a diagnosis of partial absence of teeth (10 - 08.1), requiring orthopedic treatment using implants on the lower jaw, were treated and examined. Prosthetics were performed with fixed orthopedic structures. In order to replace the defect, 65 Solidum and Simplex implants of the «ART IMPLANT» system were installed on the lower jaw by the method of one-stage implantation, with immediate intraoperative loading and the manufacture of a temporary non-removable dental prosthesis. Prosthodontics were performed on 65 implants, 65 temporary plastic crowns were made, and then 65 ceramic or metal-ceramic crowns (Table I). All patients were fitted with dental implants in the defect area of 1-2 teeth on the lower jaw with immediate loading, using intraoperative prosthetics.

The inclusion criteria were - partial loss of teeth, the extent of the defect of 1-2 teeth on the lower jaw (see Fig. 1). Satisfactory or good level of oral hygiene, healthy mucous membrane of the oral cavity, sufficient volume of the jaw bone and its satisfactory density, sufficient space for installing a dental prosthesis, absence of endocrine diseases.

Table I. Distribution of used implants

Implantation system	Number of implants	Number of crowns	Dentition defect	
			1 tooth	2 teeth
Solidum system «ART IMPLANT»	32	32	8	7
Simplex system «ART IMPLANT»	33	33	31	4
Together	65	65	39	11

**Fig. 1.** Clinical situation before implantation.**Fig. 2.** Clinical situation after implantation

The exclusion criteria were - lack of positive motivation for treatment with the use of dental implants, age of the examinee over 65 years, low level of oral hygiene, alcohol abuse and tobacco smoking, chronic generalized periodontitis of medium and severe degrees, significant atrophy of the alveolar part in the area of the dentition defect of the lower jaw, insufficient density of the jaw bone, osteoporosis, insufficient prosthetic space, presence of endocrine diseases, immunodeficiency, blood diseases, radiation and chemotherapy, systemic corticosteroid

therapy, chronic somatic diseases in the stage of decompensation. Planning and treatment of patients was carried out according to the following algorithm: cone-beam computed tomography was performed to obtain files in dicom format for further planning of dental implant installation (see Fig. 1). In the future, after intraoral scanning with an optical scanner to obtain a file in STL format, dicom and STL format files were combined in the 3Diagnosis computer program to compile a complete clinical picture, which includes all anatomical formations of the selected area, a

virtual placement of the implant and its superstructure was carried out. A virtual model of the surgical template is created using the received data about the state of the implant in the PlastyCAD software. The template was printed using a 3D printer. Patients underwent immediate implantation with passive occlusal loading according to traditional one-stage surgical protocols (Schwartz-Arad D. et al., 2007) under Sol local anesthesia. Articaini 4% with a vasoconstrictor 1: 100,000.

After the surgical stage of dental implantation, an optical transfer was installed in the joint of the implant. After obtaining an optical impression, the transfer was temporarily changed to a gingival former (see Fig. 2). After the laboratory production of the temporary superstructure using a RolandDWX-51D milling machine, it was installed in the joint of the implant with a force of 10-15 N.

To evaluate the results of microcirculation research using the laser method Doppler flowmetry (LDF) in patients with partial adentia, the condition of the frontal and lateral areas of the lower jaw was studied using system moor VMS LDF2 (785 ± 10 nm, maximum power 2.5mW) (Moor Instruments Ltd. Millwey Axminster Devon EX13 5HU, UK) (Fig. 1) and needle probes as per the manufacturer's instructions, and were processed by the use of specialized software (moor VMS-PC, V 3.1 for Vascular Monitor System).

The results of laboratory and clinical studies were processed by methods of variational statistics with determination of the mean value, its errors, Student's t-test for multiple comparisons, using Excel (MS Office 2010, Microsoft, USA) and STATISTICA 6.0 (StatSoft, USA).

Differences in indicators at the level of significance $p < 0.05$ were considered statistically significant.

RESULTS

According to the data of the patients before the dental implantation operation, the integrated indicator of microcirculation (IM), which reflects the level of blood flow in the mucous membrane, was on average 8.50 ± 0.43 points. (Figure 3). At the same time, the temporal variability of blood perfusion σ , which characterizes fluctuations in the flow of erythrocytes in the microcirculatory channel, was 0.90 ± 0.04 p.o. (Figure 4). Vasomotor activity of microvessels (Kv) was equal to $10.59 \pm 0.48\%$ (Figure 5). After dental implant surgery with immediate intraoperative prosthetics, after 3 days IM increased sharply by 2.7 times ($P < 0.001$) and the fluctuation of erythrocyte flow (σ) also increased by 3.1 times ($P < 0.001$) (Figures 3, 4).

However, vasomotor activity (Kv) increased by 7.06%, which indicates compensatory reactions of the microcirculation system in the mucosa (Figure 5). 10 days after the operation, the level of blood flow in the microcirculatory channel of the PM began to decrease, but it significantly exceeded the initial values by 125.88% ($p < 0.001$). Fluctuation of the flow of erythrocytes (σ) in the microcirculatory channel also had a tendency to decrease in amplitude, while its values exceeded those before surgery by 123.33% ($p < 0.001$). Kv at the same time remained approximately at the same level

Table II. Indicators of vascular tone in the microcirculatory channel of the mucous membrane in the area of installation of dental implants with immediate load according to the wavelet analysis of LDF- grams.

	Before the operation	3 days after surgery	10 days after surgery	After the operation in 1 month	3 months after the operation
NT					
n	25	23	23	21	19
M	3,57	4,07	2,50	2,88	4,71
m	± 0,16	± 0,18	± 0,11	± 0,13	± 0,21
p <		0,05	0,001	0,05	0,05
MT					
n	25	23	23	21	19
M	2,22	2,19	4,41	2,46	2,75
m	± 0,10	± 0,10	± 0,20	± 0,11	± 0,12
p <			0,001		0,05
SHI					
n	25	23	23	21	19
M	0,62	0,54	1,77	0,85	0,59
m	± 0,03	± 0,02	± 0,08	± 0,04	± 0,03
p <		0,05	0,001	0,05	

Notes: p - significant differences after surgery

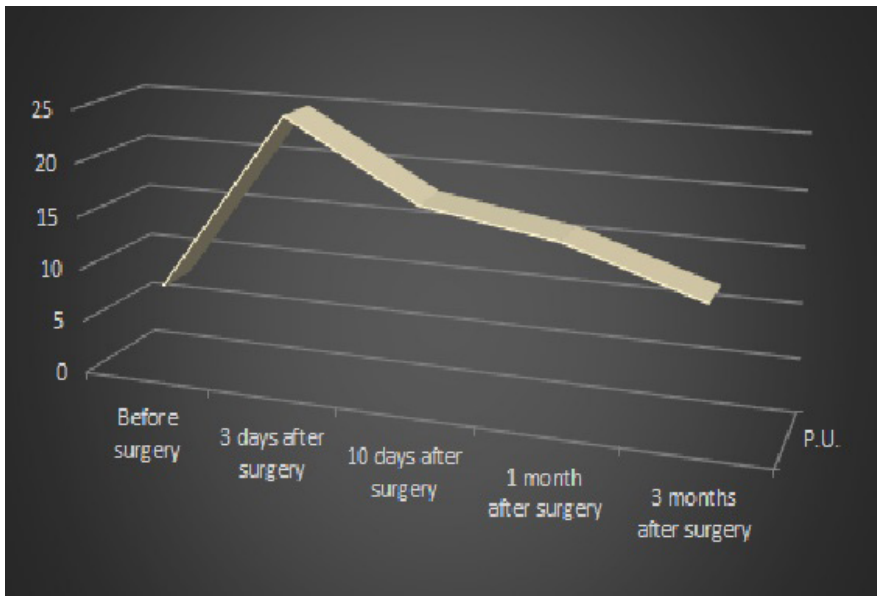


Fig. 3. Dynamics of changes in the average values of the microcirculation (IM) index after dental implant surgery and immediate intraoperative prosthetics

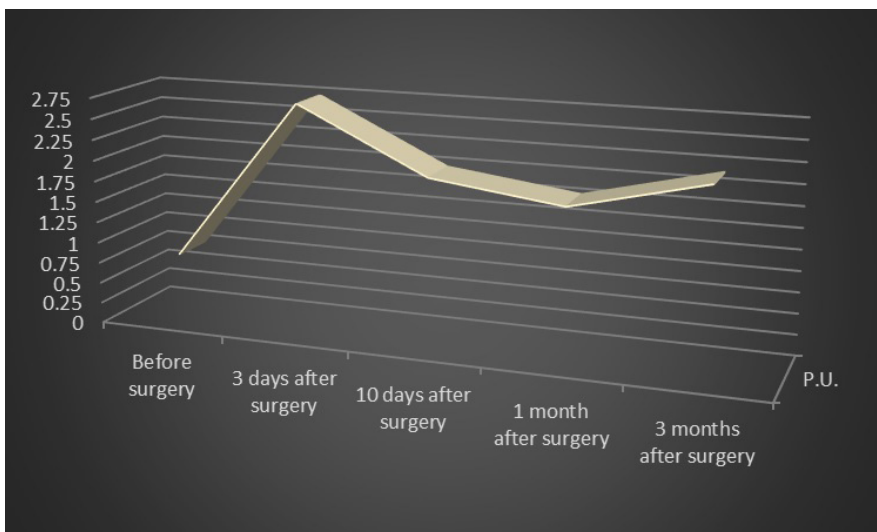


Fig. 4. Dynamics of changes in the average values of erythrocyte flow fluctuations (σ) after dental implant surgery and immediate intraoperative prosthetics

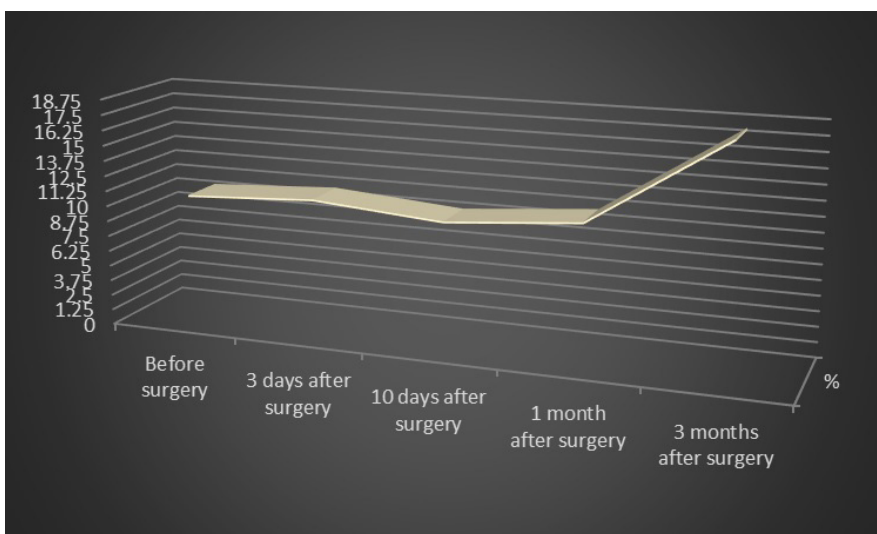


Fig. 5. Dynamics of changes in the average values of the coefficient of variation (K_v) after dental implantation surgery and immediate intraoperative prosthetics

(Figures 3, 4, 5). After 1 month, a decrease in IM and σ was recorded to 16.90 ± 0.85 perf. units. and 1.90 ± 0.09 perf. units. in accordance. However, their values significantly exceeded the initial level by 1.99 and 2.11

times ($p < 0.001$). In the remote period, 3 months after the operation, the blood flow level (IM) in the mucous membrane was on average 8.50 ± 0.43 perf. units, which is 34.12% higher than the initial level before the

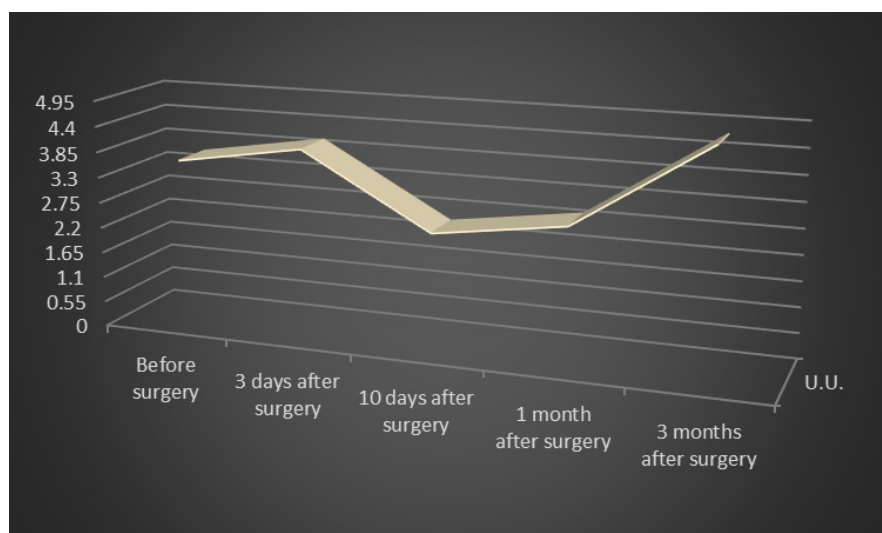


Fig. 6. Dynamics of changes in neurogenic tone (NT) after dental implant surgery and immediate intraoperative prosthetics according to wavelet analysis of LDF-grams

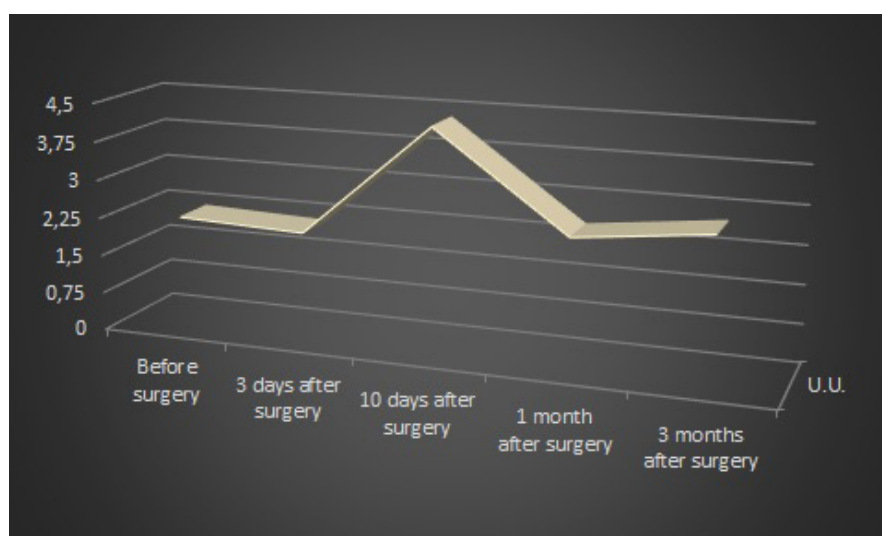


Fig. 7. Dynamics of changes in myogenic tone (MT) after dental implant surgery and immediate intraoperative prosthetics according to wavelet analysis of LDF-grams

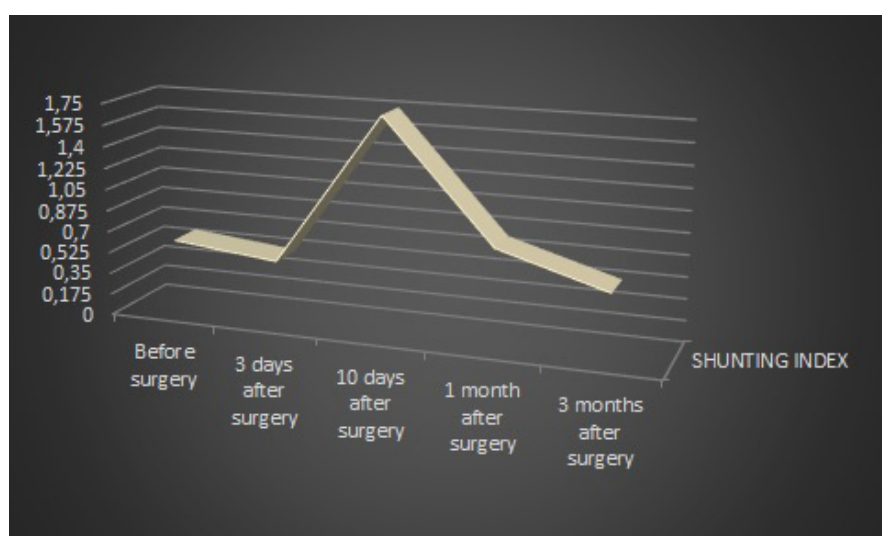

Fig. 8. The dynamic of changes in the shunt index (SHI) after dental implant surgery and immediate intraoperative prosthetics according to the wavelet analysis data of LDF – gram

operation ($p < 0.05$). At the same time, the fluctuation of the flow of erythrocytes (σ) in the microcirculatory channel was 2.10 ± 0.09 perf. unit increased by 133.33% ($p < 0.001$), which may indicate the improvement of the trophic function in the mucous membrane, which is an indicator of the restoration of the entire jaw bone

complex. The analysis of these indicators, reflecting the vasomotor activity (Kv) in the microcirculatory channel, revealed an increase in its values by 73.98% compared to the preoperative values ($p < 0.001$) (see Figure 5).

The results of wavelet analysis of LDF - grams, presented in Table II, revealed an increase in the

neurogenic tone (NT) of precapillary vessels in the microcirculatory channel of the mucous membrane of the jaws 3 days after dental implantation with immediate loading by 13.93% ($p < 0.05$), and after 10 days - a decrease by 30.04% ($p < 0.001$) compared to the initial values. 1 month after surgery, NT had a tendency to increase, but its values were lower than the initial level by 19.28% ($p < 0.05$). After 3 months, NT amounted to 4.71 ± 0.21 perf. units. and exceeded baseline by 31.88% ($p < 0.05$) (see Figure 6) (see Table II). Myogenic tone (MT), which is also involved in the active regulation of microcirculation before dental implant surgery, was equal to 2.22 ± 0.10 perf. units. After dental implantation with immediate loading, after 3 days, the values tended to decrease, and after 10 days after surgery, they increased by 99.06% ($p < 0.001$).

One month after dental implantation with immediate loading, the values dropped and differed from the preoperative level by 10.97%, and by 24.24% - after 3 months ($p < 0.05$) (see Figure 7) (see Table II).

The shunting index (SHI), which characterizes the ratio of shunting and nutritional blood flow in the microvascular network, was initially 0.62 ± 0.03 u.o. 3 days after dental implantation, his digital values tended to decrease (see Figure 8). After 10 days, its values increased by 2.85 times, which may indicate the reaction of the microcirculation in the mucous membrane to the traumatic injury of the jawbone during dental implantation and immediate intraoperative prosthetics ($p < 0.001$). One month after the operation, the SHI decreased and was higher from the initial level by 37.48% ($p < 0.05$), and after 3 months its values slightly differed from the preoperative level - 0.59 ± 0.03 u.o. This may indicate the restoration of blood circulation in the microcirculation system of the jawbones after dental implantation.

DISCUSSION

According to research János Jarabin, Zsófia Bere: the non-implanted yet previously operated contralateral sides of the patients demonstrated marginally lower ($p = 0.09$) blood flux index. The STR sides however, showed significantly lower (average 217 %) provoked blood flux compared to cotrols ($p < 0.001$). At the STP sides a maladaptation could be observed (average 316 %) compared to the contralateral sides ($p = 0.53$). STP sides demonstrated a significantly better blood flow improvement compared to the STR sides ($p = 0.02$).

These results suggest a favorable postoperative condition of vascular microcirculation after STP, than after STR surgery [18].

According to research Vladimir Kokovic, Elena Krsljak: the measured PU values ranged from 17.5 to 130.7 with a mean of 53.05. LDF >60 PU was measured at 8 implants sites, LDF <60 and ≥ 40 PU at 18sites, and LDF <40 PU at 10 sites. There were no statistically significant differences between mean values of the left and right sides of the mandibles as well as between different implants positions. There was no statistically significant difference in vascularity between men (53.3) and women (51.5) [19].

According to research F F Losev , E K Krechina , M M Kayugin LDF data, it was established that the level of microcirculation in the mucous membrane of the alveolar ridge in response to the functional load after fixation of the removable prosthesis with fixation on locators (group 1) and on telescopic crowns (group 2), it is accompanied by an increase in the level of M and σ by 37% and 66%, and by 2.2-2.4, respectively, which indicated the development of hyperemia in the microcirculatory bed, which is associated with functional load and persists up to 3 and 6 months, respectively. Restoration of microcirculation occurs after 6 and 12 months, respectively, after prosthetics, depending on the supporting elements. After fixation of the removable prosthesis, SpO₂ and U decreased, which characterized the development of hypoxia in the tissues due to functional load, which stopped after 3 and 6 months, respectively [20].

CONCLUSIONS

The use of laser Doppler flowmetry made it possible to monitor the microcirculation system during dental implantation and immediate intraoperative prosthetics. The obtained results indicate a pronounced reaction of microcirculation up to the 3rd day after surgery, an increase in blood perfusion of the mucous membrane by 2.7 times while maintaining vasomotor activity, which indicates adaptation to the injury and immediate loading of the denture in the postoperative period.

3 months after dental surgery and immediate intraoperative prosthetics, all indicators of microcirculation approach the initial values before surgery. This fact confirms the positive dynamics of recovery of microhemodynamics after dental implantation and immediate intraoperative prosthetics, thus, the dynamics of osseointegration is accelerated, which is confirmed by high indicators of the implant stability coefficient.

REFERENCES

1. Tonetti MS, Cortellini P, Graziani F et al. Immediate versus delayed implant placement after anterior single tooth extraction: the timing randomized controlled clinical trial. *J Clin Periodontol*. 2017; 44(2):215-224. doi: 10.1111/jcpe.12666.
2. Potapchuk AM, Onipko YeL, Almashi VM, Hegedűs C. Comparative evaluation of clinical application of monolithic and folding implants in rehabilitation of elderly patients with various degrees of atrophy of alveolar processes. *Wiad Lek*. 2022. DOI: 10.36740/WLek202204201.
3. Tarazona B, Tarazona-Álvarez P, Peñarrocha-Oltra D, Peñarrocha-Diago M. Relationship between indication for tooth extraction and outcome of immediate implants: A retrospective study with 5 years of follow-up. *J Clin Exp Dent*. 2014;6(4):e384-8. doi: 10.4317/jced.51616.
4. Potapchuk AM, Onipko YeL, Almashi VM, Hegedűs C. Comparative evaluation of clinical application of monolithic and folding implants in rehabilitation of elderly patients with various degrees of atrophy of alveolar processes. *Wiad Lek*. 2022;75(4 p2):921-928. doi: 10.36740/WLek202204201.
5. Montero J, Fernández-Ruiz A, Pardal-Peláez B et al. Effect of Rough Surface Platforms on the Mucosal Attachment and the Marginal Bone Loss of Implants: A Dog Study. *Materials (Basel)*. 2020;13(3):802. doi: 10.3390/ma13030802.
6. Sheng L, Silvestrin T, Zhan J et al. Replacement of severely traumatized teeth with immediate implants and immediate loading: literature review and case reports. *Dental Traumatology*. 2015;31(6):493-503. doi: 10.1111/edt.12201.
7. Savranskiy FZ, Simakhov RV, Grishin PO et al. Osobennosti provedeniya neposredstvennoy implantatsii i nemedlennoy nagruzki pri primenenii implantatsionnoy sistemy "Humana Dental". [Features of direct implantation and immediate loading when using the "Humana Dental" implantation system]. *Suchasna stomatologiya*. 2018, pp. 58-63.
8. Potapchuk AM, Onipko YeL, Almashi VM et al. Experimental study of bone rebuilding in the periimplantation area under immediate loading on dental implants. *Wiad Lek*. 2021;74(4):992-997. doi: 10.36740/WLek202104134.
8. Albrektsson T, Wennerberg A. On osseointegration in relation to implant surfaces. *Clinical Implant Dentistry and Related Research*. 2019;21(1):4-7. doi: 10.1111/cid.12742.
9. Sommer M, Zimmermann J, Grize L, Stübinger S. Marginal bone loss one year after implantation: a systematic review of different loading protocols. *International Journal of Oral and Maxillofacial Surgery*. 2020;49(1):121-134. doi: 10.1016/j.ijom.2019.03.965.
10. Guyton A, Hall J. *The Microcirculation and the Lymphatic System*. Textbook of Medical Physiology. Philadelphia, Pennsylvania: Elsevier Inc. 2012, pp. 187–188.
11. Ghouth N, Duggal MS, BaniHani A, Nazzal H. The diagnostic accuracy of laser Doppler flowmetry in assessing pulp blood flow in permanent teeth: A systematic review. *Dent. Traumatol*. 2018;34(5):311-319. doi: 10.1111/edt.12424.
12. Todea C, Cănjău S, Miron M et al. Laser Doppler flowmetry evaluation of the microcirculation in dentistry. *InTech*; London, UK. 2016, pp. 203–230.
13. Miron MI, Dodenciu D, Sârbescu PF et al. Optimization of the laser doppler signal acquisition technique in pulp vitality tests. *Arch. Balk. Med. Union*. 2011; 46(4):280–284.
14. Nakamoto T, Kanao M, Kondo Y et al. Two-dimensional real-time blood flow and temperature of soft tissue around maxillary anterior implants. *Implant. Dent*. 2012;21(6):522-7. doi: 10.1097/ID.0b013e318272fe81.
15. Sabioni L, De Lorenzo A, Lamas C et al. Systemic microvascular endothelial dysfunction and disease severity in COVID-19 patients: Evaluation by laser Doppler perfusion monitoring and cytokine/chemokine analysis. *Microvasc. Res*. 2021;134:104119. doi: 10.1016/j.mvr.2020.104119.
16. Roustit M, Cracowski JL. Assessment of endothelial and neurovascular function in human skin microcirculation. *Trends Pharm*. 2013;34(7):373-84. doi: 10.1016/j.tips.2013.05.007.
17. Reiko Y, Kaori A, Satoko-Wada T et al. Changes in the microcirculation in periodontal tissue due to experimental peri-implantitis. *J. Oral Biosci*. 2021;63(2):153-160. doi: 10.1016/j.job.2021.03.002.
18. Jarabin J, Bere Z, Hartmann P et al. Laser-Doppler microvascular measurements in the peri-implant areas of different osseointegrated bone conductor implant systems. *Eur Arch Otorhinolaryngol*. 2015;272(12):3655-62. doi: 10.1007/s00405-014-3429-0.
19. Kokovic V, Krsljak E, Andric M et al. Correlation of bone vascularity in the posterior mandible and subsequent implant stability: a preliminary study. *Implant Dent*. 2014;23(2):200-5. doi: 10.1097/ID.0000000000000057.
20. Losev F, Krechina E, Kayugin M. Comparative assessment of the processes of adaptation of supporting tissues in prosthetics with the use of implants. *Stomatologija (Mosk)*. 2021;100(4):44-48. doi: 10.17116/stomat202110004144.

ORCID and contributionship:

Anatoliy Potapchuk: 0000-0001-9857-1407^{A, B, E, F}

Ievgen Onipko: 0000-0002-3086-4657^{B, D}

Vasyl Almashi: 0000-0002-2943-4844^{A, B, C, E}

Yuriy Rak: 0000-0002-0963-1541^{B, D}

Csaba Hegedűs: 0000-0003-4143-2507^{D, E}

Volodymyr Kryvanych: 0000-0002-3522-9476^E

Stepan Sheveria: 0009-0007-6387-4521^E

Conflict of interest

The Authors declare no conflicts of interest.

CORRESPONDING AUTHOR

Anatoliy Potapchuk

Uzhgorod National University

60a Station Street, 88000 Uzhhorod, Ukraine

e-mail: anatoliy.potapchuk@uzhnu.edu.ua

Received: 09.04.2023

Accepted: 11.08.2023

A - Work concept and design, **B** – Data collection and analysis, **C** – Responsibility for statistical analysis, **D** – Writing the article, **E** – Critical review, **F** – Final approval of the article

 Article published on-line and available in open access are published under Creative Common Attribution-Non Commercial-No Derivatives 4.0 International (CC BY-NC-ND 4.0)