

**MINISTRY OF EDUCATION AND SCIENCE OF UKRAINE  
NATIONAL HIGHER  
EDUCATIONAL INSTITUTION  
«UZHHOROD NATIONAL UNIVERSITY»  
FACULTY OF DENTISTRY  
DEPARTMENT OF THERAPEUTIC DENTISTRY**

**Educational and methodological recommendations for 3rd year students in  
the discipline "Therapeutic dentistry". "Methods of examination of a  
dental patient". "Caries and non-carious dental lesions"  
*Goncharuk-Khomyn M.Y., Biley M.V., Nesterenko M.L.***

**Uzhhorod 2024**

**UDC 616.314-002**

**Educational and methodological recommendations for 3rd year students in the discipline "Therapeutic dentistry". "Methods of examination of a dental patient". "Caries and non-carious dental lesions"./ Goncharuk-Khomyn M.Y., Biley M.V., Nesterenko M.L. – Uzhhorod, 2024. – 176 p.**

*The group of authors-compilers:*

**Goncharuk-Khomyn M.Y.** – PhD., head of the department of therapeutic dentistry «UzhNU»;

**Nesterenko M.L.** – teaching assistant of the department of therapeutic dentistry «UzhNU»;

**Biley M.V.** – laboratory assistant of the department of therapeutic dentistry «UzhNU».

Educational and methodical recommendations are developed for studying the program in the discipline "Therapeutic Dentistry" by the 3rd year students of the dental faculty. These guidelines include methodological developments for conducting practical classes in conjunction with control tasks and a list of recommended educational and methodological literature, which are aimed at deepening students' knowledge of the diagnosis and treatment of diseases of hard dental tissues of various etiologies (carious and non-carious genesis), as well as the study of generally accepted and modern classifications of pathologies of hard dental tissues, their etiology, pathogenesis and clinical manifestations; approaches to the diagnosis of hard tissue pathologies of teeth using clinical and additional methods of examination of patients with odontopathologies; principles of treatment and prevention of the above diseases and their complications.

Educational and methodical recommendations were reviewed and approved at the meeting of the Department of Therapeutic Dentistry of the Faculty of Dentistry. «Uzhhorod National University». Protocol № 1 of January 18, 2024.

## **MODULE 1: "METHODS OF EXAMINATION OF A DENTAL PATIENT"**

### **METHODICAL DEVELOPMENT №1**

**TOPIC:** Organisation of dental care in Ukraine.

The structure of a dental clinic and its therapeutic department. Tasks of therapeutic dentistry, interrelation with general clinical and dental disciplines.

**I. Topic relevance:** In terms of the pace of development and implementation of modern technologies and treatment methods, the dental service in Ukraine is a leader in the healthcare system. A student of dental faculty in the 3rd year of study should consistently master new sections of therapeutic dentistry and begin his/her practical work, treatment of dental caries, in accordance with the progressive developments of domestic and world dentistry. The dental office, its organisation and equipment are the most important things that stand at the beginning of a dentist's work.

### **II. Study goal:**

#### ***2.1. Student has to know:***

- Know the organisation of dental services in Ukraine.
- Know the sanitary and technical standards for dental offices in healthcare facilities.
- Know the sanitary and hygienic requirements for a dental office in a healthcare facility.
- Know the safety rules for working in a dental office.
- Know the main and auxiliary dental equipment for the organisation of differentiated work of a general practitioner.
- Master the organisation, equipment and furnishing of a dental office.
- Master the rules of safety and work in the dental office.
- Know modern dental drugs and materials for therapeutic treatment of patients.

#### ***2.2 Be able to:***

- Apply sanitary and technical standards in the organisation of a dental office.
- Organise work in the dental office.
- Properly organise the workplace and rationally place equipment in the dental office.
- Choose the main and auxiliary equipment of the dental office.

### **III. Content of the topic**

**Sanitary and hygienic requirements for the dental office:**

1. The area of the room
2. The height of the room
3. The width of the room
4. Requirements for:
  - Walls of the office;
  - Ceiling of the office;
  - The floor of the office;
  - Doors and windows of the office.
5. Lighting of the office:
  - Natural;
  - Artificial.
6. Microclimate:
  - Air conditioning;
  - Ventilation;
  - Heating;
  - Quartzing;
7. Distance between seats and their placement
8. Bathroom facilities

#### **Dental office equipment:**

##### **I. Basic:**

1. Dental unit:
  - Toolbox;
  - Control unit;
  - Hydraulic unit;
  - Lighting unit;
  - Dental chair;
  - Compressor.
- 2 Mobile chair with backrest for the doctor.
- 3 Chair for an assistant.
- 4 Dental table - mobile or stationary.

##### **II. Additional:**

1. Photopolymer lamp.
2. Scaler.
3. Diathermocoagulator.
4. Apex locator.
5. Endomotor and endonuclease.
6. Radiovisiograph.

##### **III. Equipment for sterilisation and disinfection:**

1. Dry oven for sterilising instruments.
2. Table with sets of sterile instruments.
3. Quartz lamp.
4. Fume hood.

##### **IV. Equipment for hand treatment and pre-sterilisation:**

1. Hand wash basin for washing hands.
2. Containers with disinfectant solution for soaking instruments with a cabinet for containers with disinfectant solutions.

##### **V. Equipment for the work of a nurse:**

1. A table for keeping records.
2. A chair.
3. Computer.

4. A safe for storing documents.

**VI. Medical furniture:**

1. The doctor's desk.

2. Cabinet for storing medicines of group A and B.

3. Cabinet for storing instruments, bandages and sealing material.

## **ORGANISATION OF THE DENTAL SERVICE**

The foundations of state dental care in Ukraine were defined in April 1920 by the Order "On the State Organisation of Dental Care in the Ukrainian Republic", which legalised it as publicly accessible and free of charge with a preventive focus.

The first centralised management body for the dental service in Ukraine was the dental section of the Medical Medicine Department, established in April 1920 within the structure of the People's Commissariat of Health, with similar sections in provincial health departments.

In the early 20s, the search for optimal forms of organising dental care within the framework of an outpatient service was underway. Dentists were trained at odontology faculties established at medical institutes (Kyiv, 1920) and universities (Kharkiv, 1921), at odontology departments and dental schools. In many cities of Ukraine, private dental schools were transformed into public ones.

After the organisation of medical faculties into independent medical institutes, the departments of odontology were renamed into the departments of dentistry. A. I. Yevdokimov, I. G. Lukomskyi, E. M. Gofung, D. A. Epstein, Z. B. Pyriatynskyi invested a lot of effort and knowledge in the development of higher dental education.

The publication of a special journal, which is now published under the name "Dentistry", was important for the expansion of scientific knowledge.

In the 1920s, more than 400 dental outpatient clinics, more than 40 dental laboratories, 6 children's clinics in Odesa and a central school clinic in Mykolaiv were established on the basis of nationalised dental offices. In the early 1930s, there were 4 types of dental institutions in the country: independent dental outpatient clinics (factory and school), dental offices at dispensaries and hospitals, private dental offices and dental prosthetic institutions. Since 1930, odontology faculties in Ukraine have been separated into independent dental institutes (in Kyiv and Kharkiv).

Currently, there are the Ukrainian Medical Dental Academy, the Research Institute of Dentistry in Odesa, and a number of dental faculties in Ukraine.

In the course of training, great importance is attached to improving the basic knowledge of dentists, especially in the context of possible specialisation in dentistry, in the so-called mini-specialties (periodontics, odontology and

hygiene) within therapeutic dentistry, and material science in orthopaedic dentistry.

The formation of a new type of specialist involves improving the targeted training of dentists through the system of postgraduate training through internships, creating a "specialisation model".

### **Dental care (outpatient) is provided in Ukraine:**

- independent dental clinics (republican, regional, city, district);
- dental departments within territorial polyclinics of cities, central district hospitals and primary health care centres at industrial enterprises;
- in dental offices of hospitals, dispensaries, antenatal clinics, educational institutions;
- -independent children's polyclinics;
- self-supporting polyclinics.

Admission to dental polyclinics and departments is carried out in the field of therapeutic, orthopaedic and surgical dentistry.

#### **The modern dental clinic includes departments and offices:**

- Therapeutic dentistry with a room for the treatment of periodontal and oral mucosa diseases;
- Department (office) of Surgical Dentistry with an operating unit;
- Orthopedic department with a dental prosthetic laboratory and a foundry;
- Mobile dental care and dental disease prevention department;
- X-ray rooms.

The dental clinic's examination room plays an important role in regulating the flow of patients.

Specialised outpatient dental care is one of the most widespread types of medical services provided to the population. The proportion of dental morbidity in the total morbidity of the population by referral reaches more than 16%. The number of people seeking dental care is second only to visits to general practitioners, with 90% of the population suffering from caries and 40% from periodontal disease.

In-patient dental care is provided in dental departments or specialised beds in republican, regional, municipal, district, and clinics of research institutes, medical universities, and institutes and institutes for the improvement of doctors.

Planning and management of the work of all institutions is entrusted to chief specialists.

The chief specialist is appointed from among the chief doctors of republican, regional and municipal dental clinics. The chief dentist, through the management of healthcare institutions and local healthcare authorities, must provide organisational, methodological and scientific guidance to the work of dental institutions.

### **Independent dental clinics**

Regardless of the location (republican, oblast, city, district), according to the number of medical positions, they can be of 5 categories:

- non-category - more than 40 positions;
- Category 1 - 30 - 40 positions;
- Category 2 - 25 - 30 positions;
- Category 3 - 20 - 25 positions;
- Category 4 - 15 - 20 positions;
- Category 5 - 10 - 15 positions.

The number of medical staff is calculated based on the population, assuming that each resident has 2.2 visits per year. For every 10,000 adults, 4.0 dentist positions (therapist + surgeon) and 1 prosthetist position are allocated for 4-5 dentist positions.

For every 10 thousand children, 4.5 dentist positions are allocated.

Currently, the number of dentists in Ukraine is 4.0 per 10 thousand people.

### **Structure of a dental clinic**

The polyclinic includes special departments:

- 1 - therapeutic dentistry;
- 2 - surgical dentistry;
- 3 - orthopaedic dentistry;
- 4 - paediatric dentistry (where there is no children's dental clinic).

In addition, the polyclinic includes the following rooms:

- 1 - functional diagnostics;
- 2 - paradontology;
- 3 - anaesthesia;
- 4 - physiotherapy;
- 5 - radiological.

The polyclinic is managed by dental offices or departments at general polyclinics, dispensaries, schools, and the Ministry of Health. The polyclinic also includes

- 1 - dental laboratory;
- 2 - clinical laboratory;
- 3 - organisational and methodological office;
- 4 - registration office;
- 5 - administrative and economic part.

The dentist's office is equipped with a dental chair, a universal dental or turbine drill with a set of dental instruments (spatula, mirror, tweezers, probes, etc.), instruments for filling and removing dental plaque, burs, pulp extractors, root needles, root canal fillers, filling material and medicines.

Doctors work in two shifts on a rolling schedule.

The district therapeutic principle of dental care has been developed. This takes into account the incidence of dental diseases, the age composition of the population, and the availability of medical staff.

One anaesthetist position is established for every 20 dental medical positions. Dental departments of hospitals and healthcare facilities

Dental departments are established where there are no independent dental clinics. They provide differentiated treatment. A department is created if there are 8 or more dentists. One of them is appointed head of the department.

Independent dental offices are set up in hospitals, polyclinics, antenatal clinics, medical centres, health posts, and schools.

Most often, dental care is provided to the public in a dental office. In hospitals with more than 250 beds, one dentist position is allocated and one additional position for every 300 beds above this. If a hospital has fewer than 250 beds, but has a dental office, 0.5 dentist positions are allocated.

Tuberculosis hospitals are allocated 0.5 positions for 75 to 200 beds. If tuberculosis hospitals have more than 200 beds, one dentist position is allocated. In paediatric tuberculosis hospitals, even if there are 50 beds, 0.5 positions of dentist are allocated.

In general polyclinics, if the number of dentists is less than 8, dental offices are created, but they must provide differentiated reception.

Dental offices are set up in medical and sanitary units and health centres if there are 1500 or more employees at all industrial enterprises and construction sites.

Chemical industry enterprises are allocated 0.75 positions per 1,000 employees.

Schools and universities have a dental office if there are 800 or more students.

In antenatal clinics, one position per 100,000 people is allocated, and 0.5 positions per 50,000 people. More than one position in an antenatal clinic is not allocated.

### **Functions of a dental clinic.**

A dental polyclinic is the main specialised medical and preventive care institution that provides highly qualified and specialised care for diseases of the oral cavity and teeth.

#### **The main functions of dental clinics are:**

- 1) organisation and provision of specialised dental care to various population groups;
- 2) implementing the dispensary method in the activities of dentists to prevent diseases of the oral cavity and teeth;
- 3) organising and carrying out oral cavity sanitation both in a planned manner and when the population addresses dental institutions;
- 4) development and improvement of comprehensive medical check-ups in cooperation with district (shop) therapists, as well as paediatricians, obstetricians-gynecologists, ENT and other specialists of general and children's polyclinics, antenatal clinics, and dispensaries;



- 5) development of narrow-profile types of dental care and their approximation to the population;
- 6) improvement of treatment and diagnostic methods: physiotherapeutic, X-ray, biochemical, cytological, functional diagnostic, etc;
- 7) promotion of hygienic and medical knowledge in the field of dentistry among the population;
- 8) accounting and reporting dental documentation.

Medical examination of dental patients is a system of measures aimed at early detection of diseases of the teeth and other organs and tissues of the oral cavity and maxillofacial region; elimination of the causes of these diseases; quantitative examination and treatment of patients registered for medical examination and preservation of their working capacity.

The selection of dental patients for dispensary supervision should be carried out by dentists of all specialties, regardless of the place of work and the nature of the appointment.

Patients subject to dispensary supervision are referred to district and workshop dentists.

The following patients are subject to dispensary supervision by dentists with multiple progressive dental caries, fluorosis, periodontal disease of I-III degree, chronic gingivitis and stomatitis, cheilitis, glossalgia, odontogenic neuralgia of the trigeminal and facial nerves, chronic osteomyelitis of the facial bones, chronic sinusitis, chronic inflammation of the salivary glands, precancerous diseases of the jaws and cavity malignant neoplasms of the jaws and oral cavity, congenital clefts of the maxillofacial region, dentoalveolar anomalies, congenital and acquired deformities of the jaws.

**A plan of treatment and preventive measures is drawn up for each patient in the clinic, which includes:**

- 1) an in-depth study of the patient's working and living conditions and a detailed clinical examination;
- 2) outpatient (or inpatient) treatment: oral cavity sanitation, medication, surgery, physiotherapy, etc;
- 3) referral of a patient for consultation with doctors of another speciality (ENT 1, etc.)
- 4) compliance of the patient with personal prevention measures, work, rest, nutrition, and rational employment;
- 5) analysis of the effectiveness of dental patients' medical examination.

For each patient, along with the outpatient card, a control card of the dispensary patient is filled out (form N° 030/y).

The main medical and preventive measures of the dispensary are: scheduled oral cavity sanitation, which is carried out from the age of 3 throughout life, primarily in organised teams.

### **Key performance indicators of dentists in the outpatient service:**

#### *Patient admission rates:*

- general dentists - 3 persons per hour,
- surgeons - 5 persons per hour,
- orthopedists - 2 persons per hour,
- mixed reception - 3.2 persons per hour.
- Qualitative indicators of a dentist-therapist
- Prevention of dental caries.
- Scheduled sanitation of employees of leading professions with hazardous working conditions.
- Sanitation among schoolchildren and preschoolers.
- Sanitation of pregnant and lactating women.
- Sanitation of patients with sore throats and gastrointestinal diseases.
- Percentage of visits by rural residents.
- Share of primary visits.
- Share of sanitised patients among all primary patients.
- Percentage of patients in need of oral cavity sanitation identified from among those examined as part of routine sanitation.
- Percentage of sanitised patients among those identified as part of the routine sanitation.

A unit of work of a dentist is considered to be a completed work (applying a filling within 20 minutes, taking anamnesis, making a diagnosis, recording in the medical history, washing hands, processing and shaping the tooth cavity and applying a filling).

- The period of preservation of the filling is at least 2 years.
- Treatment of pulpitis - in 2 visits.
- Treatment of periodontitis - in 3 visits.

#### **IV. Control questions for the class topic:**

1. Organisation of therapeutic dental care in Ukraine.
2. Types and structure of dental clinics.
3. Functions of the dental clinic.
4. The main indicators of the work of a dentist - therapist.
5. Sanitary and hygienic requirements for the organisation of a dental office.
6. Equipment of the dental office.
7. Safety rules when working in a dental office.
8. Organisation of the workplace of a dentist - therapist.

#### **V. Control test tasks and/or case tasks:**

1. According to sanitary and hygienic standards, the microclimate of a dental office consists of:
  - A. Heating, lighting, floor space, air conditioning and ventilation;
  - B. Condition of the walls of the room;
  - C. Quartzizing;

D. The height of the room.

**The correct answer is: A.**

2. The height of the dental office in accordance with sanitary and hygienic standards should be not less than:

- A. 5 metres
- B. 2 metres
- C. 3 metres
- D. 4 metres
- E. 2.5 metres

**The correct answer is: C.**

3. The walls of the dentist's office are painted bright red. What colour should be chosen:

- A. Brown
- B. Light tone (light grey, light blue, light green)
- C. Blue
- D. Orange
- E. Purple

**The correct answer is: B.**

4. Assess the compliance of the conditions that are put forward by the requirements for the organisation of a dental office, if one chair has an area of 7 sq. m. in a room located in the basement without sewage and with artificial lighting.

**The correct answer is:** in this room, according to sanitary and hygienic standards, it is impossible to place a dental office, because:

- 1) One dental chair must have an area of at least 14 square metres.
2. The room must have natural light.
- 2) The room must have a sewage system and a ventilation system.
- 3) In addition, working in such an office will violate the rules of ergonomics in dentistry.

5. During a routine medical check-up of dentists, one of the doctors was diagnosed with hepatitis C. Name the possible reasons for the doctor's infection while working with the patient.

**The correct answer is:**

The doctor may not have followed the safety rules while working with the patient, namely:

- worked without gloves;
- used non-sterile boron or endo instruments after treating a patient with hepatitis C
- accidentally injured himself with an endo instrument (pierced his glove) while treating a patient with hepatitis C.

In addition, during the treatment of patients, doctors should wear: a medical mask, dental glasses and latex or nitrile gloves, a cap and a long-sleeved gown.

6. A dental office with a total area of 10 m', located in a basement without sewage, artificial lighting. Do these conditions meet the requirements for setting up a dental office?

**The correct answer:** The dental office is organised in a spacious, well-lit room equipped with forced ventilation and sewerage.

7. The floor in the dental office is covered with artistic parquet, what else is needed to be able to work in the dental office?

The correct answer: If the floor of the dental office is covered with artistic parquet, there should be a rubber mat under the feet of the dentist.

8. Is it possible to prepare amalgam in a dental office without a fume hood?

**Correct answer:** It is not possible to prepare amalgam in the dental office in the absence of a fume hood, there must be a suitable room equipped with a fume hood.

9. The walls of the dental office are painted bright red. Does this colour meet the requirements for the organisation of a dental office?

**The correct answer:** The walls of the dental office should be painted in light colours that do not tire.

## LIST OF REFERENCES

### Main literature

1. Stomatology: textbook: in 2 books. Book I / M.M. Rozhko, Z.B. Popovych, V.D. Kuroiedova et al.: edited by M.M. Rozhko. – Kyiv: AUS Medicine Publishing, 2020. – 792 p.: color edition.
2. Periodontal and Oral Mucosa Diseases: textbook. Vol. 2 / A.V. Borsenko, L.V. Lynovytska, O.F. Nesyn et al.; edited by A.V. Borysenko. - Kyiv: AUS Medicine Publishing, 2018. – 624 p.; color edition.
3. Stomatology: textbook: in 2 books. Book 2 / M.M. Rozhko, I.I. Kyrylenko, O. H. Denysenko et al.; edited by M. M. Rozhko. – Kyiv: AUS Medicine Publishing, 2018. – 960 p.; color edition.

### Additional literature

1. Esthetic Dentistry: A Clinical Approach to Techniques and Materials 3rd Edition by Kenneth W. Aschheim. Publisher: Mosby; 3rd edition, 2014. – 600 p.
2. Esthetic and Restorative Dentistry: Material Selection and Technique 3rd Edition by Douglas A Terry, Willi Geller. Publisher: Quintessence Publishing Co Inc.; 3rd edition, 2017. – 776 p.
3. Dental Composite Materials for Direct Restorations Softcover reprint of the original 1st ed. by Vesna Miletic. Publisher: Springer; 1st edition, 2018. – 327 p.
4. Posterior Direct Restorations 1st Edition by Salvatore Scolavino, Gaetano Paolone. Publisher: Quintessence Pub Co; 1st edition, 2021. – 264 p.

5. Smile Design Integrating Esthetics and Function Essentials of Esthetic Dentistry Volume Two by Jonathan B. Levine. Elsevier Health Sciences, 2015. – 240 p.
6. Cohen's Pathways of the Pulp 12th Edition by Louis H. Berman, Kenneth M. Hargreaves. Publisher: Elsevier; 12th edition, 2020. –992 p.

## Lesson №2

### **TOPIC: Equipment of the dentist's workplace: universal dental units and chairs. Safety precautions. Ethics and deontology in dentistry. Iatrogenic diseases.**

**I. Topic relevance:** The performance of dental duties largely depends on the organisation of the workplace. The dentist's workplace is equipped with sophisticated equipment and apparatus that allows him or her to successfully solve the problems of diagnosing and treating diseases of the teeth, periodontal tissues and oral mucosa.

#### **II. Study goal:**

##### **2.1. Student has to know:**

- Know the basic equipment of a dental office;
- Know the basic hygiene requirements for a dental office;
- Know the classification of dental units and chairs;
- Know what the duties of an assistant are;
- Safety precautions in the organisation of work in dental offices;
- Safety precautions for a dentist - general practitioner.

##### **2.2 Be able to:**

- To be able to distinguish dental units by their feed;
- Be able to work with an assistant in four hands;
- Be able to distinguish iatrogenic disease in a patient;
- Follow all safety precautions in the dental office;
- Be able to communicate ethically with patients and listen to them.

#### **III. Content of the topic**

##### **Basic equipment**

Traditionally, all dental equipment in an office is divided into the main equipment, without which it is impossible to perform medical procedures, and auxiliary equipment, which is necessary for specific manipulations.

The dental unit is a key element of the dentist's workplace. It provides the dentist with the conditions necessary for the efficient and technological performance of the main types of dental treatment.

##### **Universal dental units**

A modern dental unit is a complex set of electrical, mechanical and hydraulic elements that convert external energy into the energy of dental instruments and is designed to provide the necessary conditions for dental treatment.

##### **Dental units can be classified:**

- 1) by the way they are located in the office:

- stationary (fixed to the floor of the office);
  - portable (in which the dental unit does not have a rigid connection to the chair);
- 2) special purpose:
- laser (for beam preparation);
  - for endodontic work;
  - for periodontal manipulations;
- 3) for professional hygiene:
- removal of dental plaque;
  - bleaching with soda under pressure;
- 4) electric: for the installation of electric micromotors (brush and brushless) and piezoelectric scalars.
- 5) by the number of staff:
- only for the doctor;
  - for the simultaneous work of a doctor and his/her assistant, i.e. the so-called "four-handed" principle.

According to modern views, ergonomic requirements are best met by the work of a general dentist with an assistant in a four-handed position with the patient lying horizontally, due to the reduction of unwanted movements of the working team and the reduction of the time required to perform almost all medical procedures.

Unlike a nurse, a doctor's assistant works directly in the oral cavity. Their duties include

- professional hygiene and cleaning of teeth before restoration;
- Participation in the identification of colour and shades;
- Assisting in the restoration of teeth;
- control over the cleanliness of the surgical field, evacuation of oral fluid and aerosols;
- operation of a polymerisation lamp and protection of personnel from polymerisation light;
- polishing of teeth undergoing restoration.

In addition, the assistant performs the usual duties of a dental nurse.

When choosing equipment, the main focus should be on the assistant's workplace, which will save the dentist from unnecessary movements. Access to handpieces and other dynamic instruments should be focused primarily on the assistant and only then on the doctor. The dentist's workstation should be to the right of the patient, and the assistant's workstation should be to the left.

It is also desirable that the positioning of the handpieces corresponds to the frequency of their use. For example, a turbine handpiece should be located closer to the doctor than a mechanical handpiece; a high-speed vacuum cleaner and a water/air gun should be located closer to the assistant than a saliva ejector. In

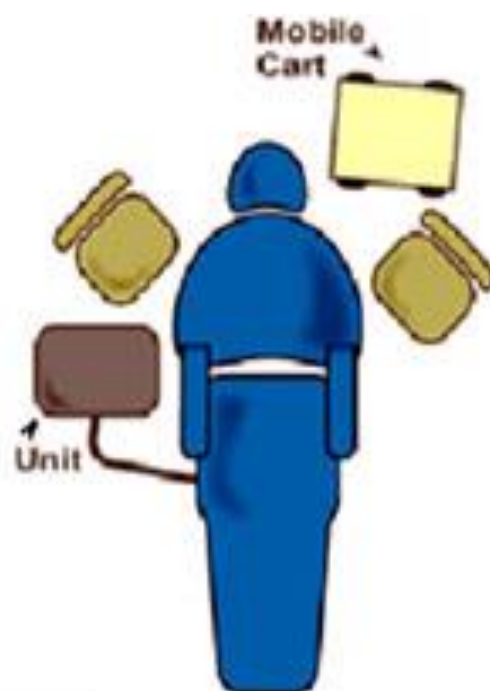
order to reduce movements, all instruments should be within the reach of the assistant for quick transfer to the doctor.

Most dental units used by dentists are equipped with a back table and a side table. Figures 1-4 show schematic examples of four common types of dental unit design.

### Installation with side feed

This design has been popular for decades. In fact, many dental schools use this type of unit, equipped with a fixed worktable, due to the fact that students usually have to work without an assistant. This style of setup requires the dentist to remove and replace handpieces, which in turn causes attention to shift from the working field to this procedure, forcing the dentist to turn his or her body to pick up the instrument and then refocus back to the working field. This can lead to physical fatigue and eye strain.

The side-feed design separates the assistant from the instruments and the ability to change handpieces or burs, which requires more unnecessary movements on the part of the clinician and therefore a loss of efficiency.



### Installation with rear feed

With this design, the dentist is forced to remove and replace the handpieces himself. This leads to constant turning, eye fatigue due to distraction from the working field. At the same time, there is often a moment when, in order to start working, it is necessary to transfer the handpiece from one hand to the other, the working hand. The units themselves are mounted in a fixed position, which does not allow adjusting it to change the working position to a more comfortable one for either the doctor or the assistant. The vacuum cleaner and water/air gun are fixed directly to the assistant's workspace. However, as the vacuum cleaner and gun are located at the back, this forces the assistant to bend over to reach them. When a movable table is used with a rear-feed unit, it can obstruct access to the sink, vacuum cleaner or water/air gun. For the assistant, this design will cause constant stress and fatigue, and limit their efficiency. However, despite ergonomic drawbacks,

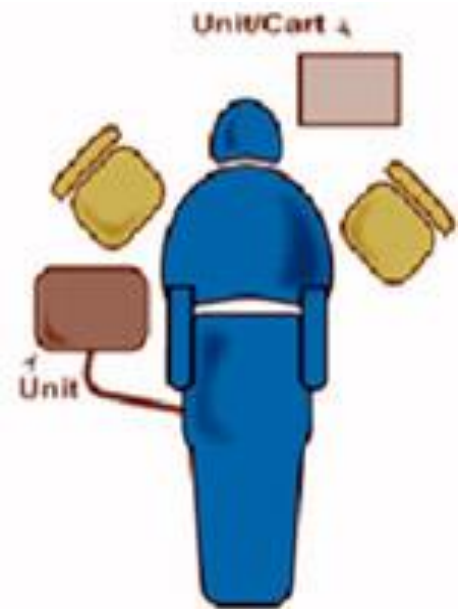



rear-feed units remain popular because they fit perfectly into the design of the room and hide the unit from the patient's view.

### **Split installation/tabletop**

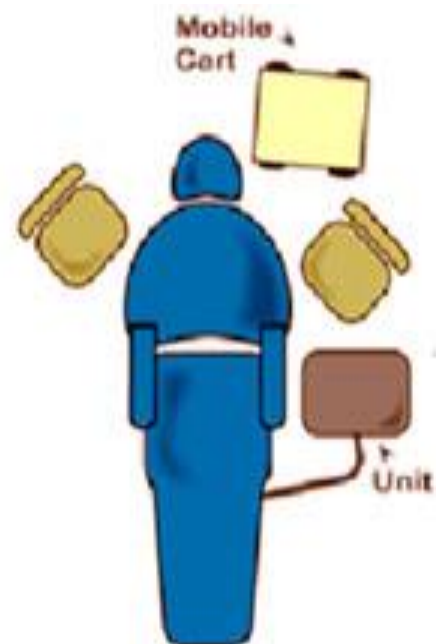
The concept of separating the unit and table separates the machine into the dentist's part and the assistant's movable table with vacuum and water/air gun. As with side-feed units, this design requires the dentist to change handpieces and makes them inaccessible to the assistant, thus reducing productivity. The assistant can only work with a vacuum cleaner and water/air gun that are integrated into the mobile table and is unable to hand over handpieces to the dentist and change burs. Very often, mobile tables of this design are not adapted for storage of auxiliary instruments and adequate space for storage of dental materials.



The split-level design of the unit can limit the assistant's workspace and forces them to place ancillary instruments in trays on a fixed table. This position requires additional movements to change the required instruments and materials stored in this way, and also opens the way for cross-infection of instruments stored in trays.

### **Transtorax type unit with chest table**

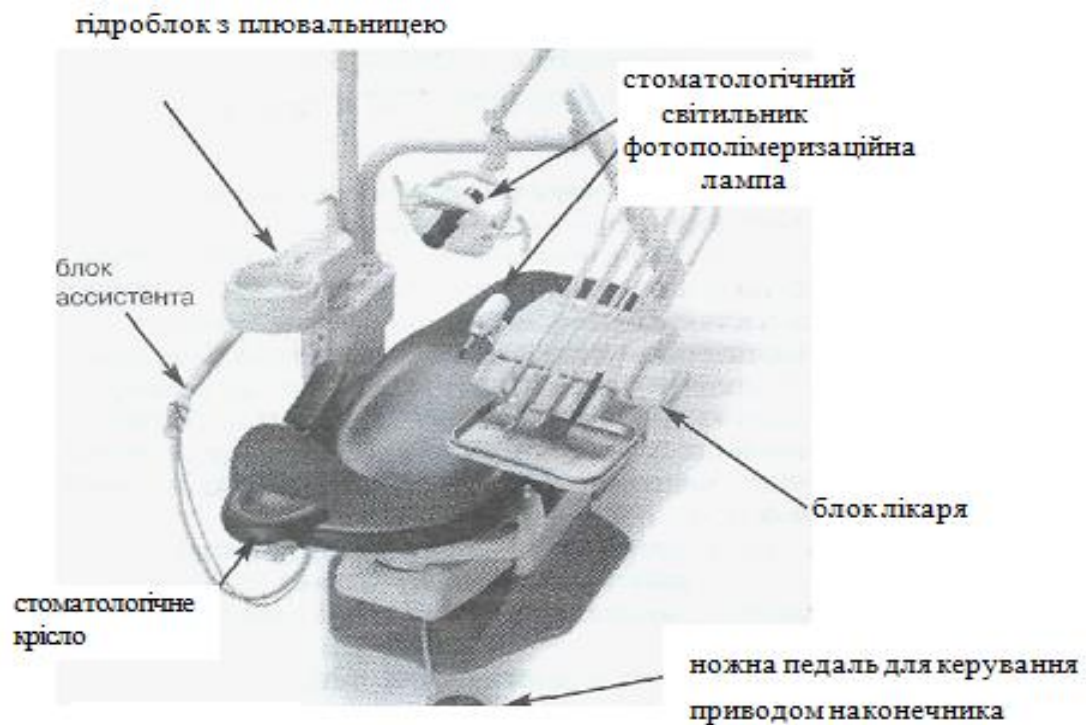
The chest table setup offers the best ergonomic compromise between the movements required and the time spent. With the table positioned on top of the patient's chest, the assistant can easily change handpieces and hand them over to the dentist, saving the dentist from having to switch their gaze from the working field. Repeatedly switching a close-focused gaze from a brightly lit working field to a dimmer space at a distant distance forces the doctor's eyes to adjust to changes in lighting and distance, which can lead to eye fatigue and subsequent headaches. And a mobile table with a mobile top that slides over the sitting assistant's lap serves as the main source of materials and instruments, conveniently located within the assistant's reach. There are no hoses to restrict the assistant's



mobility. This type of setup is specially designed for the most efficient four-handed operation.

**The universal dental unit is equipped with the following units:**

- electric and air drive for handpiece operation;
- modular dental unit has 2-3 hoses for micromotor and turbine handpieces;
- equipped with an air and water cooling system for the drills;
- connected to the water supply and sewerage system;
- pusher (water-air gun);
- equipped with an aspiration system (saliva ejector, vacuum cleaner), etc;
- a hydraulic unit with a spittoon;
- special dental lamp "Reflector";
- oil-free compressor;
- dental chair with automatic control.



In addition, the machines can be equipped with additional devices and equipment:

- system for monitoring the working field through the tip;
- built-in lamp for light curing materials with a wavelength of 450 - 500 nanometres;
- ultrasonic scaler for removal of dental plaque;
- diathermocoagulator;

- computer
- radiovisiograph;
- intraoral video camera;
- endodontic microscope.

### **Safety precautions in the organisation of work in dental offices**

Safety in dentistry is aimed at preventing injuries to patients and medical staff during treatment.

Each dental department (office) must have occupational health and safety (OHS) instructions in place.

Regular OHS briefings shall be conducted. Responsibility for compliance with the requirements of occupational health and safety lies with the chief physician and heads of departments.

Dental offices (therapeutic, surgical, orthopedic, children's, orthodontic) must have 14 m<sup>2</sup> of space for one dental chair and 7 m<sup>2</sup> for each additional chair. If the additional chair has a universal installation, the area is increased to 10 m<sup>2</sup>. In therapeutic and surgical rooms, no more than three chairs should be placed, and in surgical rooms - no more than two chairs with the mandatory separation of doctors' workplaces by opaque partitions up to 1.5 m high, a nurse's workplace should be equipped.

The walls of dental offices should be smooth, without cracks. All corners and joints of walls, ceilings and floors should be rounded, without cornices and decorations. The walls of surgical rooms and the sterilisation room shall be lined to a height of at least 1.8 m, in the operating room - with glazed tiles. Above the panel, the walls are painted with oil or water-based paints.

Adverse factors in the work of dental professionals are noise and vibration caused by the use of new dental equipment - high-speed drills and turbines, which generate a high noise level of 75-100 dBA. This leads to a decrease in hearing acuity and can cause deafness. It has been established that high noise levels lead not only to changes in the hearing organ, but also in the central nervous system, cardiovascular and other systems. *Правила техніки безпеки*

#### *1. Medical staff wearing special clothing and footwear:*

- Dental gown - protects clothing from contamination and the patient from contamination from clothing.
- Medical cap - protects the hair from damage during the movement of the dental unit and prevents during the movement of the dental unit and prevents clogging with turbine aerosol.
- Medical mask - protects the dentist from inhalation of microorganisms exhaled by the patient and turbine aerosol.
- Dental goggles - transparent goggles that cover the eyes, including the sides. They protect the eyes from aerosol, dust and blood drops. Instead, a dental shield can be used - a transparent plastic sheet that covers the entire face.

- Dental gloves. They differ from general medical gloves in that they have a special relief on the fingertips to prevent the instrument from slipping.
- Changeable footwear - with a smooth surface, easy to clean; wearing shoes only inside the medical facility.
- Compliance with the rules of work with flammable, strongly acting and poisonous substances.

2. *Compliance with the anti-epidemic regime.* A physician who strictly adheres to safety rules reduces the risk of harm to health not only to his/her own health, but also to the health of patients and colleagues.

### **The role of the doctor in the occurrence of iatrogenic diseases**

The term "iatrogeny" was coined in 1925 after the publication of the work of the German psychiatrist Bumke (O. S. E. Bumke) "The physician as a cause of mental disorders". Since then, specialists in various clinical professions have been actively researching this concept and trying to formulate its definition.

According to one of them, iatrogenic diseases (from the Greek iatros - doctor and gennao - to create, produce) are various pathological processes associated with preventive, diagnostic, therapeutic and resuscitation measures. Thus, it is any harm caused to a patient by a healthcare professional without malice.

#### **According to this definition, iatrogenies can be divided into eight groups:**

1. Iatrogenies associated with preventive measures - vaccinations and their complications, violation of the epidemiological regime - including infectious diseases caused by them.
2. Iatrogenies associated with diagnostic examinations due to unsafe research methods, technical errors, equipment failure.
3. Iatrogenies associated with medicinal, surgical and other treatment methods: intolerance, erroneous use, wrong choice of treatment method, anaesthesia hazards.
4. Iatrogenies associated with resuscitation (rib fracture during closed heart massage, etc.); complications caused by catheterisation and puncture of veins and arteries.
5. Iatrogenies associated with changes in the patient's psyche due to unethical actions of healthcare professionals: careless words in the presence of the patient; disrespectful attitude towards the patient.
6. Iatrogenies associated with shortcomings in the organisation of medical care and patient care - lack of beds in the hospital, long walks to the examination rooms.
7. Iatrogenies associated with inactivity or failure to provide medical care for one reason or another.
8. Iatrogenic pseudo-illnesses, including "computer pseudo-illnesses", associated with the establishment of an incorrect diagnosis and the conduct of inappropriate treatment. This can be observed during mass examinations, as a result of diagnostic errors in the equipment.

However, if we accept this classification and definition of iatrogenic diseases, then any pathology that occurs as a result of a doctor's action can be attributed to them. Therefore, it is not justified to expand the content of the concept of "iatrogenic diseases". After all, some actions of healthcare professionals that have negative consequences cannot be avoided, such as injuries during surgery.

On the other hand, complications caused by incorrect diagnosis and treatment fall into the category of medical errors or medical offences as failure to provide medical care.

The occurrence of iatrogenic diseases depends not only on the behaviour of the doctor, but also on the patient: his or her gender, age, emotionality, and intellectual development. Depending on the peculiarities of the psyche, the type of nervous activity, different patients react differently to the actions or some words of the doctor. For example, women are more likely to have iatrogenies.

Among age groups, adolescents, menopausal women, and older people are more likely to be affected. The public's awareness of diseases and the prevalence of diseases at a certain time play a major role in the occurrence of iatrogenic diseases. For example, at the beginning of the twentieth century, there were many people who considered themselves to have tuberculosis or syphilis. Today, people often "look for" cancer and HIV/AIDS.

The main method of treatment for iatrogenic diseases is psychotherapy, which can be supplemented with appropriate symptomatic and sedative treatment. In no case should you tell a patient that they do not have a disease and do not need treatment. You need to take an active part in their treatment. Sometimes it is necessary to involve a psychologist or psychiatrist in treatment.

#### **IV. Control questions for the class topic:**

1. What is the main equipment in a dental office?
2. Classification of dental units?
3. What are the duties of a doctor's assistant (assistant)?
4. What units are equipped with a universal dental unit?
5. What does the doctor's unit consist of?
6. What are the safety precautions for a dentist in a dental office?
7. What is the role of the doctor in the occurrence of iatrogenic diseases?
8. What groups of iatrogenic diseases do you know?

#### **V. Control test tasks and/or case tasks:**

1. According to the sanitary and hygienic standards, the area of a dental office for one dental chair should be at least:

- A. 14 m<sup>2</sup>;
- B. 7 m<sup>2</sup> ;
- C. 21 m<sup>2</sup>;
- D. 5 m<sup>2</sup> ;
- D. 18 m<sup>2</sup>.

**The correct answer is: A.**

2. According to the sanitary and hygienic standards, for each additional dental chair, an area of at least

- A. 14 m<sup>2</sup>;
- B. 7 m<sup>2</sup>;
- C. 21 m<sup>2</sup>;
- D. 5 m<sup>2</sup>;
- D. 18 m<sup>2</sup>.

**The correct answer is: B.**

3. According to sanitary and hygienic standards, the walls in a dental office should be covered:

- A. Textile wallpaper;
- B. Lime whitewash;
- C. Chalky whitewash;
- D. Water-based paints;
- E. There is no correct answer.

**The correct answer is: C.**

4. According to sanitary and hygienic standards, the walls in a dental office should be covered:

- A. Oil paints;
- B. Lime whitewash;
- C. Chalky whitewash;
- D. Textile wallpaper;
- E. No correct answer.

**The correct answer is: A.**

5. What equipment is installed in the dental office:

- A. Steam autoclave;
- B. Operating table;
- C. Ceramic oven;
- D. Dental unit;
- E. No correct answer?

**The correct answer is: C.**

6. Diagnostic equipment of the dental office:

- A. Welcome test;
- B. Amalgam mixer;
- C. Compressor;
- D. Amalgam tracer;
- Д. Radiovisiograph.

**The correct answer is: D.**

## LIST OF REFERENCES

### Main literature

1. Stomatology: textbook: in 2 books. Book I / M.M. Rozhko, Z.B. Popovych, V.D. Kuroiedova et al.: edited by M.M. Rozhko. – Kyiv: AUS Medicine Publishing, 2020. – 792 p.: color edition.
2. Periodontal and Oral Mucosa Diseases: textbook. Vol. 2 / A.V. Borsenko, L.V. Lynovytska, O.F. Nesyn et al.; edited by A.V. Borysenko. - Kyiv: AUS Medicine Publishing, 2018. – 624 p.; color edition.
3. Stomatology: textbook: in 2 books. Book 2 / M.M. Rozhko, I.I. Kyrylenko, O. H. Denysenko et al.; edited by M. M. Rozhko. – Kyiv: AUS Medicine Publishing, 2018. – 960 p.; color edition.

### **Additional literature**

1. Esthetic Dentistry: A Clinical Approach to Techniques and Materials 3rd Edition by Kenneth W. Aschheim. Publisher: Mosby; 3rd edition, 2014. – 600 p.
2. Esthetic and Restorative Dentistry: Material Selection and Technique 3rd Edition by Douglas A Terry, Willi Geller. Publisher: Quintessence Publishing Co Inc.; 3rd edition, 2017. – 776 p.
3. Dental Composite Materials for Direct Restorations Softcover reprint of the original 1st ed. by Vesna Miletic. Publisher: Springer; 1st edition, 2018. – 327 p.
4. Posterior Direct Restorations 1st Edition by Salvatore Scolavino, Gaetano Paolone. Publisher: Quintessence Pub Co; 1st edition, 2021. – 264 p.
5. Smile Design Integrating Esthetics and Function Essentials of Esthetic Dentistry Volume Two by Jonathan B. Levine. Elsevier Health Sciences, 2015. – 240 p.
6. Cohen's Pathways of the Pulp 12th Edition by Louis H. Berman, Kenneth M. Hargreaves. Publisher: Elsevier; 12th edition, 2020. –992 p.

### Lesson № 3

#### **TOPIC: Scheme of examination of a dental patient.**

#### **Subjective examination: complaints, medical and life history.**

#### **Characteristics of pain syndrome in various dental lesions**

**I. Topic relevance:** The correct diagnosis of the disease can be made only on the basis of a comprehensive examination of the patient. Therefore, mastering a set of methods for examining patients with oral diseases is the basis for establishing the correct diagnosis and subsequent individualised and effective treatment.

As in all branches of clinical medicine, the examination of a patient in therapeutic dentistry is divided into two parts:

- 1) questioning (anamnesis), during which the patient provides the doctor with the information necessary for diagnosis about the disease and himself/herself;
- 2) objective examination (examination, palpation, percussion, etc.) with the use of basic physical and additional (laboratory, instrumental) research methods.

#### **II. Study goal:**

##### **2.1. Student has to know:**

- Know the difference between subjective and objective examination of a dental patient;
- Know how to properly interview a patient;
- Know what a patient's medical history is;
- Know what a patient's life history is;
- Know how to properly collect anamnesis of a dental patient;
- Know the duration of pain of a particular dental disease;
- Know how to identify disorders of the state and functions of the salivary glands.

##### **2.2 Be able to:**

- Be able to distinguish between subjective and objective examination of a dental patient;
- Be able to analyse patient complaints;
- Assess the duration of the patient's pain;
- Be able to detail other patient complaints (bleeding gums, tooth mobility, swelling, etc.);
- Be able to assess the condition and function of the patient's salivary glands.

#### **III. Content of the topic**



Diagnosis and treatment planning are common elements in all disciplines of dentistry. In evaluating a patient, the clinician evaluates information from the history and clinical findings; this information may suggest a clinical diagnosis. The purpose of a diagnosis is to determine what problem the patient is having, and why the patient is having that problem. Ultimately, this will directly relate to what treatment, if any, will be necessary.

**The process of making a diagnosis can be divided into five stages:**

- The patient tells the clinician why the patient is seeking advice.
- The clinician questions the patient about the symptoms and history that led to the visit.
- The clinician performs objective clinical tests.
- The clinician correlates the objective findings with the subjective details and creates a tentative differential diagnosis.
- The clinician formulates a definitive diagnosis. This information is accumulated by means of an organized and systematic approach that requires considerable clinical judgment. Questioning, listening, test-ing, interpreting and finally answering the ultimate question of why will lead to an accurate diagnosis and in turn result in a more successful treatment plan. An initial historical profile should identify the patient; establish the chief com-plaint; reflect the dental history; document drug allergies or other adverse drug effects; identify medications, vitamins, dietary supplements, or special diets; and provide a record of past and present illness, major hospitalizations, and a review of major organ systems. The historical profile shall be reviewed with the patient at each subsequent appointment and any new information obtained should be documented in the progress notes.

*Patient Identification:* The basic biographical data should include the patient's name, age, sex, ethnic extraction, marital status, occupation and place of residence. The date of the evaluation also must be recorded. Not only are these items essential for patient identification but also they may provide invaluable background information for the differential diagnosis of certain conditions, or identify patients in a high — risk category for a variety of diseases.

*CHIEF COMPLAINT.* Upon arrival for a dental consultation, the patient should complete a thorough registration that includes information pertaining to medical and dental history. This should be signed and dated by the patient, as well as initialed by the clinician as verification that all of the submitted information has been reviewed. The clinician may find dental pathosis, but it may not be the pathologic condition that mediates the patient's chief complaint. Investigating these complaints may indicate that the patient's concerns are secondary to a medical condition or possibly a result of recent dental treatment.

Occasionally, the chief complaint is simply that another clinician correctly or incorrectly advised the patient that he or she had a dental problem, with the patient not necessarily having any symptoms. There-fore, the clinician must pay close attention to the actual expressed complaint; determine the chronology of

events that led up to this complaint and question the patient as to any other pertinent issues, including medical and dental history.

For future reference and in order to ascertain a correct diagnosis, the patient's chief complaint should be properly documented, using the patient's own words.

*Character of the Symptoms:* The most common complaint causing a person to seek the services of a healthcare provider is pain.

Determine its character. Is it sharp or dull? Is it pain or is it merely discomfort? Does it appear suddenly and disappear quickly, or does it gradually increase in intensity and subside slowly? A lesion should be inspected. Is it white, red, pigmented, ulcerative, vesicular, bullous, exophytic, or a combination of these various characteristics? Admittedly, this observation is part of the examination, not the history, but there are at least two good reasons for doing it at this point in time. First, it establishes the dentist's concern for the patient's problems, and second, it may suggest additional questions to be asked during the history-taking process.

**MEDICAL HISTORY.** A fundamental principle in establishing a diagnosis is gathering information relevant to the disease process. The clinician must complete the database before beginning the interpretive and decision-making process. The database begins with the patient's medical history. Obtaining a comprehensive written medical history is mandatory and should precede the examination and treatment of all patients.

The medical history provides information regarding the patient's overall health and susceptibility to disease and indicates the potential for adverse reactions to treatment procedures. Information regarding current medications, allergies, and diseases, as well as the patient's emotional and psychologic status, can be assessed as it relates to the clinical problem. This information is important in diagnosis because the patient may have a systemic disease with oral manifestations. Moreover, a systemic disease may present initially as an oral lesion.

The clinician is responsible for taking a proper medical history from every patient who presents for treatment. It is imperative that vital signs be gathered at each treatment visit for any patient with a history of major medical problems. The temperature of patients presenting with subjective fever or any signs or symptoms of a dental infection should be taken.

The clinician should evaluate a patient's response to the health questionnaire from two perspectives:

(1) those medical conditions and current medications that will necessitate altering the manner in which dental care will be provided and,

(2) those medical conditions that may have oral manifestations or mimic dental pathosis. Patients with the following medical conditions may require either a modification in the manner in which the dental care will be delivered or a modification in the dental treatment plan: cardiovascular, gastrointestinal,

haematologic, neurolog-ic and other diseases. Several medical conditions have oral manifestations, which must be carefully considered when attempting to arrive at an accurate dental diagnosis.

Many of the oral soft tissue changes that occur are more related to the medications used to treat the medical condition than the medical condition itself. If at the completion of a thorough dental examination, the subjective, objective, clinical testing, and radiographic findings do not result in a diagnosis with an obvious dental etiology, then consideration must be given that an existing medical problem could be the true etiology. In such instances a consultation with the patient's physician is always appropriate.

**DENTAL HISTORY.** The taking of a dental history allows the clinician to build rapport with the patient and is often more important than the examination and testing proce-dures. The dental history almost always contributes to the establishment of a diagnosis. The dental history should include the chief complaint and a history of the present illness if the patient has signs and/or symptoms of disease. The clinician should question the patient regarding the inception, location, type, frequency, intensity, duration, and cause of any pain or discomfort to develop a differential and definitive diagnosis. The process of information gathering may provide the clinician with a tentative diagnosis and guide the examination and testing process.

*Pain* is a complex physiologic and psychologic phenomenon and often cannot be used to differentiate endodontic problems from non-endodontic pathosis. Identifying the source of a patient's pain may be routine or complex. Inflammation and pain in the dental pulp are often difficult to localize and may be referred to a tooth in the opposing quadrant or to the preauricular region. A history of previous pain from a symptomatic tooth is also an important finding.

The chronology of events that lead up to the chief complaint is recorded as the dental history. This information will help guide the clinician as to which diagnostic tests are to be performed. The history should include any past and present symp-toms, as well as any procedures or trauma that might have evoked the chief com-plaint.

*Proper documentation is imperative.* It may be helpful to use a premade form to record the pertinent information obtained during the dental history interview and diagnostic examination. The dialogue between the patient and the clinician should encompass all of the details pertinent to the events that led up to the chief complaint. The conversation should be directed by the clinician in order to produce a clear and concise narrative that chronologically depicts all of the necessary information about the patient's symptoms and the development of these symptoms. After starting the interview and determining the nature of the chief complaint, the clinician continues the conversation by documenting the sequence of events that promulgated the request for an evaluation.

The dental history is divided into *five basic directions of questioning: localization, commencement, intensity, provocation and the duration of pain.*

With the dental history interview complete, the clinician has a better understanding of the patient's chief complaint and can concentrate on making an objective diagnostic evaluation, although the subjective (and artistic) phase of making a diagnosis is not yet complete and will continue after the more objective testing and scientific phase of the investigatory process.

**Anamnesis Morbi.** A number of questions should be considered. How long has the condition associated with the patient's chief complaint been present? Has the problem developed slowly or rapidly? Some conditions have a sudden onset, but others begin slowly and insidiously. Have the symptoms become worse or better? Are they better at times and worse at other times? The oral healthcare provider should document a history of allergic drug reactions and other adverse drug effects and investigate whether drugs or medications are being taken. Many patients habitually take drugs for minor complaints, a practice that should be documented carefully. Patients often do not recognize nonprescription medications as drugs and, therefore, do not mention the habitual use of aspirin, decongestants, antihistamines, vitamins, and many other over-the-counter medications. Inquire about dietary supplements or special diets the patient may be on. Immunosuppressant therapy may place a patient in the high-risk category for many viral, fungal, and bacterial infections and de novo malignancies.

**Anamnesis Vitae. Family History.** The dentist should inquire about the patient's general health, as perceived by the patient and summarize past and present medical conditions. A clinician must record any hereditary or developmental abnormalities.

Previous operations, injuries, accidents and hospitalizations should be recorded, as well as comments about anaesthesia, drug reactions, blood transfusions, or transmissible diseases. In addition to hereditary conditions, acquired infectious diseases may be transmitted from one family member to another, some requiring only casual contact, while others are transmitted only through repeated, intimate encounters (sometimes associated with child abuse).

*The personal habits* of patients may reveal important clues to diagnosis. Excessive use of tobacco and alcohol may produce symptoms whose significance is lost without knowledge of a patient's smoking and drinking habits. Information about educational, social, religious, and economic background and feelings of achievement or frustration can provide important insight into understanding the patient as a person.

**Review of Organ Systems.** The chief complaint and the medical, family, and social histories of the patient should guide the clinician to investigate areas of special concern. All signs and symptoms related to specific organ systems should be recorded. The status of organ systems may suggest the presence of concomitant systemic conditions, contribute to the diagnostic process and influence projected treatment protocols and prognosis.

#### **IV. Control questions for the class topic:**

1. What is the subjective questioning of a dental patient?

2. How to properly interview a dental patient?
3. What should you pay attention to when interviewing a patient?
4. How to properly detail patient complaints?
5. What is the difference between medical history and life history?
6. What is the scheme for collecting a dental patient's life history?
7. What are pre-existing and concomitant diseases?
8. Do bad habits affect the patient's oral health?
9. What is pain syndrome?
10. Classification of pain syndrome?
11. General principles of treatment of pain syndrome?

**V. Control test tasks and/or case tasks:**

1. The set of information about the patient and the development of the disease that the doctor receives during the interview of the patient or the patient's relatives is:

- A. The patient's complaints;
- B. Anamnesis of the patient;
- C. Duration of pain;
- D. Pain syndrome;
- D. General examination.

**The correct answer is: B.**

2. What does NOT apply to the collection of a patient's medical history:

- A. Past illnesses;
- B. Bad habits;
- C. Family life;
- D. Examination of the oral cavity;
- D. Heredity .

**The correct answer is: C.**

3. Bad habits include:

- A. Smoking ;
- B. Excessive consumption of alcohol;
- C. Abuse of spicy food;
- D. Abuse of sweets;
- E. All answers are correct.

**The correct answer is: D.**

4. On the basis of what, from the very beginning, it is possible to predict the correct preliminary diagnosis of the disease, which must be confirmed by other methods of examination?

**Correct answer:** On the basis of all complaints, medical history and the patient's life. The final diagnosis is established after supplementing the patient's questioning with objective data from clinical and laboratory tests.

5. What is the classification of pain syndromes?

**Correct answer:** There are 3 main types of pain syndromes: somatogenic (nociceptive pain); neurogenic (neuropathic pain); psychogenic (psychogenic pain).

6. Pain that occurs independently of somatic, visceral or neural damage and is largely determined by psychological and social factors is:

- A. Neuropathic pain;
- B. Psychogenic pain;
- C. Compressor pain;
- D. Nociceptive pain.

The correct answer is: B.

## LIST OF REFERENCES

### Main literature

1. Stomatology: textbook: in 2 books. Book I / M.M. Rozhko, Z.B. Popovych, V.D. Kuroiedova et al.: edited by M.M. Rozhko. – Kyiv: AUS Medicine Publishing, 2020. – 792 p.: color edition.
2. Periodontal and Oral Mucosa Diseases: textbook. Vol. 2 / A.V. Borsenko, L.V. Lynovytska, O.F. Nesyn et al.; edited by A.V. Borysenko. - Kyiv: AUS Medicine Publishing, 2018. – 624 p.; color edition.
3. Stomatology: textbook: in 2 books. Book 2 / M.M. Rozhko, I.I. Kyrylenko, O. H. Denysenko et al.; edited by M. M. Rozhko. – Kyiv: AUS Medicine Publishing, 2018. – 960 p.; color edition.

### Additional literature

1. Esthetic Dentistry: A Clinical Approach to Techniques and Materials 3rd Edition by Kenneth W. Aschheim. Publisher: Mosby; 3rd edition, 2014. – 600 p.
2. Esthetic and Restorative Dentistry: Material Selection and Technique 3rd Edition by Douglas A Terry, Willi Geller. Publisher: Quintessence Publishing Co Inc.; 3rd edition, 2017. – 776 p.
3. Dental Composite Materials for Direct Restorations Softcover reprint of the original 1st ed. by Vesna Miletic. Publisher: Springer; 1st edition, 2018. – 327 p.
4. Posterior Direct Restorations 1st Edition by Salvatore Scolavino, Gaetano Paolone. Publisher: Quintessence Pub Co; 1st edition, 2021. – 264 p.
5. Smile Design Integrating Esthetics and Function Essentials of Esthetic Dentistry Volume Two by Jonathan B. Levine. Elsevier Health Sciences, 2015. – 240 p.
6. Cohen's Pathways of the Pulp 12th Edition by Louis H. Berman, Kenneth M. Hargreaves. Publisher: Elsevier; 12th edition, 2020. –992 p.

## Lesson № 4

**TOPIC: Clinical examination methods, their importance for the diagnosis of diseases of the oral cavity: examination (external, of the patient's face, vestibule, oral cavity, dentition). Examination of the disease site**

**I. Topic relevance:** Objective examination includes examination, examination of the oral cavity and, if necessary, the entire body of the patient with the use of various diagnostic techniques (palpation, percussion, hardware and laboratory methods of examination). Its purpose is to identify and detail pathological changes in the teeth, oral cavity and maxillofacial area.

### **II. Study goal:**

#### ***2.1. Student has to know:***

- Know the difference between subjective and objective examination of a dental patient;
- Know what a patient examination consists of;
- Know what a general examination of a patient is;
- Know what types of patient positions exist;
- Know what an oral examination consists of;
- Know what instruments are needed for dental examination;
- Know what functional completeness of fillings is and what clinical tests are used to assess it.

#### ***2.2 Be able to:***

- Be able to distinguish between subjective and objective examination of a dental patient;
- Analyse the general condition of the patient;
- Assess the patient's skin and facial shape;
- Be able to conduct an examination of the oral cavity of a dental patient;
- Be able to use a mirror and probe when examining the patient's teeth.
- To be able to determine the functional integrity of fillings using clinical tests;
- Be able to perform palpation and percussion and distinguish between painful reactions to them.

### **III. Content of the topic**

**EXTRAORAL EXAMINATION.** Basic diagnostic protocol suggests that a clinician observe patients as they enter the operatory. Signs of physical limitations may be present, as well as signs of facial asymmetries that result from facial swelling. Visual and palpation examinations of the face and neck are

warranted to determine whether swelling is present. Palpation allows the clinician to determine whether the swelling is localized or diffuse, firm or fluctuant.

These latter findings will play a significant role in determining the appropriate treatment. Extraoral facial swelling of odontogenic origin typically is the result of endodontic etiology because diffuse facial swelling resulting from a periodontal abscess is rare. Swellings of non-odontogenic origin must always be considered in the differential diagnosis especially if an obvious dental etiology is not found. Sinus tracts of odontogenic origin may also open through the skin of the face.

These openings in the skin will generally close once the offending tooth is treated and healing occurs. A scar is more likely to be visible on the skin surface in the area of the sinus tract stoma than on the oral mucosal tissues. The term fistula is often inappropriately used to describe this type of drainage. The fistula, by definition, is actually an abnormal communication between two internal organs or a pathway between two epithelium-lined surfaces.

*The extraoral examination* may give the clinician insight as to which intraoral areas may need a more focused evaluation. Extraoral swelling, localized lymphadenopathy, or an extraoral sinus tract should provoke a more detailed assessment of related and proximal intraoral structures. Palpation of the cervical and submandibular lymph nodes is an integral part of the examination protocol. If the nodes are found to be firm and tender along with facial swelling and an elevated temperature, there is a high probability that an infection is present.

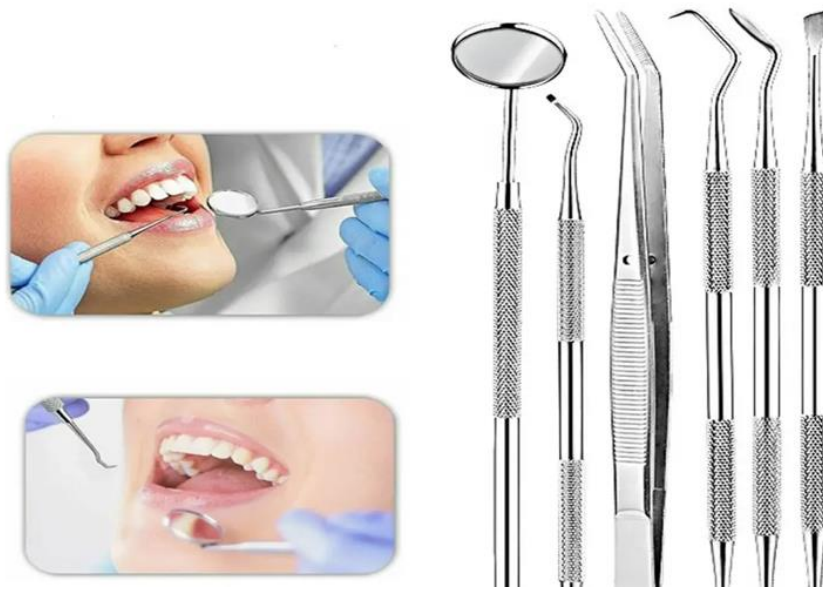**INTRAORAL EXAMINATION.** Visual inspection of the soft tissues should include an assessment of colour, contour, and consistency.

Localized redness, edema, swelling, or a sinus tract can indicate inflammatory disease.

Examination of the hard structures may reveal clinical findings such as developmental defects, caries, abrasion, attrition, erosion, defective restorations, fractured cusps, cracked teeth, and tooth discoloration. Intraoral swellings should be visualized and palpated to determine whether they are diffuse or localized and whether they are firm or fluctuant.

These swellings may be present in the attached gingiva, alveolar mucosa, mucobuccal fold, palate, or sublingual tissues. Other testing methods are required to determine whether the etiology is endodontic, periodontics, or a combination of these two or whether it is of a nonodontogenic origin.





**EXAMINATION OF THE ORAL CAVITY.** Dentists should have a special interest in the physical examination of the oral cavity since the mouth is the anatomical area of the body for which they are the ultimate authority. Therefore, the organization of this section is more detailed and provides greater emphasis on possible findings and interpretation of data.

Basic instrumentation for the oral examination includes a *good light source, a mouth mirror, an explorer, a periodontal probe, dry gauze sponges, and an air syringe.* The need for specialized instrumentation and additional diagnostic procedures will vary with the findings and differential diagnoses developed.

*Examine the Teeth.* Note the number, size, shape and colour of teeth, There are such terminology employed in the literature around caries diagnosis (which should imply a human professional summation of all available data), lesion detection (which implies some objective method of determining whether or not disease is pres- and lesion assessment (which aims to characterise or monitor a lesion, once it has been detected).

*Direct Dentin Stimulation.* This is probably the most accurate and, in many cases, the best pulp vitality test.

Exposed dentin may be scratched with an explorer; however, the absence of a response is not as indicative as the presence of a response. Caries are probed deeply with an explorer to non-cariou dentin, sudden, sharp sensation indicates that the pulp contains vital tissue.

*Visual-tactile examination.* Visual changes of the dental structure resulting from the demineralization process can be visually observed during caries development, such as an increase in opacity and roughness of the enamel.

Visual examination has been widely used in dental clinics for detecting carious lesions on all surfaces. This method is based on the use of a dental mirror,

a sharp probe and a 3-in-1 syringe and requires good lighting and a clean/dry tooth surface.

The examination is based primarily on subjective interpretation of surface characteristics, such as integrity, texture, translucency/opacity, location and colour. However, tactile examination of dental caries has been criticized because of the possibility of transferring cariogenic microorganisms from one site to another, leading to the fear of further spread of the disease in the same oral cavity. More-over, use of an explorer can cause irreversible damages to the iatrogenic and demineralized tooth structure.

Visual and tactile methods typically go hand in hand, because most dentists use dental probes and other tools to examine teeth during the clinical examination. The first visual indication of caries in enamel is generally small white lesions where demineralization has occurred under the dental plaque. However, greyish lesions also can be seen at the level of dentin, and in more advanced stages, caries can appear as open cavities on enamel, dentin layers, or all the way to the pulp.

Other tools used in visual-tactile examination may include magnifying devices to look at teeth, or orthodontic elastic separators to separate teeth over the course of 2 to 3 days for a closer look between teeth prone to caries lesions. Fibre-optic transillumination is also sometimes used. This is a method by which visible light is emitted through the tooth using an intense light source. If the transmitted light reveals a shadow, this may indicate a carious lesion. Vision aids: Combination visual inspection of lesions with binocular magnification, radiographs and probes.

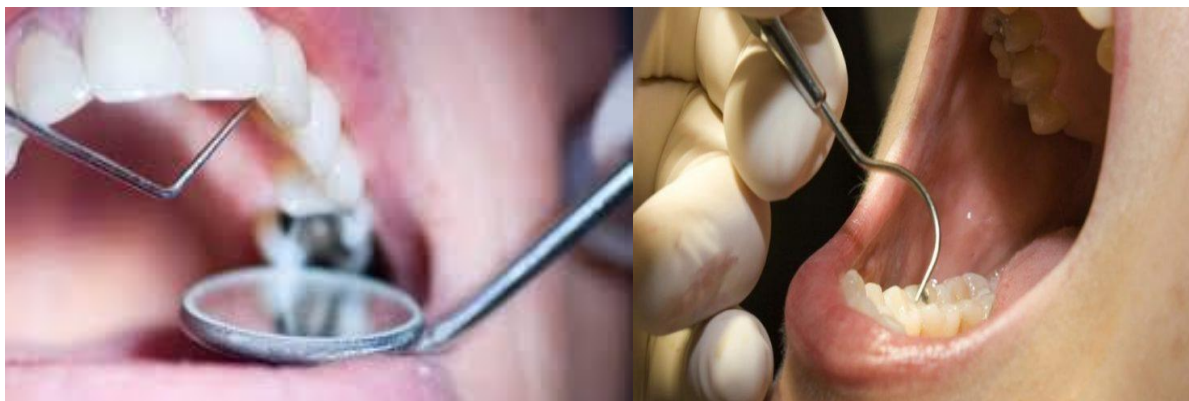
All combinations shared the low sensitivity whilst the combination of bitewing radiographs and visual inspection significantly improved the sensitivity. The traditional method of detecting caries signs is by visual inspection of dental surfaces, with the aid of a bright light and dental mirror if necessary to see teeth from all angles. Reflecting light onto the mouth mirror also can be done to search for dark shadows that could indicate dentin lesions. The coronal carious lesion starts as a clinically undetectable subsurface demineralization. With further progression, it will (eventually) become clinically detectable, and then can be classified according to type, localization, size, depth, and shape.

The visual method, a combination of light, mirror, and the probe for detailed examination of every tooth surface, is by far the most commonly applied method in general practice worldwide.

*Probing.* The probe didn't add to the sensitivity of vision, and even decreased the sensitivity of visual diagnosis (0.6 versus 0.65). In an «in vitro» validation study of the sharp probe to detect fissure caries, sensitivities were found for caries stages at initial and deep stages.

Clinical examination was quite variable between practitioners owing to the size and shape of the explorer tip, the force applied, and the judgment of the examiner. This examination uses a fine, pointed probe to test for surface defects in the enamel. If the probe remains stuck when probing the fissures, this is a sure

sign of dentin softening. While the use of a dental probe continues to be controversial, it is extremely helpful when used correctly and judiciously.



A *dental probe* can be used to remove plaque that may be covering, and when the blunt side of the probe is used, it can help remove bio-film to check for signs of demineralization and to assess the surface roughness of a lesion. Studies show that gentle probing does not disrupt the surface integrity of non-cavitated lesions, while vigorous poking can cause irreversible damage to the surface of a developing lesion.

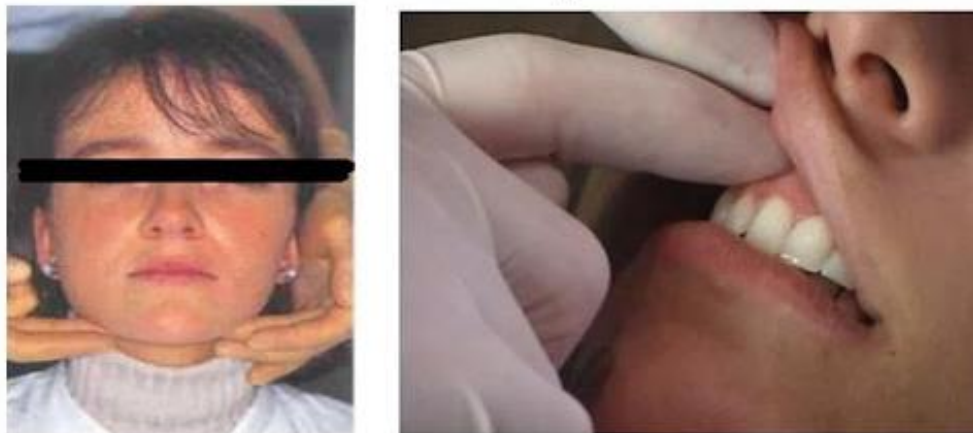
A probe is unnecessary if visual inspection detects a cavity. During a visual-tactile examination, the dentist will also use a syringe or drying tool to blast air on to the tooth, which makes it easier to see some lesions. If in doubt, or to confirm the visual assessment, the probe can be used gently across a tooth surface to confirm the presence of a cavity apparently confined to the enamel.

This is achieved by sliding the ball end along the suspect pit or fissure and a limited discontinuity is detected if the ball drops into the surface of the enamel cavity/discontinuity. The same dragging motion used to clean the fissure using a blunt probe conveys to the dentist information about the surface roughness around the walls of lesions and an idea if the base is soft or hard. Further results had showed arrested lesions became smooth and lost surface frostiness especially with regard to root caries. In cavitated lesions, the information, which could be gained, is enormous.

The highest increase in the tools performances was noticed for the probe in cavitated lesions. Even for non-cavitated, the probe is still accepted for the removal of plaque from the fissures that might obscure cavities and to improve the access of direct vision. Care must be applied whilst using the probe not to produce damage by disrupting the continuity of the surface. Probing of root caries lesions with a sharp explorer using controlled, modest pressure, however, may create surface defects that prevent complete remineralization of the lesion.

The technique of temporary elective tooth separation as an aid to diagnosis of caries in proximal smooth surfaces is now regaining popularity, albeit with less traumatic methods that seem acceptable to most patients and dentists. This

method permits a more definite assessment of whether there is a detectable proximal enamel lesion by using radiography.



*Tooth separation* can be used as a method for examination of a suspicious area on the approximal surface. With this technique an orthodontic elastic separator can be applied for 2-3 days around the contact areas of approximal surfaces, facilitating the clinical and probing assessments. However, this method might create some discomfort and requires an extra visit. Studies have shown that tooth separation have detected more non-cavitated enamel lesions than visual-tactile examination without separation or bitewing examination.

The presence of cavitation (loss of surface integrity) associated with a root caries lesion does not necessarily imply lesion activity. Non-cavitated (early) root caries lesions almost universally are considered to be active. A cavitated lesion, however, may be either active or arrested. Lesion activity has been linked to lesion depth, but this clinical observation has not been verified. The texture of a root caries lesion also has been linked to lesion activity.

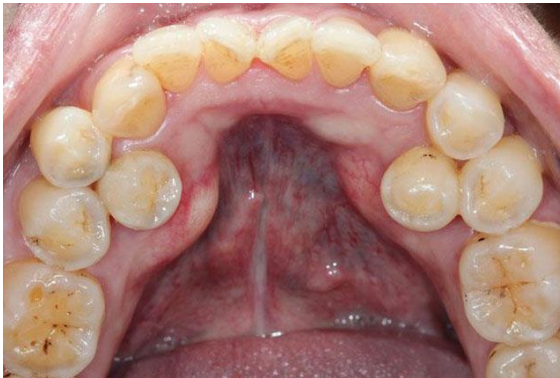Active lesions have been described as soft or leathery compared to arrested lesions that have a hard texture. There is supporting laboratory evidence from a study that used microbiological indicators for lesion activity that «soft» or «leathery» lesions on root surfaces are more heavily infected with bacteria than are «hard» root surfaces.

Given the paucity and generally low level of the scientific evidence, the ICDAS Coordinating Committee, recommends that the following clinical criteria be used for the detection and classification of root caries:

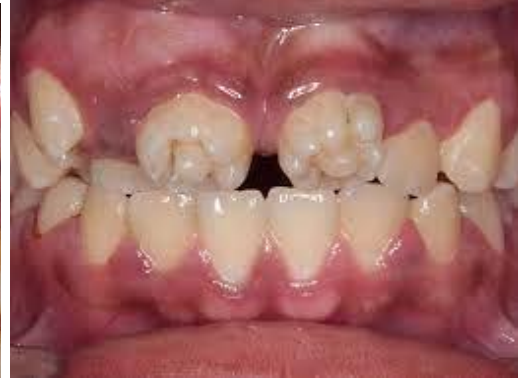1. Colour (light/dark brown, black);
2. Texture (smooth, rough);
- 3 Appearance (shiny or glossy, matte or non-glossy);
4. Perception on gentle probing (soft, leathery, hard).
5. Cavitation (loss of anatomical contour).

Additionally, the outline of the lesion and its location on the root surface are useful in detecting root caries lesions. Root caries appears as a distinct, clearly demarcated circular or linear discolouration at the cemento-enamel junction (CEJ) or wholly on the root surface. The colour of the lesion can also be used to make

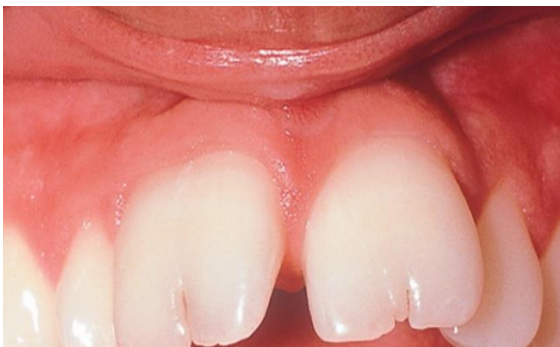the distinction between arrested and active, with arrested lesions acquiring internal brown pigmentation and surface stain, while active lesions retain their white appearance.



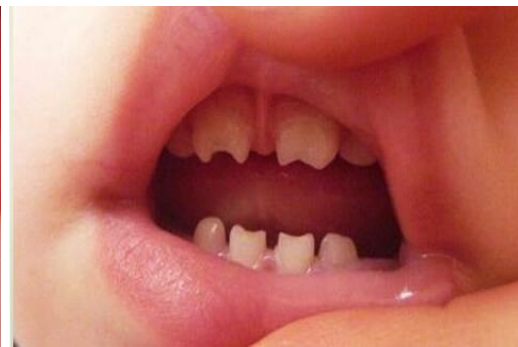1. *Extra teeth.*



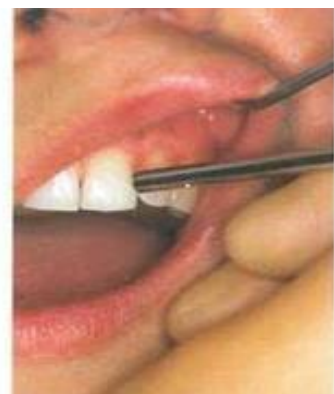
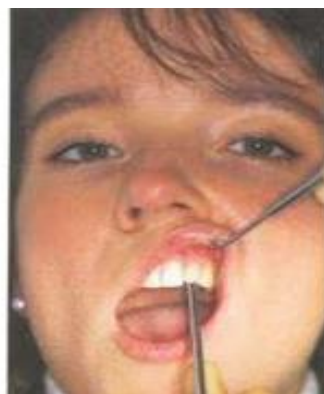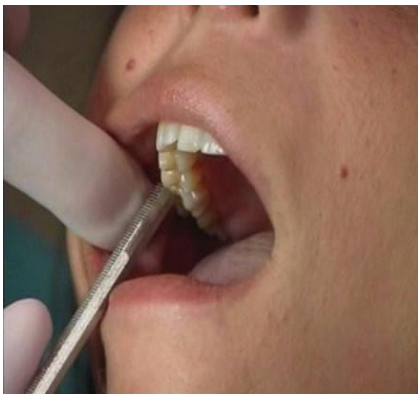2. *Hutchinson's teeth*

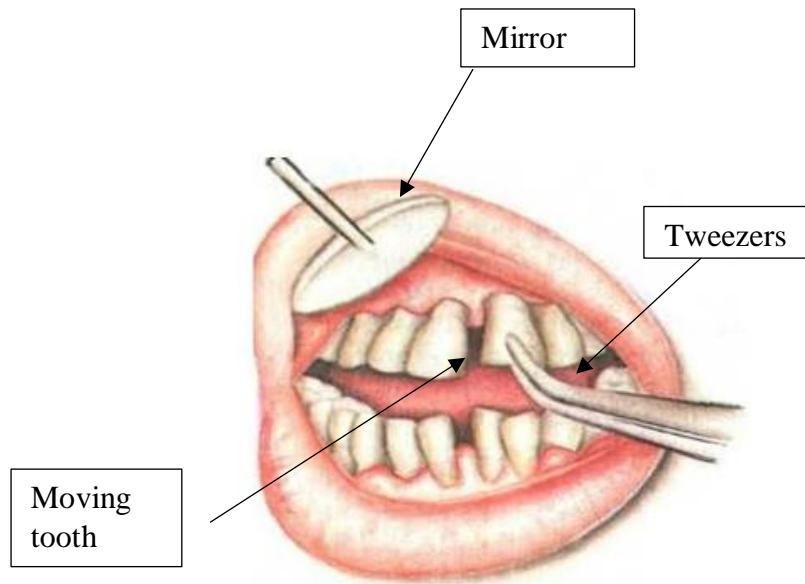


3. *Macrodontia*

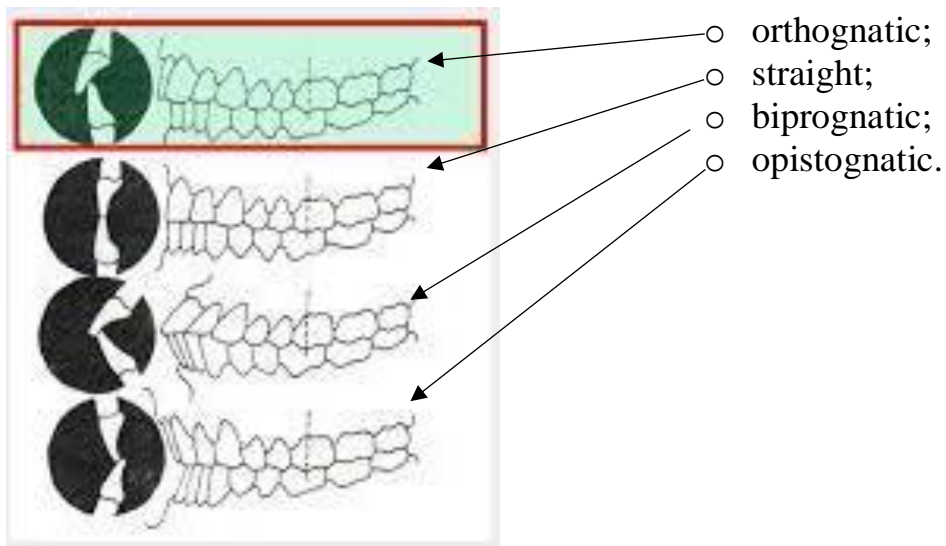


4. *Furnie's teeth*



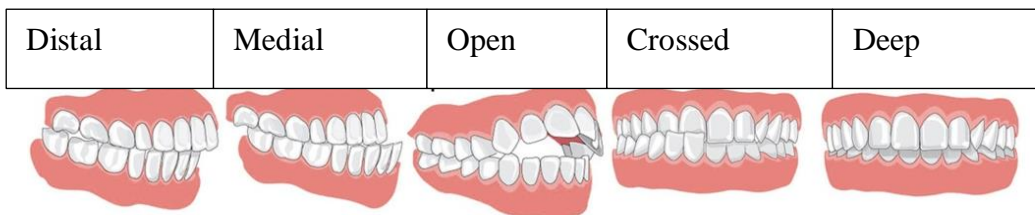


Physiological bite:



Pathological bite:

- distal;
- medial;
- deep;
- open;
- crossed.



**IV. Control questions for the class topic:**

1. What is meant by examination of a dental patient?

2. Where do we start the examination of the patient?
3. How to conduct a general examination of a dental patient?
4. What do we pay attention to when examining the patient's oral cavity?
5. What do you use for dental examination?
6. What is included in the patient's examination kit and how should this toolkit be used?
7. What clinical tests are used to evaluate the functional integrity of fillings?
8. What is percussion and palpation and what is the difference between them?
9. What is tooth mobility and what are its degrees?
10. What should you look for when assessing the bite?

**V. Control test tasks and/or case tasks:**

1. What makes it possible to judge the patient's condition in general and obtain valuable information necessary to establish a diagnosis of the disease, and sometimes to make a prognosis?

- A. The patient's complaints;
- B. The patient's history;
- C. Duration of pain;
- D. Pain syndrome;
- D. General examination.

**The correct answer is: D.**

2. What does NOT apply to the general examination of a dental patient:

- A. Examination of the oral cavity;
- B. Mucous membrane of the gums;
- C. Family life;
- D. Condition of the skin;
- D. Dental examination .

**The correct answer is: B.**

3. To examine the teeth are used:

- A. A mirror;
- B. Tweezers;
- C. Probe;
- D. Excavator;
- D. All answers are correct.

**The correct answer is: D.**

4. Dental examination is recommended to begin on the right side of the lower jaw with:

- A. Fangs;
- B. The last molar;
- C. Central incisor;
- D. First premolar;
- D. All answers are correct.

**The correct answer is: B.**

5. Physiological occlusion includes:

- A. Distal;
- B. Medial;
- C. Biproglossal;
- D. Open;
- D. Crossed.

**The correct answer is: B.**

6. How many degrees of tooth mobility are there?

**The correct answer:** There are 3 degrees of tooth mobility:

I - the tooth deviates in the vestibular-oral (labial-lingual) direction within the width of its cutting edge (1-2 mm);

II - in addition to the mobility characteristic of grade I, the tooth is mobile in the mesiodistal direction;

III - in addition to the above, the tooth is visually mobile in the vertical direction.

## LIST OF REFERENCES

### Main literature

1. Stomatology: textbook: in 2 books. Book I / M.M. Rozhko, Z.B. Popovych, V.D. Kuroiedova et al.: edited by M.M. Rozhko. – Kyiv: AUS Medicine Publishing, 2020. – 792 p.: color edition.
2. Periodontal and Oral Mucosa Diseases: textbook. Vol. 2 / A.V. Borsenko, L.V. Lynovytska, O.F. Nesyn et al.; edited by A.V. Borysenko. - Kyiv: AUS Medicine Publishing, 2018. – 624 p.; color edition.
3. Stomatology: textbook: in 2 books. Book 2 / M.M. Rozhko, I.I. Kyrylenko, O. H. Denysenko et al.; edited by M. M. Rozhko. – Kyiv: AUS Medicine Publishing, 2018. – 960 p.; color edition.

### Additional literature

1. Esthetic Dentistry: A Clinical Approach to Techniques and Materials 3rd Edition by Kenneth W. Aschheim. Publisher: Mosby; 3rd edition, 2014. – 600 p.
2. Esthetic and Restorative Dentistry: Material Selection and Technique 3rd Edition by Douglas A Terry, Willi Geller. Publisher: Quintessence Publishing Co Inc.; 3rd edition, 2017. – 776 p.
3. Dental Composite Materials for Direct Restorations Softcover reprint of the original 1st ed. by Vesna Miletic. Publisher: Springer; 1st edition, 2018. – 327 p.
4. Posterior Direct Restorations 1st Edition by Salvatore Scolavino, Gaetano Paolone. Publisher: Quintessence Pub Co; 1st edition, 2021. – 264 p.
5. Smile Design Integrating Esthetics and Function Essentials of Esthetic Dentistry Volume Two by Jonathan B. Levine. Elsevier Health Sciences, 2015. – 240 p.



6. Cohen's Pathways of the Pulp 12th Edition by Louis H. Berman, Kenneth M. Hargreaves. Publisher: Elsevier; 12th edition, 2020. –992 p.

## Lesson №5

### **TOPIC: Auxiliary methods of examination of the patient: thermodiagnosics, EOD, use of caries detectors: methodology, interpretation of results.**

**I. Topic relevance:** Examination of the patient includes special clinical methods of examination of the oral cavity (temperature diagnostics, index assessment of the hygienic state of the oral cavity, periodontal indices); functional methods of examination (electro-odontodiagnosics).

#### **II. Study goal:**

##### **2.1. Student has to know:**

- Know what is meant by auxiliary methods of examination of a dental patient;
- Know what thermodiagnosics is and how to perform it;
- Know what electro-odontodiagnosics is and how to perform it;
- Know why colour tests with dyes are used;
- Know the methodology of conducting colour tests with dyes;
- Know how to interpret the results of caries detectors.

##### **2.2 Be able to:**

- Be able to perform temperature diagnostics on a dental patient;
- Be able to perform electro-odontodiagnosics on a patient;
- To be able to analyse the results of the patient's EOD;
- Be able to correctly use colour tests with dyes;
- Analyse the results of the use of caries detectors;
- Be able to classify auxiliary methods of patient examination.

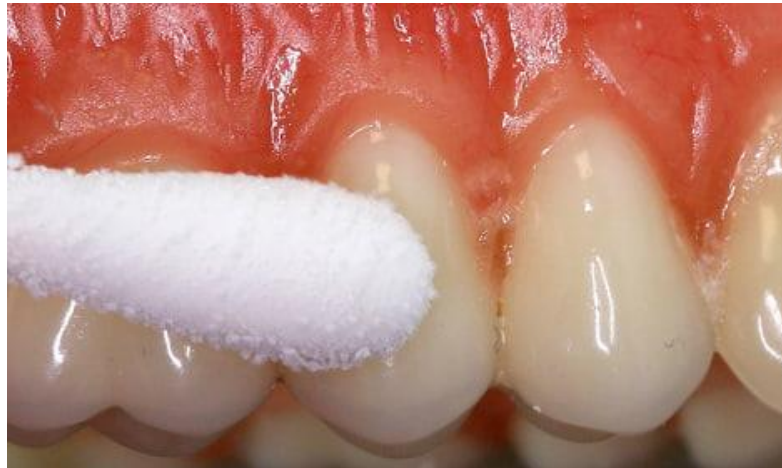#### **III. Content of the topic**

At the caries spots located in fissures there can be difficulties at their diagnostics and differentiation with other pathological conditions, especially with children. It is linked with accumulation of food remnants in fissures, pigments which can change colour of surface fissures. In such cases it is hard visually to reveal a whitish or some pigmented caries spot in the enamel. Using another diagnostic method to reveal the clinical caries signs at probing - softening, sensitiveness of surface of enamel. In children these signs may be very subjective, that is caused by insufficient mineralization of enamel in fissures. In such cases it is had to use the additional methods of caries investigation.

To reveal caries it is possible to use, except for mechanical, (probing) and also other irritants (thermal, chemical). On the fissures surface placed cold (5—10° C) or hot (60-70° C) water or gutta-percha warmed-up to soft consistency. In

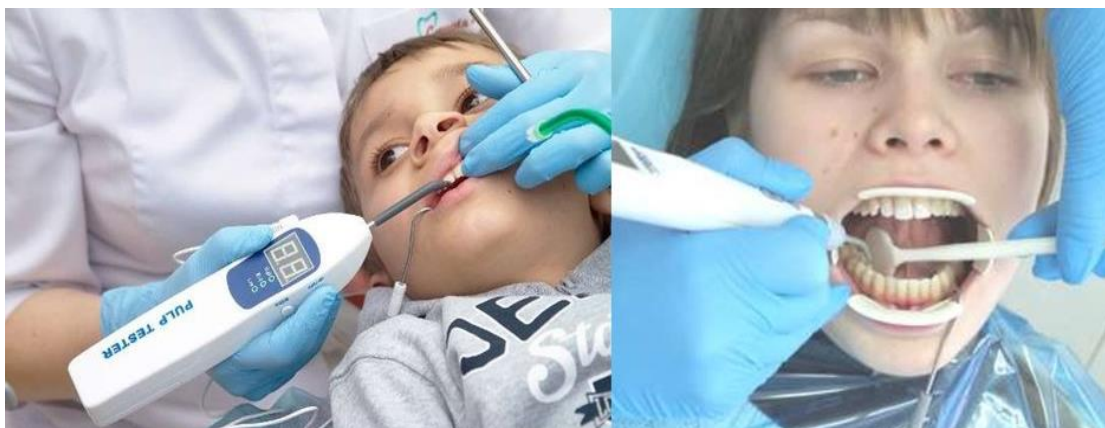intact enamel surface the heating of a fissure within the limits of 10-60° C does not cause a characteristic for a caries pain.

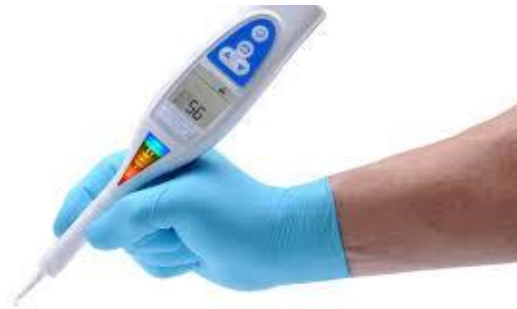Chemical irritants can be used, such as organic solutions (lactic, apple) acids; and inorganic (hydrochloric, carbolic) acids; for solutions of sucrose, glucose, alcohol and ether. Intensity and frequency of feeling pain almost does not rely on the use of an irritant, but is dependent mainly on its concentration, age of patient (in elderly patients the reaction on the pain feeling low) and organism resistance.



The method of electro diagnostic of initial forms of caries was founded (Novik I. O., 1951; N.A. Kodola, 1956). By the special device the conductivity is measured between the surfaces of affected by a pathological process (caries) or suspicious on its presence and intact enamel areas.

A tooth is isolated, dry out, an active electrode is placed on the suspicious area of enamel surface and the passive is placed in the patient hand. If enamel surface is intact, the conductivity is practically equal to the zero because of large electric resistance of intact enamel. At caries presence the conductivity arises. Approximately on the same principle based the method of electro diagnostics of caries offered by V.K. Leontyev (1983).

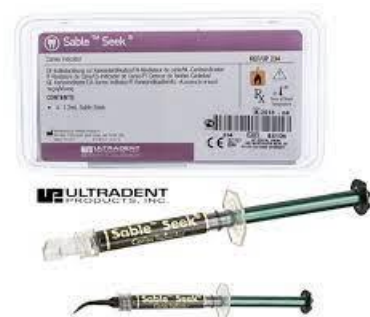
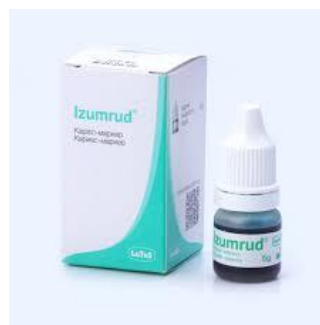
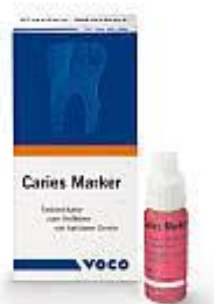

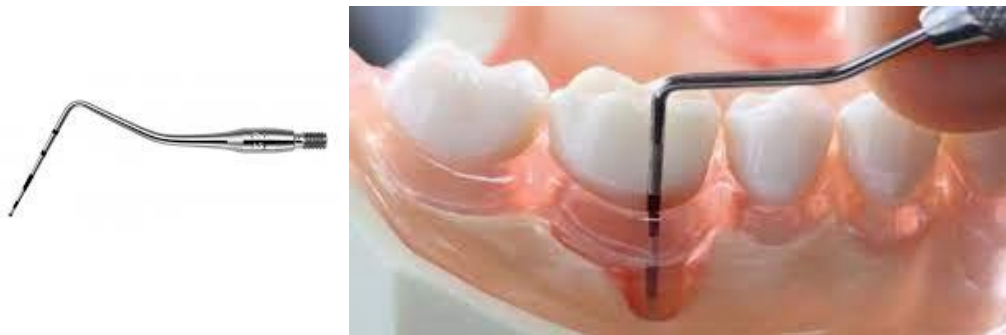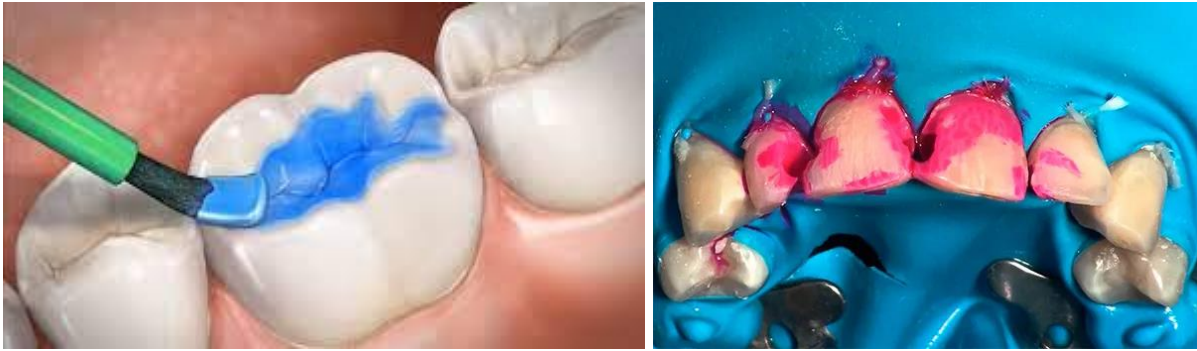The very effective diagnostic method of acute incipience caries is usage of the reactions with *different dyes*. They are based on properties of dye to penetrate into the demineralized enamel and, thus, dyeing a caries spot, while in an intact enamel it cannot penetrate.

It is used a 2% water solution of methyl blue, a 0.1% water solution of methyl red, carmine, Congo red and others. A tooth is isolated from saliva by cotton rolls, dry out and on its surface with cotton pellet place a dye. In a few minutes the remnants of dye wash off by water and at presence of carious spot the surface of enamel gets the colour of dye (dark blue, rose and others). Another method is the use the solution of nitric acid silver, in a caries spot it is restored to metallic silver under influencing of present in her products of protein disintegration.

A spot here acquires the black colour. More rapid renewal of silver in this reaction can be attained by placed on the treated by nitric acid silver surface of enamel the repairer, for example a 4% solution of hydroquinone. In a carious spot the quantity of mineral components (apatites) of enamel diminishes because of processes of demineralization. It causes changes of conductivity of this hard tooth tissues, namely to its increase, because electric resistance of such area of enamel diminishes.





#### IV. Control questions for the class topic:

1. What is temperature diagnostics?
2. How to properly perform thermal diagnostics on a patient?
3. What is electro-odontodiagnostics?
4. How to interpret the results of EOD?
5. What are colour tests with dyes?
6. What is the technique of using caries marker colouring?
7. How to properly analyse the data after a colour test with dyes?
8. What is periodontium?
9. How to identify periodontal inflammation?

#### V. Control test tasks and/or case tasks:

1. What determines the reaction of a tooth to temperature stimuli?
  - A. EOD;
  - B. Temperature diagnostics;
  - C. Radiography;
  - D. Caries - marker;
  - D. CT SCAN.

**The correct answer is: B.**

2. The electrical excitability of the pulp is determined by:
  - A. Vital staining;
  - B. Radiography;
  - C. Examination of the oral cavity;
  - D. Electro-odontodiagnostics;
  - E. Dental examination.

**The correct answer is D.**

3. The pulp of intact healthy teeth reacts to the current within:

- A. 2 - 6  $\mu\text{A}$ ;
- B. 7 - 15  $\mu\text{A}$ ;
- C. 15 - 40  $\mu\text{A}$ ;
- D. 40 - 100  $\mu\text{A}$ ;
- E. more than 100  $\mu\text{A}$ .

**The correct answer is: A.**

4. The most sensitive points for electrode placement are:

- A. The middle of the cutting edge of the canine;
- B. The middle of the tubercles of the last molar;
- C. The middle of the cutting edge of the central incisor;
- D. The middle of the tubercles of the first premolar;
- E. All answers are correct.

**The correct answer is C.**

5. For the colouring of hard tooth tissues use:

- A. 2% alcohol solution of methylene blue;
- B. 2% aqueous solution of methylene blue;
- C. 4% aqueous solution of methylene blue;
- D. 0.1% aqueous solution of methylene blue;
- E. 0.4% alcohol solution of methylene blue.

**The correct answer is: B.**

6. The TER test is based on the phenomenon of penetration of the dye into the acid-dissolved enamel. By comparing the acquired colour with a standard scale, a quantitative assessment of the caries resistance of tooth enamel is obtained in points. How are the scores classified?

**Correct answer:** The results can be classified as follows:

1 -3 points - pale blue colour, indicating a significant resistance of the enamel to caries;

4-6 points - blue colour, indicating an average degree of functional resistance of the enamel;

7 - 9 points - blue colour, indicating a significant decrease in enamel resistance and a high risk of caries;

10-12 points - dark blue colour, indicating a very significant decrease in the functional resistance of the enamel and the maximum risk of caries.

7. To detect periodontal pockets are used:

- A. Forceps;
- B. Mirror;
- C. Button probe;
- D. Probe;
- D. Excavator.

**The correct answer is C.**

## LIST OF REFERENCES

### **Main literature**

1. Stomatology: textbook: in 2 books. Book I / M.M. Rozhko, Z.B. Popovych, V.D. Kuroiedova et al.: edited by M.M. Rozhko. – Kyiv: AUS Medicine Publishing, 2020. – 792 p.: color edition.
2. Periodontal and Oral Mucosa Diseases: textbook. Vol. 2 / A.V. Borsenko, L.V. Lynovytska, O.F. Nesyn et al.; edited by A.V. Borysenko. - Kyiv: AUS Medicine Publishing, 2018. – 624 p.; color edition.
3. Stomatology: textbook: in 2 books. Book 2 / M.M. Rozhko, I.I. Kyrylenko, O. H. Denysenko et al.; edited by M. M. Rozhko. – Kyiv: AUS Medicine Publishing, 2018. – 960 p.; color edition.

### **Additional literature**

1. Esthetic Dentistry: A Clinical Approach to Techniques and Materials 3rd Edition by Kenneth W. Aschheim. Publisher: Mosby; 3rd edition, 2014. – 600 p.
2. Esthetic and Restorative Dentistry: Material Selection and Technique 3rd Edition by Douglas A Terry, Willi Geller. Publisher: Quintessence Publishing Co Inc.; 3rd edition, 2017. – 776 p.
3. Dental Composite Materials for Direct Restorations Softcover reprint of the original 1st ed. by Vesna Miletic. Publisher: Springer; 1st edition, 2018. – 327 p.
4. Posterior Direct Restorations 1st Edition by Salvatore Scolavino, Gaetano Paolone. Publisher: Quintessence Pub Co; 1st edition, 2021. – 264 p.
5. Smile Design Integrating Esthetics and Function Essentials of Esthetic Dentistry Volume Two by Jonathan B. Levine. Elsevier Health Sciences, 2015. – 240 p.
6. Cohen's Pathways of the Pulp 12th Edition by Louis H. Berman, Kenneth M. Hargreaves. Publisher: Elsevier; 12th edition, 2020. –992 p.

## Lesson №6

**TOPIC: X-ray, luminescence and transillumination diagnostics.  
Indications, features of the procedure. Diagnostic tests: with anaesthesia  
and for dissection. Methods of determining trigger zones and examination  
of the exit points of the peripheral branches of the trigeminal nerve.  
Laboratory methods of examination. Interpretation of results.**

**I. Topic relevance:** The examination of the patient includes additional and functional examination methods, without which it is difficult for the dentist to establish a definitive diagnosis. These include radiological examination, which has several types of diagnostics: intraoral radiography, extraoral radiography, panoramic radiography, computed tomography, orthopantomography, electroradiography, fluorescent and transillumination diagnostics

### **II. Study goal:**

#### ***2.1. Student has to know:***

- Know what is meant by additional and functional examination methods;
- Know the types of radiography and how to distinguish between them;
- Know how to perform a radiographic examination correctly;
- Know what luminescent diagnostics is;
- Know the difference between luminescent and transillumination diagnostics;
- Know what diagnostic tests with anaesthesia and dissection are;
- Know the definition of trigger zones.

#### ***2.2 Be able to:***

- Be able to perform radiological diagnostics;
- Be able to perform luminescence diagnostics and analyse the results;
- Be able to perform transillumination diagnostics and analyse the results;
- To be able to perform diagnostic tests with anaesthesia and for dissection;
- Be able to identify trigger points and examine the exit points of the peripheral branches of the trigeminal nerve;
- Be able to classify laboratory methods of examination.

### **III. Content of the topic**

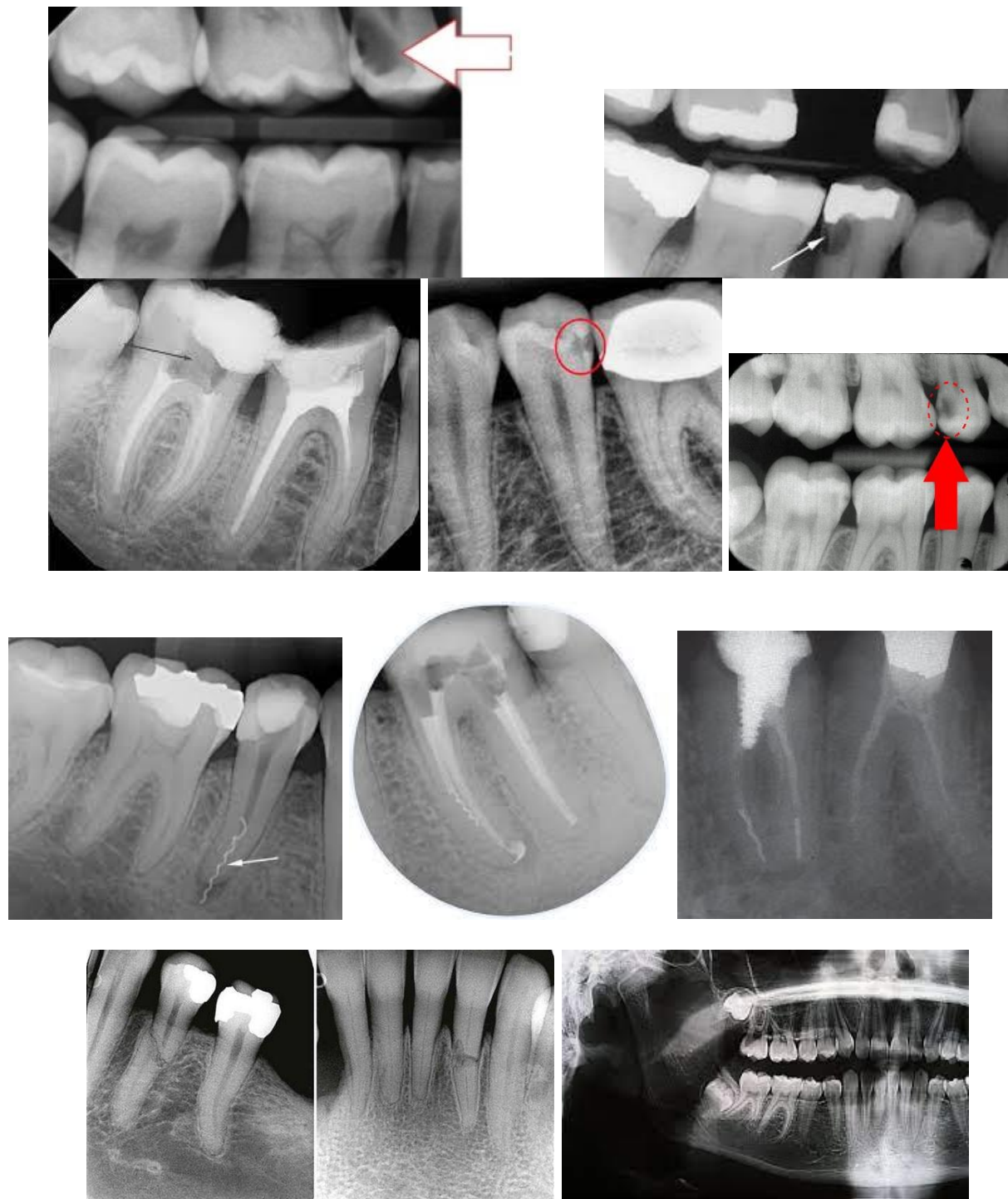

*Diagnostic radiography* is an integral part of the clinical process. It is predicated on a careful correlation of patient history and clinical findings. Radiographs should be ordered in those instances in which the clinician anticipates that the expected obtained will contribute materially to the proper diagnosis, treatment, and prevention of disease.

*The standard X-ray image* in caries diagnostics is an imaging of the bite wing or of the individual tooth. This is done to search specifically for caries near the contact points between the teeth (approximal caries) and dentin caries created in the depth of the fissures. For standard two-dimensional radiography, clinicians basically project X-radiation through an object and capture the image on a recording medium - either X-ray film or a digital sensor. On an X-ray image, caries appears as a dark spot.

**X-rays** are less absorbed in dental areas with mineral loss or defects and thus blacken the film. Radiographic examination of the hard tissues can often provide valuable information regarding caries and existing restorations, calcifications, internal and external resorptions, tooth and pulpal morphology, root fractures, the relationship of anatomic structures, and the architecture of the osseous tissues. In general, when endodontic pathosis appears in radiography, it appears as bone loss in the area of the periapex.

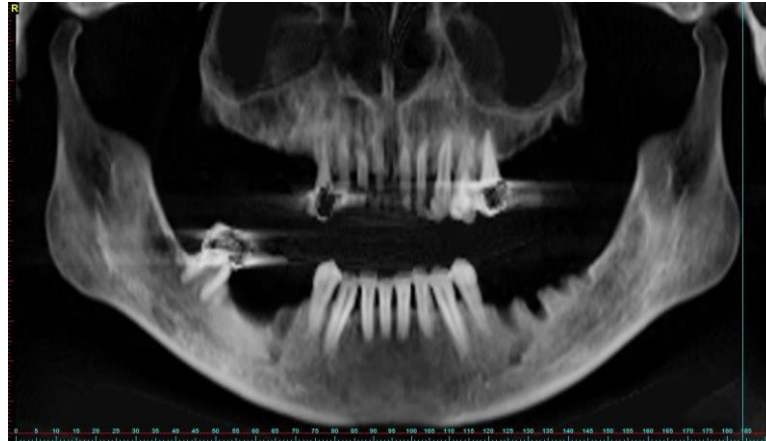The infection in the pulpal space transgresses through the pulp canal space and into the adjacent alveolar bone. The pathosis may present merely as a widening or break in the lamina dura - the most consistent radiographic finding when a tooth is non vital - or it may present as a radiolucent area at the apex of the root or in the alveolar bone adjacent to the exit of a lateral or furcation canal. Bitewing Radiography: The process of creating radiograph images of the posterior teeth, with the specific objective of identifying carious lesions on the proximal surfaces that may be inaccessible to visual and tactile examination. Less mineralized tissues permit more x-rays to pass through (radiolucency) and therefore create greater levels of exposure to radiographic film or a digital transducer. The viewing of a digital radiographic image on a high-resolution monitor allows for rapid and easy interpretation for both the clinician and the patient. The image appears almost instantly, with no potential for image distortion from improper chemical processing, because there is none. The clinician can zoom in to different areas on the x-ray image, digitally enhance the image in order to better visualize certain anatomic structures, and in some cases the image can even be colourized, which is a useful tool for patient education.



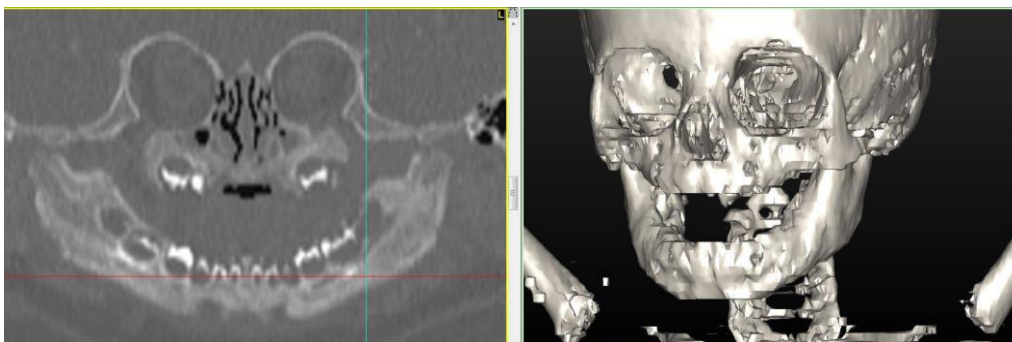
1. *Tooth fracture*

2. *Retained teeth*

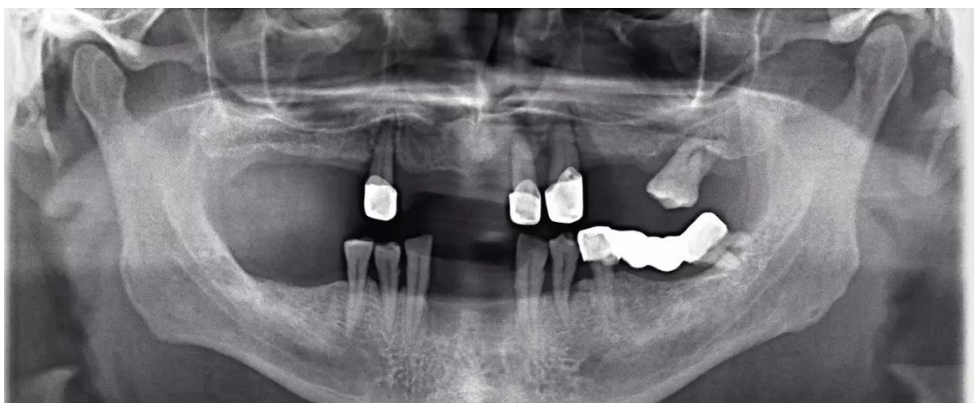
*Atrophy* — reduction in bone volume due to bone resorption.



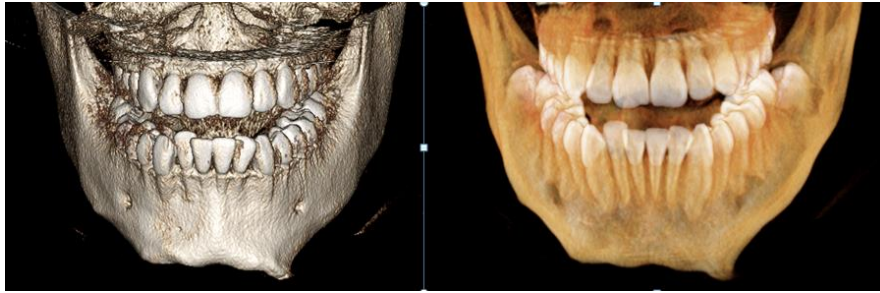*Hyperostosis* — volumetric bone augmentation.



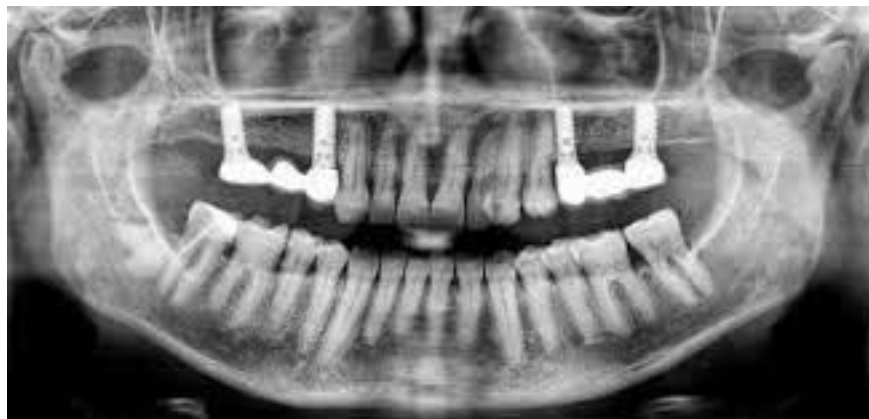*Destruction* — destruction, change of bone structure with its subsequent replacement by another pathologically altered tissue. A distinction is made between focal (in the form of one or more foci of lightening of flat bones) and diffuse destruction. Complete resorption of the bone and disappearance of all its elements is called osteolysis.



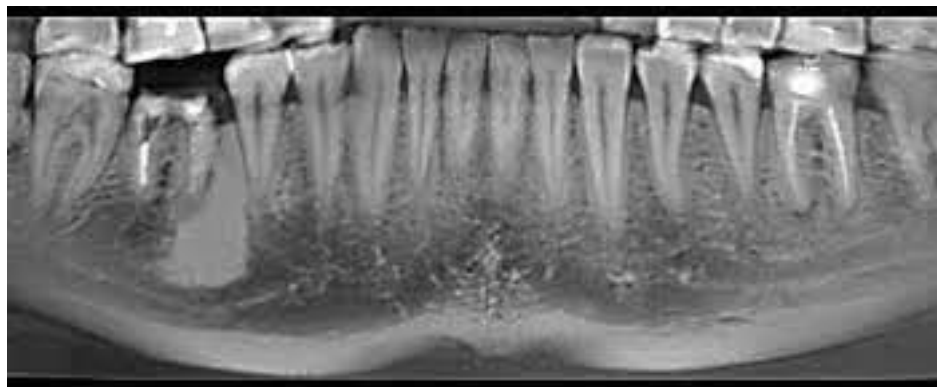
*Deformation* — violation of the anatomical shape of the bone.



*Osteoporosis* — is a dystrophic process that results in a decrease in the thickness of bone plates. It is characterised by increased radiological transparency of bone tissue, can be focal and diffuse.



*Osteosclerosis* — bone compaction: the spongy substance becomes compact; it can be focal and diffuse. The combination of these radiological symptoms creates a diverse radiological picture of the disease.

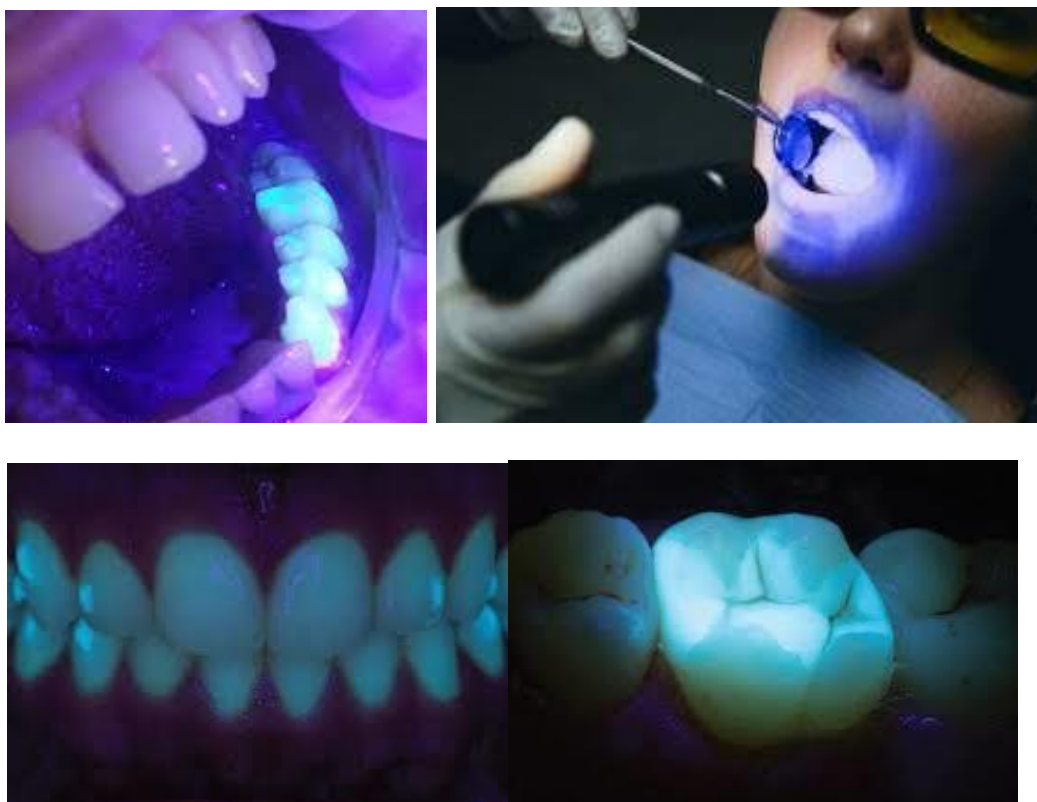

It is possible to apply the method of luminescent diagnostics, which is based on the phenomenon of fluorescence of intact hard tooth tissues under action on them of ultraviolet rays. The special ultraviolet lamps are used for this purpose. In the black-out apartment the surface of tooth is lighted by a lamp in the distance

by 20-30 sm. By fluorescence intact dental enamel shines light-green or bluish light, while areas affected by caries areas do not radiate light. The histological features at an initial caries are characterized development of different degree of enamel demineralization. At the enamel section the body of caries lesion has the triangle appearance with the basis turned of to enamel sur-face. At the study in the polarized light depending on the structure changes in the enamel lesion distinguish a few areas.

The most demineralized is sub superficial lesion layer, which is covered by the mineralized superficial enamel layer. This interesting phenomenon is explained by the remineralization processes of carious lesion by the mineral components of saliva, if an oral fluid is unable to provide remineralization of the demineralized enamel area the rapid development of caries lesion occurs. The surface texture of an incipient lesion is unaltered and is undetectable by tactile examination with an explorer.

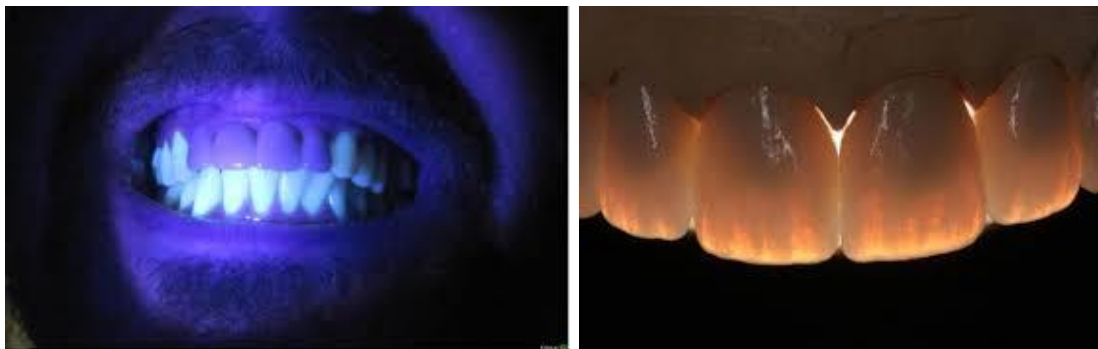
A more advanced lesion develops a rough surface that is softer than the unaffected, normal enamel. Softened chalky enamel that can be chipped away with an explorer is a sign of active caries. In the interior layers of white caries spot there are the changes both enamel rods surfaces and prisms themselves. In separate areas the crystals of apatites are destroyed, their orientation in rods changes, in formed micro spaces there are atypical crystals.



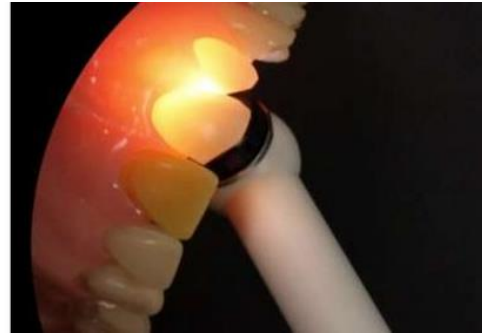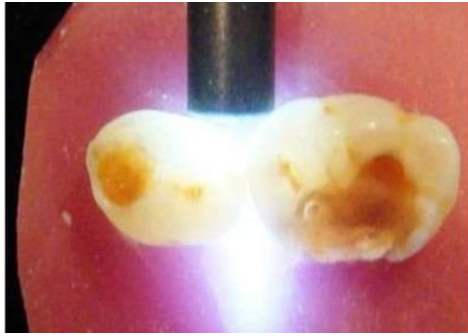Fragmentation of crystals, formation of homogeneous fine-grained substance and disappearances of visible border, between prisms is marked in future. Non-cavitated enamel lesions retain most of the original crystalline framework of the enamel rods and the etched crystallites serve as nucleating agents for remineralization.

Calcium and phosphate ions from saliva can then penetrate the enamel surface and precipitate on the highly reactive crystalline surfaces in the enamel lesion. Remineralized (arrested) lesions can be observed clinically as intact, but dis-colored, usually brown or black spots. Depending on the degree of the demineralization G. Gustafson (1975) distinguishes five zones. Most deeply in the enamel there is placed hyper mineralization zone with disappearance enamel structural components.

In the second zone there is reduction of its hardness because of partial dissolution of enamel minerals, in the third - increase of mineralization. In a sub superficial fourth demineralization zone the minerals are almost fully washed. In a superficial fifth zone there can be complete disintegration, however it during long time remains enough mineralized and undamaged, even when caries spread on all thickness of enamel.



One diagnostic aid in the anterior tooth area is the transillumination of contact points between incisors. A polymerisation lamp can be used as a light source. In contrast to healthy enamel, caries will appear darker. • *Transillumination/dye staining.* The use of a fibre-optic light is an excellent method of examining teeth for coronal cracks and vertical root fractures. The tooth or root should be examined in the presence of minimal background lighting. The fibre optic light is then placed on the varied surfaces of the coronal tooth structure or on the root after flap reflection. Fracture lines can be visually detected when light fails to traverse the fracture line. The fractured segment near the light appears brighter than the segment away from the light. Application of dyes to the tooth can also demonstrate fractures as the dye penetrates the fracture line. An ancillary technique is the application of dye to the internal surfaces of a cavity preparation or access opening; the clinician leaves the dye in place for a week before reexamining the tooth.



**LABORATORY METHODS.** In physical evaluation, clinical laboratory procedures may provide the final clue essential to confirm a diagnosis. They may also lead to the early detection of disorders with vague signs and symptoms contribute to the discovery of significantly, unexpected conditions, or provide a baseline against which response to or the safety of a therapeutic intervention may be measured. Consequently, in some situations, clinical laboratory information may be essential prior to the initiation of therapy. In other instances, it may be an important component of a diagnostic or therapeutic follow — up evaluation. Prior to ordering laboratory procedures, the clinician should elicit a careful medical history, perform a thorough physical examination, evaluate radiographic studies, and then request the tests from the laboratory that are most likely to either confirm or exclude the provisional diagnosis.

**MUTANT STREPTOCOCCI IN SALIVA.** In toddlers (1-2 years) the presence of mutant streptococci as the sole predictor for caries during the following 2—3 years had low accuracy (either low sensitivity combined with high specificity, or vice versa).

**SALIVARY LACTOBACILLUS COUNT.** In a large number of studies on both toddlers and preschool children, the presence of lactobacilli in saliva has been tested as the sole predictor or in models. The accuracy in predicting the development of caries lesions is low.

#### **IV. Control questions for the class topic:**

1. What additional research methods are used in the diagnosis of caries diagnosis?
2. What additional research methods are used in the diagnosis of various forms of pulpitis?
3. What additional research methods are used in the diagnosis of apical periodontitis?
4. The principle, methodology and interpretation of the results of luminescent diagnostics.
5. The principle, methodology and interpretation of the results of transillumination diagnostics.
6. What are the results of the tooth preparation test depending on the state of the pulp?

7. Indications, methodology and interpretation of the results of the test with anaesthesia.

8. Methods of examination of the exit sites of the peripheral branches of the trigeminal nerve. Value in the differential diagnosis of acute forms of pulpitis.

9. Methods for determining trigger zones.

**V. Control test tasks and/or case tasks:**

1. What gives the densest shadow in X-rays?

- A. Enamel;
- B. Dentin;
- C. Mucous membrane;
- D. Cement.

**The correct answer is: A.**

2. The cavity of the tooth on X-rays has the form of:

- A. A thick shadow;
- B. Shadow;
- C. Enlightenment;
- D. Dense shadow;
- D. Dense enlightenment.

**The correct answer is C.**

3. Radiography can detect:

- A. Retained teeth;
- B. Tooth decay;
- C. Fracture of the tooth root;
- D. The state of bone tissue;
- E. All of the above.

**The correct answer is: D.**

4. What type of radiography allows to obtain a plane-expanded layer-by-layer image of both closed (or open) jaws on one film? How to perform this examination correctly?

**The correct answer:** Orthopantomography. The patient is examined on a special apparatus - an orthopantomograph. During the examination, an X-ray tube and a semicircular film cassette placed opposite it at opposite ends of the console axis rotate in a horizontal plane around the patient's head, which is fixed motionless. The device rotates the X-ray tube around three axes, which ensures perpendicular and orthoradic direction of the rays relative to the area under examination. The film cassette is placed as close as possible to the maxillofacial area. Thus, the X-rays passing through different parts of the jaws always hit different parts of the film, and as a result, both jaws are displayed on the film.

5. A dystrophic process that results in a decrease in the thickness of the bone plates. It is characterised by increased radiological transparency of bone tissue, can be focal and diffuse:

- A. Atrophy;
- B. Hyperostosis;



- C. Destruction;
- D. Deformation;
- E. Osteoporosis.

**The correct answer is: D.**

6. Destruction, change of bone structure with its subsequent replacement by another pathologically altered tissue. Distinguish between focal (in the form of one or more foci of luminal bone) and diffuse destruction:

- A. Atrophy;
- B. Hyperostosis;
- C. Destruction;
- D. Deformation;
- E. Osteoporosis.

**The correct answer is: B.**

7. Complete resorption of bone and disappearance of all its elements is called:

- A. Osteolysis;
- B. Hyperostosis;
- C. Osteosclerosis;
- D. Deformation;
- E. Osteoporosis.

**The correct answer is A.**

8. What method is used to determine the state of marginal adhesion of fillings, to recognise the initial caries of teeth, differential diagnosis of diseases of the oral mucosa? How to conduct this study correctly?

**The correct answer:** Luminescent diagnostics. It is based on the ability of tissues and their cellular elements to emit light of a certain colour when exposed to ultraviolet rays (primary or intrinsic fluorescence of a substance). The examination is carried out in a darkened room after the eyes have adapted to the darkness using special devices and microscopes with filters for fluorescence cytological examination. The surface of the tooth is irradiated with ultraviolet rays from a distance of 20-30 cm using a lamp. To enhance the effect of fluorescence, the examined tissues can be pretreated with fluorescent substances (e.g. fluorescein, fluorochrome, tryptaflavin, etc.). This fluorescence is called secondary fluorescence.

## LIST OF REFERENCES

### Main literature

1. Stomatology: textbook: in 2 books. Book I / M.M. Rozhko, Z.B. Popovych, V.D. Kuroiedova et al.: edited by M.M. Rozhko. – Kyiv: AUS Medicine Publishing, 2020. – 792 p.: color edition.

2. Periodontal and Oral Mucosa Diseases: textbook. Vol. 2 / A.V. Borsenko, L.V. Lynovytska, O.F. Nesyn et al.; edited by A.V. Borysenko. - Kyiv: AUS Medicine Publishing, 2018. – 624 p.; color edition.
3. Stomatology: textbook: in 2 books. Book 2 / M.M. Rozhko, I.I. Kyrylenko, O. H. Denysenko et al.; edited by M. M. Rozhko. – Kyiv: AUS Medicine Publishing, 2018. – 960 p.; color edition.

### **Additional literature**

1. Esthetic Dentistry: A Clinical Approach to Techniques and Materials 3rd Edition by Kenneth W. Aschheim. Publisher: Mosby; 3rd edition, 2014. – 600 p.
2. Esthetic and Restorative Dentistry: Material Selection and Technique 3rd Edition by Douglas A Terry, Willi Geller. Publisher: Quintessence Publishing Co Inc.; 3rd edition, 2017. – 776 p.
3. Dental Composite Materials for Direct Restorations Softcover reprint of the original 1st ed. by Vesna Miletic. Publisher: Springer; 1st edition, 2018. – 327 p.
4. Posterior Direct Restorations 1st Edition by Salvatore Scolavino, Gaetano Paolone. Publisher: Quintessence Pub Co; 1st edition, 2021. – 264 p.
5. Smile Design Integrating Esthetics and Function Essentials of Esthetic Dentistry Volume Two by Jonathan B. Levine. Elsevier Health Sciences, 2015. – 240 p.
6. Cohen's Pathways of the Pulp 12th Edition by Louis H. Berman, Kenneth M. Hargreaves. Publisher: Elsevier; 12th edition, 2020. –992 p.

## Lesson №7

### **TOPIC: Medical documentation of a therapeutic appointment Medical record of a dental patient (f.043/ O) is a medical, scientific and legal document.**

**I. Topic relevance:** All the data obtained during the examination is recorded in the dental patient's medical record. All stages of treatment of dental and oral diseases are also recorded in the medical record. The medical record is an official legal document, and the accuracy of its completion is of great importance for determining the necessary treatment and, in some cases, for the legal assessment of the doctor's actions.

#### **II. Study goal:**

##### **2.1. Student has to know:**

- Know what medical records are;
- Know what types of dental records exist;
- Know what tooth marking schemes are used;
- Know how to properly fill in the patient's medical history;
- Know what a medical document is;
- Know what a scientific document is;
- Know what a legal document is;

##### **2.2 Be able to:**

- Be able to fill in a medical record of a dental patient;
- Know how to use tooth marking schemes;
- Be able to correctly fill in the stages of treatment;
- Be able to distinguish between medical documentation;

#### **III. Content of the topic**

##### **Medical record (medical history) of a dental patient**

*The first section of the card* - the passport part - contains basic data about the patient: surname, name and patronymic; age, sex, place of residence, occupation, address. This part of the card is filled in at the reception desk during the initial visit to the doctor.

Later, the doctor enters data from the interview (complaints, medical and life history), examination, clinical and additional methods of objective

examination. A special section contains data on the general examination of the patient and his or her oral cavity.

Special schemes have been developed for the convenience of recording the results of the oral examination. Today, there are several recording schemes. The most commonly used is the designation of the dentition in the form of a dental

8	7	6	5	4	3	2	1	1	2	3	4	5	6	7	8
8	7	6	5	4	3	2	1	1	2	3	4	5	6	7	8

formula:

Permanent teeth are marked with Arabic numerals, and temporary (milk) teeth are marked with Roman numerals.

V	IV	III	II	I	I	II	III	IV	V
V	IV	III	II	I	I	II	III	IV	V

The numbers above the horizontal line represent the upper teeth and below it the lower teeth. The vertical line divides the formula in the middle, which corresponds to the midline of the dentition. The numbers on the left indicate the teeth of the right half of the jaw, and the numbers on the right indicate the teeth of the left half. In other words, the doctor looks at the patient through this formula, superimposing it on the patient's dentition.

Conventionally, each tooth of the permanent and temporary bites has its own numerical designation. Permanent teeth are designated by Arabic numerals from 1 to 8:

- 1 - central incisor,
- 2 - lateral (lateral) incisor,
- 3 - canine,
- 4 - first premolar (first small angular tooth),
- 5 - second premolar (second small angular tooth),
- 6 - first molar (first large angular tooth),
- 7 - second molar,
- 8 - third molar.

Temporary (milk) teeth are designated by Roman numerals from I to V:

- I - central incisor,

II - lateral (lateral) incisor,

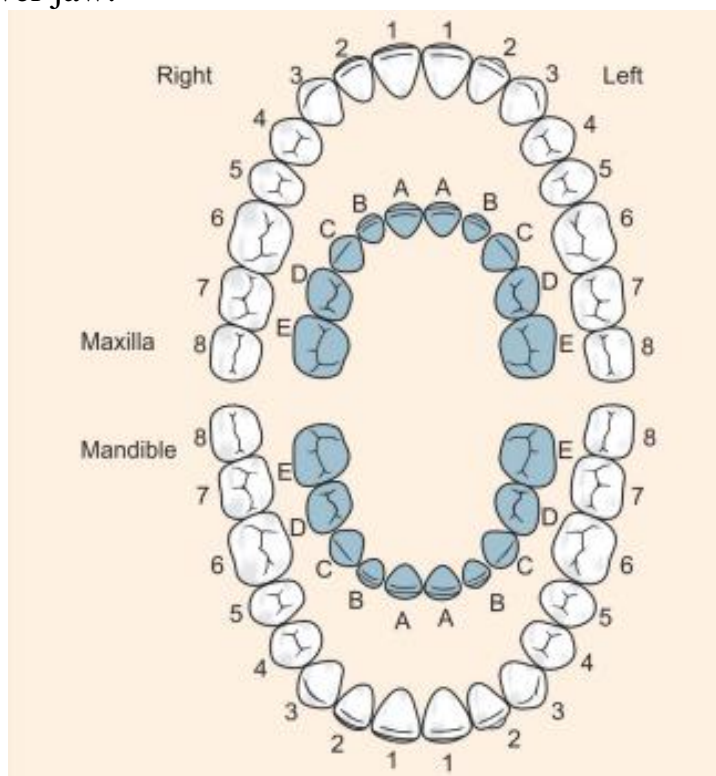
III - canine,

IV - first molar,

V - second molar.

When writing down the formula for the teeth of an alternating bite, Arabic and Roman numerals are added to it in accordance with the location of the permanent and temporary teeth. To indicate that an individual tooth belongs to one side of the jaw or the other, a combination of vertical and horizontal angled lines is used, together with the number corresponding to the tooth. The digit above the horizontal line indicates the tooth of the upper jaw, and the digit below it indicates the tooth of the lower jaw. A vertical line on the left indicates a tooth in the left half of the jaw, and a vertical line on the right indicates a tooth in the right half of the jaw. For example,  $\lfloor 1$  means the upper left central incisor,  $2 \rfloor$  means the upper right lateral (lateral) incisor,  $\lrcorner 4$  means the lower left first premolar,  $6 \lrcorner$  means the lower right first molar,  $\lfloor IV$  means the upper left first temporary (milk) molar, etc.

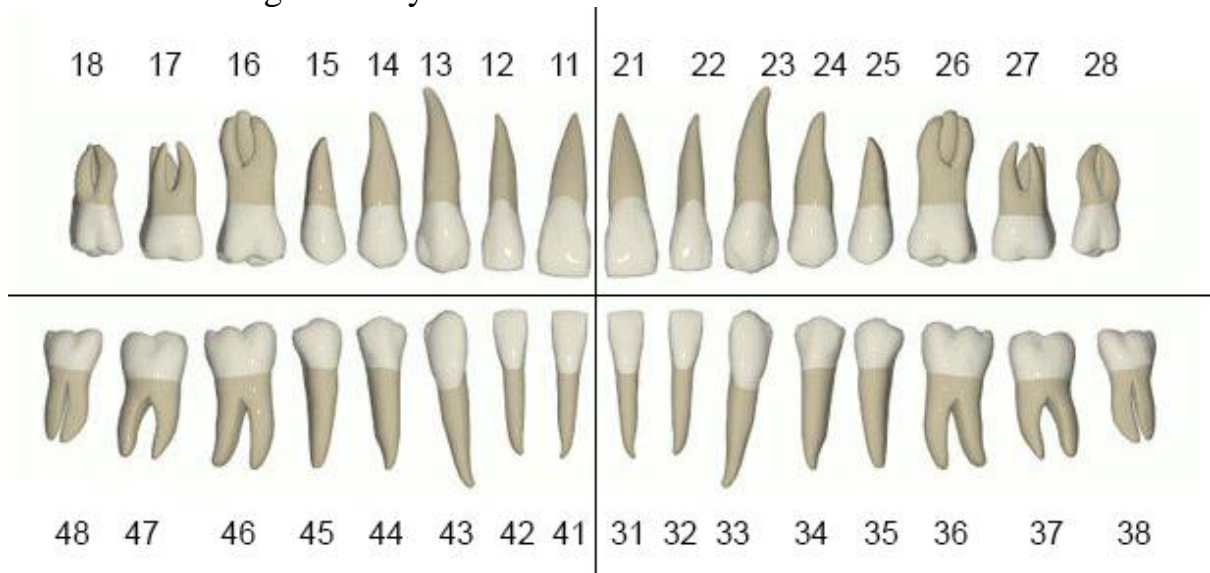
To unify the recording of the dental formula, the WHO (World Health Organization) and FDI (International Federation of Dentists) proposed a two-digit system of designation of teeth depending on their location on one side or the other of the upper or lower jaw.



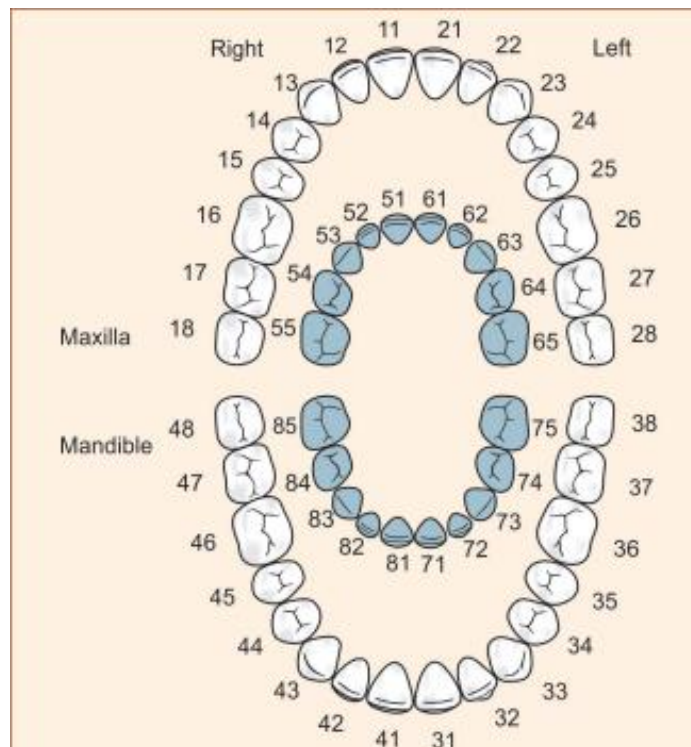
In this system, each tooth is labelled with two Arabic numerals, the first of which indicates the quadrant of the corresponding half of the jaw and the second the serial number of the tooth in that quadrant. Both jaws of the patient are divided into four quadrants, which have their own numbers. The designation begins with

the upper jaw on the right, which has number 1. Then they move clockwise and mark the corresponding halves of the jaws: the upper left jaw with the number 2, the lower left jaw with the number 3 and the lower right jaw with the number 4.

The serial number of each tooth is indicated by the generally accepted system (see above) from the central incisor (1) to the third molar (8). The dental formula according to this system looks like this:



For temporary teeth in this system, instead of Roman numerals, Arabic numerals are also used, but unlike the permanent bite, the jaw quadrants have numbers from the 5th (right half of the upper jaw) to the 8th (right half of the lower jaw). According to this system, the dental formula for a temporary bite is as follows:



Accordingly, the designation of teeth according to this system is as follows: 21 - upper left central incisor, 46 - lower right first molar, 62 - upper left lateral (lateral) temporary incisor, etc. The advantage of the new system of dental formula expression over the conventional one is the possibility of easy transfer of notations to a computer and further processing of information.

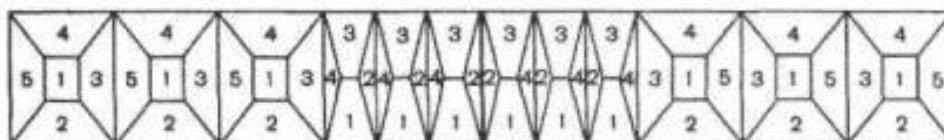
A specific variant of the digital tooth marking system is the system developed by the American Association of Dentists. According to this system, all permanent bite teeth are designated by numbers from 1 to 32: the teeth of the right half of the upper jaw, starting with the third molar, have numbers from 1 to 8; on the left half, the count continues - the first incisor has the number 9 and then up to the third molar - the number 16.

The teeth of the lower jaw begin with the third left molar, number 17, and continue to number 32, the third right molar. The sequence of counting is similar for temporary teeth, but they are designated by letters of the Latin alphabet. Thus, the formula of teeth according to this system looks like this:

1	2	3	4	5	6	7	8	9	10	11	12	13	14	15	16
32	31	30	29	28	27	26	25	24	23	22	21	20	19	18	17

A	B	C	D	E	F	G	H	I	J
T	S	R	Q	P	O	N	M	L	K

Dental formula diagrams have also been developed, which show all the surfaces of the tooth crowns as if in an expanded form. They can be used to accurately mark the location of a carious cavity, filling or other pathological lesion on each individual tooth.



In this formula, the front teeth have 4 surfaces, and the premolars and molars have 5 surfaces. For the correct interpretation of the data in this formula, the following conventions have been adopted for tooth surfaces. For anterior teeth (incisors and canines): 1 - vestibular (gingival, labial) surface; 2 - medial (median); 3 - lingual (palatal) and 4 - distal. On premolars and molars: 1 - masticatory; 2 - vestibular (gingival, buccal); 3 - medial; 4 - lingual (palatal); 5 - distal surface.

Alphabetic designations are used to schematically record diseases and dental conditions in the dental formula:

- C - caries,
- P - pulpitis,

Pt - periodontitis,  
 P - filling,  
 K - artificial crown,  
 H - artificial tooth of a bridge prosthesis,  
 X - tooth root,  
 O - missing tooth,  
 T - trauma (tooth crown),  
 H - hypoplasia,  
 F - fluorosis.

The degree of tooth mobility is indicated by Roman numerals - I, II or III. Sometimes carious cavities are designated by Latin letters and classified according to their location on different tooth surfaces. For this purpose, the following letter designations of different tooth surfaces are accepted:

O - occlusal (chewing);  
 I - cutting (incisal) edge;  
 M - medial contact;  
 D - distal contact;  
 F - vestibular (gingival, frontal, labial);  
 C - buccal (buccal);  
 L - lingual (palatal, lingual).

Combined carious cavities located simultaneously on several tooth surfaces are indicated by a combination of several letters, for example:

MO - medial occlusal cavity, i.e. a cavity located on the chewing and medial contact surfaces of the tooth crown;

M O D - medial occlusal-distal cavity, i.e. located on the chewing, medial and distal contact surfaces of the tooth crown;

MI - medial invasive cavity, i.e. located on the medial surface and cutting edge of the anterior tooth crowns;

FO - vestibular occlusal cavity, i.e. located on the vestibular (gingival) and chewing surfaces of the crowns of the posterior teeth (premolars and molars);

LO - lingual-occlusal cavity, i.e. located on the lingual and chewing surfaces of the crowns of the teeth.

Cavities located on the other upper surfaces of the tooth crowns are designated in the same way.

After indicating the condition of the teeth on the dental formula, the dentist notes the nature of the bite (physiological or pathological), the condition of the periodontal tissues and oral mucosa. The doctor describes in detail the local condition of the lesion - carious cavity, non-carious defect, traumatic lesion, etc. Then notes the data of the clinical examination (examination, percussion, palpation, etc.). If additional examinations were performed (e.g., X-ray, electroodontodiagnostic, laboratory), the data obtained are also recorded in the card.

After the interview, examination, and additional tests, the doctor determines the diagnosis of the disease and enters it in a special column. In some



complicated cases, it is permissible, but it must be noted in the card, to make a preliminary diagnosis. In this case, the final diagnosis, indicating the exact date of its establishment, is entered after a full range of diagnostic examinations or even preliminary, trial treatment.

A special section of the medical record contains a treatment plan developed on the basis of the diagnosis and the patient's individual characteristics. The availability of such a plan allows for a complete comprehensive treatment, taking into account the smallest details. In addition, it allows treatment to be carried out even in unforeseen cases of illness or in the absence of the doctor in question.

The stages of treatment (each visit to the doctor) are recorded in a special section called the Treatment Diary. It indicates the date of the visit, the patient's condition and a short list of the medical treatments and surgical interventions performed. The name of the doctor who performed the treatment must be indicated. This section of the card is filled in by the doctor immediately after the visit.

In the section "Epicrisis", after the treatment, the result of the treatment and recommendations to the patient are briefly described. If no treatment is planned in the near future, the medical record is kept in the registry or in the archive of the medical institution.

Recently, it has become increasingly common in medical institutions to enter all information about patients and the course of their treatment into a computer. This allows you to store all the necessary data for many years, and if necessary, they can be easily retrieved from the computer's memory (for prompt use by the doctor, etc.).

Documentation of the patient-dentist relationship has always been a hot topic among dentists.

**All documents can be divided into mandatory and optional.**

*Mandatory documents are:*

- Informed voluntary consent in the form of N003-6/o (the most important document);
- medical record in the form N043/o and N043-1/o;
- other forms of primary accounting documentation (forms N037/o, N037-1/o, N037-2/o, N039-3/o, N039-4/o);
- maintenance of these forms is provided for by sub-clause 22, clause 13 of the Licensing regulations on medical practice and by the orders of the Ministry of Healthcare of Ukraine N110 dated 14.02.12 and N435 dated 29.05.13;
- internal regulations (subclause 1 of clause 12 of the Licensing regulations on medical practice);
- statement (act) of patient's refusal from treatment (Article 43 of the Law of Ukraine "Fundamentals of the Legislation of Ukraine on Healthcare").

*Optional:*

- contract for the provision of dental services/public contract;
- patient's health questionnaire (if the patient needs to be administered a medicine, a questionnaire should be filled out (Order of the Ministry of Health No. 916 of 30.12.15));
- special informed consent of the patient;
- patient's treatment plan;
- consent to photo, audio or video recording;
- recommendations of the dentist;
- guarantees for dental services;
- an act of dental services rendered;
- act of refund to the patient;

**IV. Control questions for the class topic:**

1. What is a dental patient's medical record?
2. What types of dental records do you know?
3. What is the formula for permanent bite teeth?
4. What is the formula for the teeth of a changeable bite?
5. What is the formula for milk bite teeth?
6. What letter designations are used to enter diseases and dental conditions in the dental formula?
7. What information does a dentist record in the "Doctor's diary"?
8. What is the "Epicrisis"?
9. What legal documents do you know?

**V. Control test tasks and/or case tasks:**

1. Which dental form of medical record is used by a dentist-therapist?
  - A. No. 043/o;
  - B. No. 039/o;
  - C. No. 041/o;
  - D. № 049/o.

**The correct answer is: A.**

2. Dental caries is indicated in the medical record of a dental patient by:
  - A. K;
  - B. Ka;
  - C. C;
  - D. Sa;
  - D. N.

**The correct answer is B.**

3. The medial-occlusal cavity, that is, the cavity located on the chewing and medial contact surfaces of the tooth crown is denoted by:
  - A. MO;
  - B. FO;

- C. MOP;
- D. MOD;
- D. MI.

**The correct answer is: A.**

4. What should a dentist record in the "Doctor's diary"?

**The correct answer is:** The stages of treatment (each visit to the doctor) are recorded in a special section "Treatment diary". It contains the date of the visit, the patient's condition and a short list of the treatment measures and surgical interventions performed. The name of the doctor who performed the treatment must be indicated. The doctor fills in this section of the card immediately after visiting the patient.

5. What does a dentist enter in the section "Epicrisis"?

**Correct answer:** In the "Epicrisis" section, after the treatment, the doctor briefly describes the result of the treatment and recommendations to the patient. If no treatment is planned in the near future, the medical record is kept in the registry or in the archive of the medical institution.

#### LIST OF REFERENCES

##### Main literature

1. Stomatology: textbook: in 2 books. Book I / M.M. Rozhko, Z.B. Popovych, V.D. Kuroiedova et al.: edited by M.M. Rozhko. – Kyiv: AUS Medicine Publishing, 2020. – 792 p.: color edition.
2. Periodontal and Oral Mucosa Diseases: textbook. Vol. 2 / A.V. Borsenko, L.V. Lynovytska, O.F. Nesyn et al.; edited by A.V. Borysenko. - Kyiv: AUS Medicine Publishing, 2018. – 624 p.; color edition.
3. Stomatology: textbook: in 2 books. Book 2 / M.M. Rozhko, I.I. Kyrylenko, O. H. Denysenko et al.; edited by M. M. Rozhko. – Kyiv: AUS Medicine Publishing, 2018. – 960 p.; color edition.

##### Additional literature

1. Esthetic Dentistry: A Clinical Approach to Techniques and Materials 3rd Edition by Kenneth W. Aschheim. Publisher: Mosby; 3rd edition, 2014. – 600 p.
2. Esthetic and Restorative Dentistry: Material Selection and Technique 3rd Edition by Douglas A Terry, Willi Geller. Publisher: Quintessence Publishing Co Inc.; 3rd edition, 2017. – 776 p.
3. Dental Composite Materials for Direct Restorations Softcover reprint of the original 1st ed. by Vesna Miletic. Publisher: Springer; 1st edition, 2018. – 327 p.
4. Posterior Direct Restorations 1st Edition by Salvatore Scolavino, Gaetano Paolone. Publisher: Quintessence Pub Co; 1st edition, 2021. – 264 p.

5. Smile Design Integrating Esthetics and Function Essentials of Esthetic Dentistry Volume Two by Jonathan B. Levine. Elsevier Health Sciences, 2015. – 240 p.
6. Cohen's Pathways of the Pulp 12th Edition by Louis H. Berman, Kenneth M. Hargreaves. Publisher: Elsevier; 12th edition, 2020. –992 p.

## Lesson № 8

**TOPIC: Oral hygiene and its importance in the comprehensive prevention of diseases of the oral cavity and the body as a whole. Definition of GI according to Fedorov-Volodkina and Green-Vermillion (standard and simplified methods), oral hygiene efficiency index.**

**I. Topic relevance:** Oral hygiene is an integral part of the local prevention of major dental diseases.

Proper oral care and the rational use of hygiene products ensure the elimination of pathogens that cause destruction, and ultimately gingivitis, periodontitis and periodontal disease. Thus, oral hygiene prevents inflammation and tissue destruction.

**II. Study goal:**

**2.1. Student has to know:**

- To know what oral hygiene is;
- Know how to properly care for the oral cavity at home;
- Know the types and means of hygienic care;
- Know the types of hygiene indices;
- Know how to determine the GI according to Fedorov-Volodkina;
- Know how to determine the GI according to Green-Vermillion;

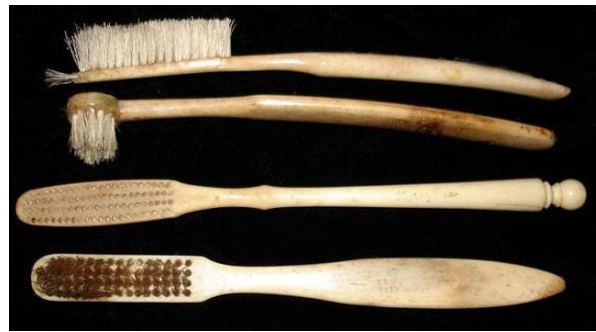**2.2 Be able to:**

- Know how to properly care for the oral cavity;
- Be able to distinguish between hygiene care products;
- Be able to identify GI by Fedorov-Volodkina;
- To be able to identify GI by Green-Vermillion;

**III. Content of the topic**

Preventive *oral hygiene* is a system of methods used to care for the oral cavity, as well as means aimed at preventing the development of pathological processes in the oral cavity.

Oral hygiene has existed since ancient times. There are descriptions of various tools used for this purpose: toothpicks, wooden sticks, tongue scrapers. The works of Hippocrates mention rinsing to eliminate bad breath. Resins, ground cocoa beans, white clay, talcum powder, pumice, coral and corundum powder, etc. were used to clean teeth.



The level of oral hygiene is inextricably linked to the intensity of dental pathology. In the oral cavity of a modern person, favourable conditions are created for the active development of microorganisms, whose waste products cause pathological processes in periodontal tissues and tooth enamel.

The most common dental diseases are caries, inflammatory and dystrophic periodontal disorders, diseases of the oral mucosa and salivary glands, and anomalies of the dentition. And while the latter are not directly related to poor hygiene, other dental pathologies, according to the results of many studies, are necessarily associated with a negligent attitude to hygiene.

Poor oral hygiene affects various body systems through bacterial infections and inflammatory processes that spread through the circulatory system. Here are some of the organ systems that can be affected by poor oral hygiene:

1. **Cardiovascular system:** Bacterial infections and inflammatory processes that start in the oral cavity enter the circulatory system and cause inflammatory reactions in the arteries. This can lead to a risk of heart disease, such as endocarditis (inflammation of the inner lining of the heart).

2. **Respiratory system:** Inflammatory processes in the oral cavity spread to the upper respiratory tract and lungs, leading to inflammation and other diseases of the respiratory system.

Inflammatory processes that occur due to poor oral hygiene can affect different parts of the respiratory system.

*Here are some examples:*

**Gingivitis and periodontitis:** Inflammatory gum disease (gingivitis) and periodontitis (an inflammatory process that affects the tissues that support the teeth) can lead to the spread of inflammation to the upper respiratory tract. The inflammatory reactions can spread through the mucous membranes and aerosols produced during chewing and speaking and cause inflammation in the nasal cavities and larynx.

**Pharyngitis:** Inflammation in the upper mouth can lead to pharyngitis, an inflammation of the back of the throat. This can cause discomfort and sore throat, cough and other respiratory symptoms.

**Bronchitis and pneumonia:** Inflammatory reactions can spread further down the airways and cause inflammation of the bronchi (bronchitis) or even the

lungs (pneumonia). This can cause severe coughing, chest pain, shortness of breath and other unpleasant symptoms.

General impact on the immune system: Inflammatory processes that develop in the mouth due to poor hygiene can also affect the body's overall immunity. A deteriorating immune system can make you more vulnerable to respiratory diseases.

3. Periodontium (The support system for the teeth/tissue around the tooth): Inflammation of the gums and supporting tissues can lead to damage to the bones that support the teeth. This can lead to tooth loss and other problems with the structure of the mouth.

4. Digestive system: The initial stage of food digestion takes place in the mouth under the influence of saliva and enzymes. Inflammatory processes can affect this process and cause problems with the gastrointestinal tract.

5. General condition of the body: The general inflammatory state of the body caused by inflammatory processes in the oral cavity can affect the overall health, immunity and overall resistance to disease.

Hygiene items include toothbrushes, dental floss, tongue cleaners, oral irrigators, dental brushes, interdental stimulators, and items for the care of removable orthopaedic and orthodontic structures.

#### Toothbrushes

A toothbrush is a device for brushing teeth and gum massage. It is used with toothpaste. Modern toothbrushes come in a variety of shapes. Their working surface consists of synthetic or natural fibres of different sizes and stiffness.

#### **Toothbrushes are divided into:**

1. By the type of bristles:

- with natural bristles
- with synthetic smooth bristles
- with synthetic microtextured bristles

2. By the stiffness of the bristles:

- very soft
- soft
- medium hardness
- hard
- very hard

3. By the number of rows of bristles:

- four-row
- three-row
- two-row (sulcular - for cleaning the gingival sulcus)
- single-bunch (used when it is impossible to clean with a large head brush)

4. By the size of the working part:

- children's
- teenagers

- adults
- special purpose
- single beam

5. By the method of actuation:

- manual
- automatic (electric)

6. By purpose:

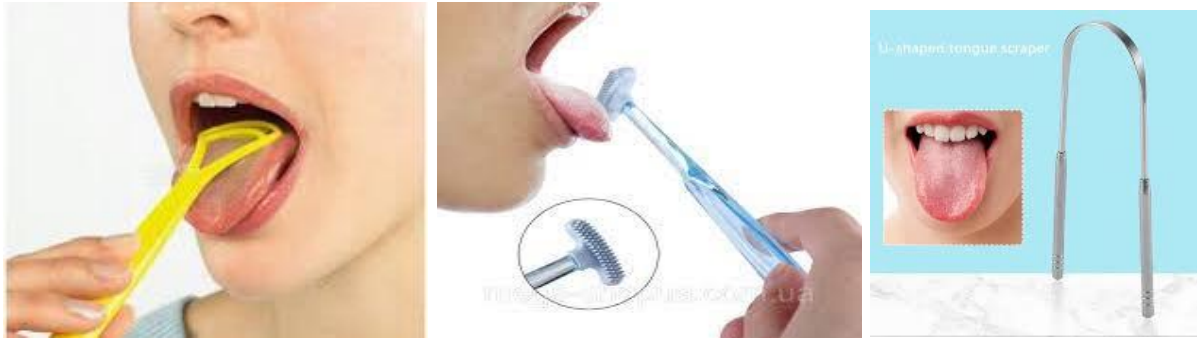- standard
- orthodontic (with a middle recess for the orthodontic arch)
- special purpose (after surgical interventions)



### **Tools for cleaning the back of the tongue**

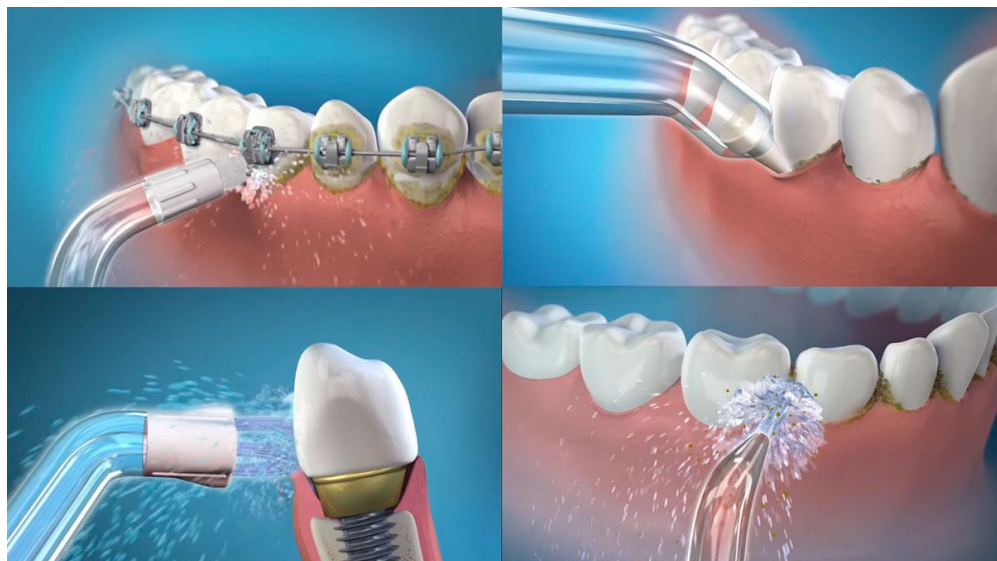
The most popular hygiene items are spoons and tongue scrapers. They are made of plastic with a rounded tip that does not cause a gag reflex. Scrapers have soft bristles at the end for more effective cleaning. A regular toothbrush, an electric toothbrush, or an irrigator with a special nozzle are also suitable. The main thing to remember is that tongue cleaning is an addition to oral hygiene, but not its main stage.





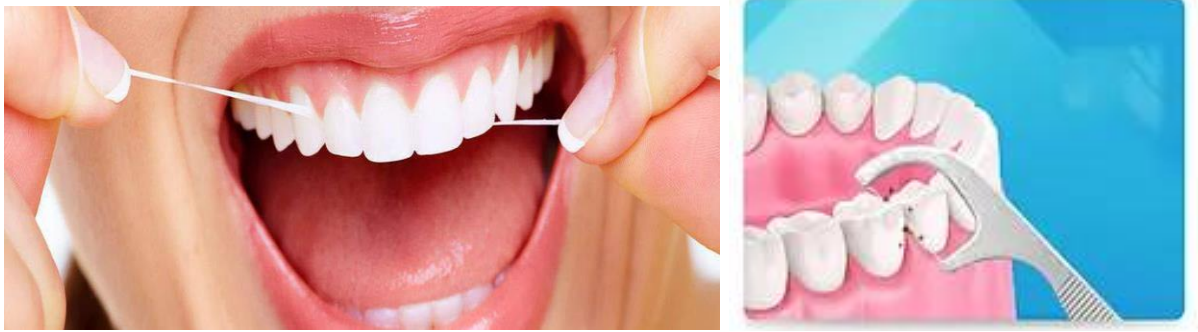### **Oral irrigators (electric hydromassagers)**

They have the form of nozzles that deliver a jet of liquid under pressure, which is pre-poured into a reservoir. The force of the liquid flow is adjustable. The jet can be centred ("jet" mode) or sprayed ("shower" mode), continuous or pulsating. When operating in the "jet" mode, food debris and partially soft plaque are washed away from the surfaces of the teeth, interdental spaces, gums, tongue, and SOPD under high pressure; when operating in the "shower" mode, the gums, SOPD, and tongue are massaged, resulting in normalised peripheral blood circulation. Effective for periodontal and OSA diseases.



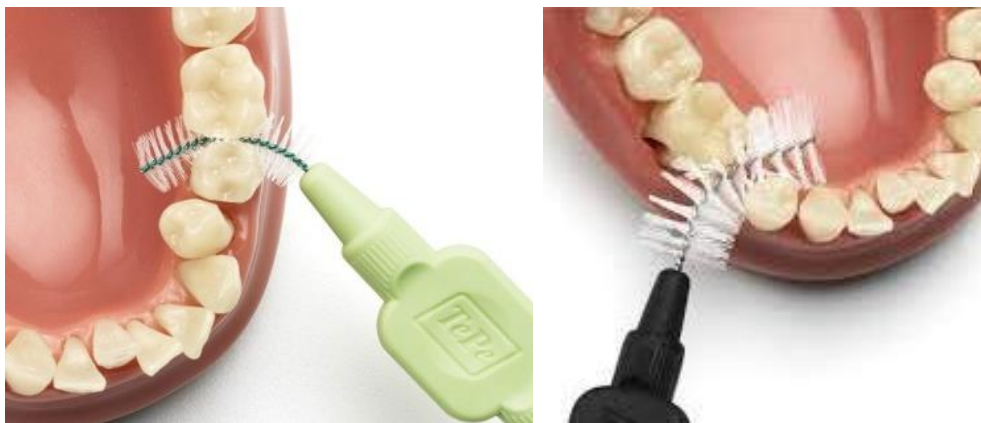### **Dental floss**

Designed for cleaning interdental spaces. The floss is effective in narrow, difficult-to-clean interdental spaces, crowded teeth, periodontal disease, fixed orthopedic and orthodontic structures in the oral cavity, implants, and apical fillings.



### **Interdental brushes**

Designed for cleaning wide interdental spaces, spaces under fixed orthodontic arches, areas under the flushing parts of bridges and spaces between implants and dentures, as well as exposed bifurcations and trifurcations of teeth.



### **Methods of brushing your teeth**

The standard method of brushing your teeth. The dentition is conventionally divided into several segments (3 segments on each jaw): two segments for molars and premolars, one segment for canines and incisors. Teeth and gums cleaning starts with the upper right large angular teeth and continues towards the upper left molars. The teeth are cleaned sequentially on the upper and then on the lower jaw.

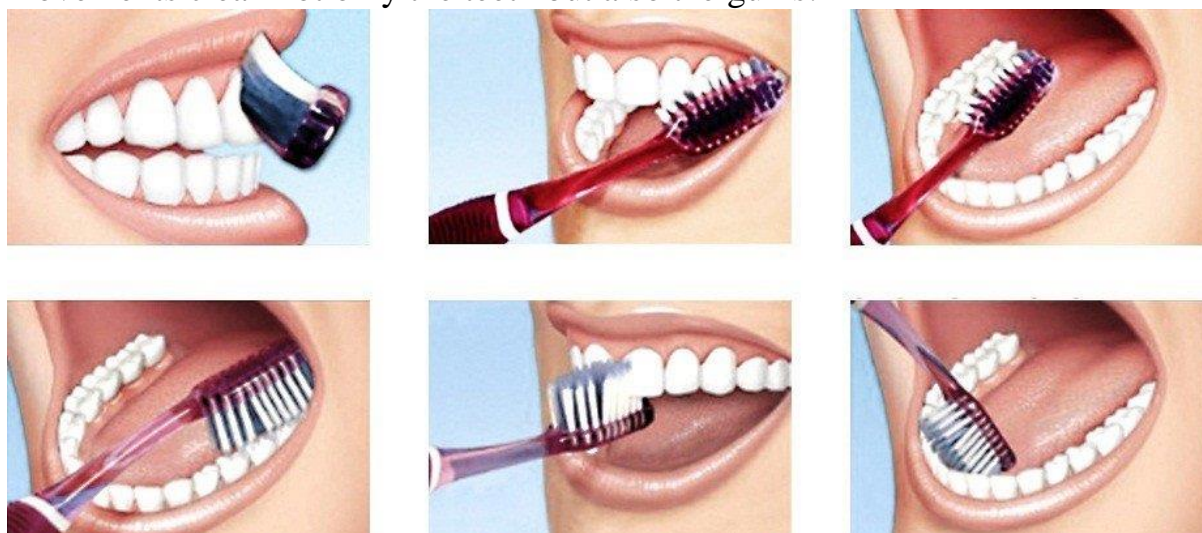
When brushing the buccal surfaces of the large and small angular teeth of the upper and lower jaw, the brush bristles should be directed at an acute angle to the tooth surface.

"Using a downward sweeping motion for the upper jaw and an upward sweeping motion for the lower jaw, plaque is removed from the gums at the same time. Then make several horizontal (back and forth) movements, and finish brushing in a circular motion, with pressure applied to the brush when it passes from the gums and rubs against the tooth. Then a counter semicircle is performed without pressure to return the brush to its original position. After that, the toothbrush is moved forward one segment and the entire combination of

movements is repeated. The chewing surfaces of the large and small angular teeth of the upper and lower jaws are cleaned with brush bristles directed perpendicular to the occlusal plane (penetrating deep into the fissures and interdental spaces) with horizontal movements of the brush head (without changing its position) back and forth.

The palatal surfaces of the large and small angular teeth of the upper jaw and the lingual teeth of the lower jaw are cleaned in the same way as the buccal surfaces. When brushing the buccal surfaces of the upper and lower anterior teeth, use the same movements as when brushing the buccal surfaces of molars and premolars.

When brushing the palatal surfaces of the upper and lingual surfaces of the lower anterior teeth, hold the brush handle parallel to the occlusal plane, with two or three bundles of bristles covering the teeth and gums. Horizontal movements are performed. Then, the position of the brush is changed so that the brush head is directed perpendicular to the occlusal plane of the teeth, and the bristles are at an acute angle to them and reach part of the gum. Up and down brushing movements clean not only the teeth but also the gums.



*The method of brush rotation.* The brush bristles are placed on the gum mucosa. The brush is moved in a rotating motion to the crown of the tooth. This operation is performed 10-12 times in each segment of the dentition.

*Leonard's method.* The toothbrush is placed perpendicular to the surface of the teeth, and vertical movements are made only in the direction from the gums to the tooth crown: on the upper jaw from top to bottom, on the lower jaw from bottom to top. Such movements avoid damage or refraction of the gums. The vestibular surfaces of the teeth are cleaned with the teeth closed, the chewing surfaces are cleaned by moving the brush back and forth.

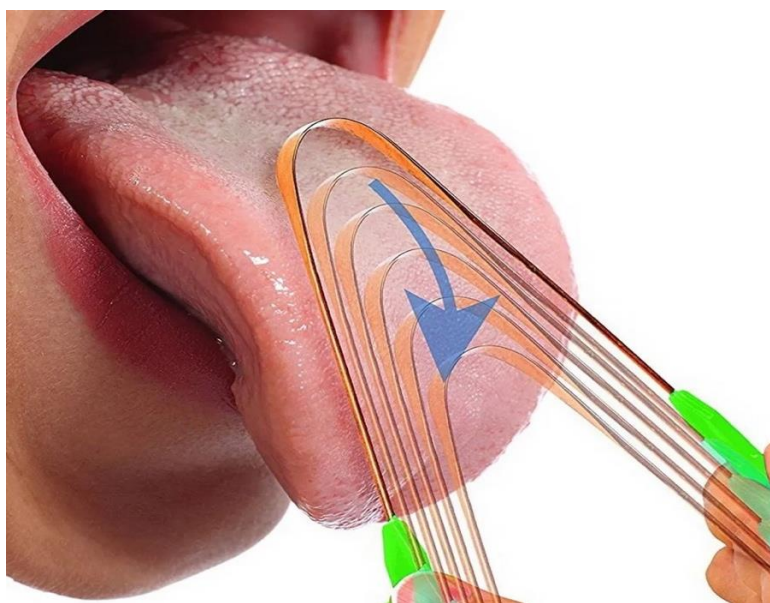
*Reite method.* The brush bristles are placed parallel to the tooth axis, with their free ends touching the gum margin. When brushing, evacuation movements are performed from the gums to the tooth crown. At the end of the movement, the bristles are set at right angles to the tooth axis. The process is repeated. Lingual

surfaces are cleaned in the same way, chewing surfaces - by moving the brush back and forth.

*Bass method.* The bristles of the brush should be at an angle of  $45^{\circ}$  to the tooth axis, with the ends of the bristles partially falling into the gingival sulcus and interdental spaces. When brushing, make vibrating movements back and forth without moving the tips of the bristles. A number of mistakes are possible here: incorrect positioning of the toothbrush head to the surface of the teeth and gums, incorrect brushing motion, i.e., the transition to horizontal movements. Internal surfaces are cleaned in the same way. Chewing surfaces, as with other methods, are cleaned by moving the toothbrush back and forth.

*Brushing the tongue.* The plaque on the tongue is a combination of a thin epithelial film that has not had time to renew, food debris and microorganisms. Therefore, dysbiosis may result in an unpleasant taste or breath.

It should be cleaned twice a day after brushing your teeth. Proper tongue cleaning begins at the root of the tongue, where the largest number of bacteria accumulates. Use gentle pressure to move from the root of the tongue to its tip, and then work the side surface, right and left. Finally, rinse your mouth with water or mouthwash.



One of the indicators of oral hygiene is the hygiene index. It is an assessment of plaque and calculus, as well as the general condition of teeth and gums. Standard clinical and simplified methods of determining the hygiene index allow you to get an objective overview of the condition of your teeth and suggest the need for additional procedures/measures/manipulations.

*Standard clinical method for determining the hygiene index:*

This methodology is based on a detailed examination of the condition of the teeth and gums using clinical examination indicators. It includes an assessment of plaque and calculus on the teeth, the degree of gum disease, and

the general condition of the teeth. The technique can use special instruments to examine the teeth and measure hygiene indicators. The hygiene index is calculated based on the results of this examination.

*Simplified method of determining the hygiene index:*

This method involves using fewer observational indicators to assess hygiene status. It may include assessing the presence of plaque on specific teeth or groups of teeth, without the detailed examination required by the standard clinical method. This technique can be used to quickly assess the hygiene status in some cases, for example, during a routine examination.

**Hygiene indices**

To objectively assess the hygienic state of the oral cavity, indices are used, which can be divided into 4 groups:

- 1 - indices that assess the area of plaque;
- 2 - indices assessing the thickness of plaque;
- 3 - indices that estimate the mass of plaque;
- 4 - indices that assess the physical, chemical, microbiological parameters of plaque.

In the clinic, the indices belonging to groups 1 and 2 are more often used, due to their sufficient information content and ease of implementation.

Hygiene performance indices, such as the Fedorov-Volodkin and Green Vermillion indices, and the Silence Lowe index, make it possible to assess hygiene results and correct the home (individual) care strategy.

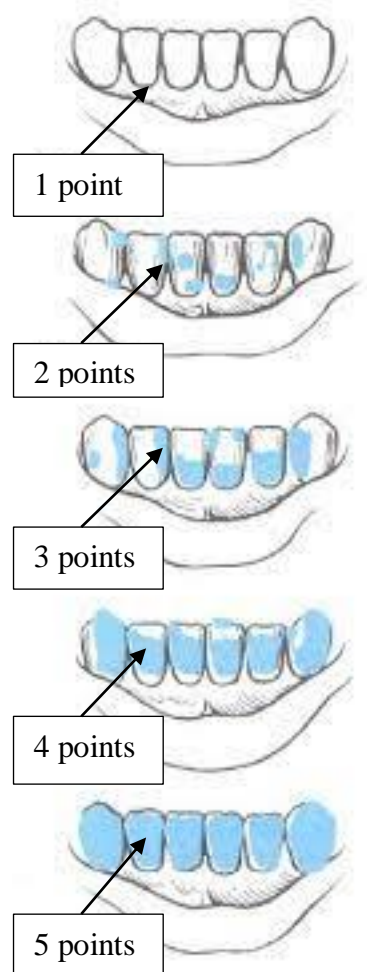
**The Fedorov-Volodkina Hygiene Index (HI) (1970)**

To determine the Fedorov-Volodkina oral hygiene index, the vestibular surfaces of the 6 anterior teeth of the lower jaw are lubricated with a solution of iodine and potassium iodide (crystalline iodine 1 g, potassium iodide 2 g, distilled water 40 ml). Quantitative assessment is carried out on a five-point scale:

- |   |   |
|---|---|
| <ul style="list-style-type: none"> <li>- staining the entire surface of the crown - 5 points;</li> <li>- 1/4 of the surface - 4 points</li> <li>- 1/2 of the surface - 3 points</li> <li>- 3/4 of the surface - 2 points</li> <li>- no staining - 1 point.</li> </ul> | <p>Assessment of the hygienic condition of the oral cavity:</p> <ul style="list-style-type: none"> <li>o 1.1-1.5 points - good;</li> <li>o 1.6-2.0 points - satisfactory;</li> <li>o 2.1-2.5 points - unsatisfactory;</li> <li>o 2.6-3.4 points - poor;</li> <li>o 3.5-5.0 points - very poor.</li> </ul> |
|---|---|

The average value of the index is calculated by the formula:

***GI = the sum of all teeth indicators/6***



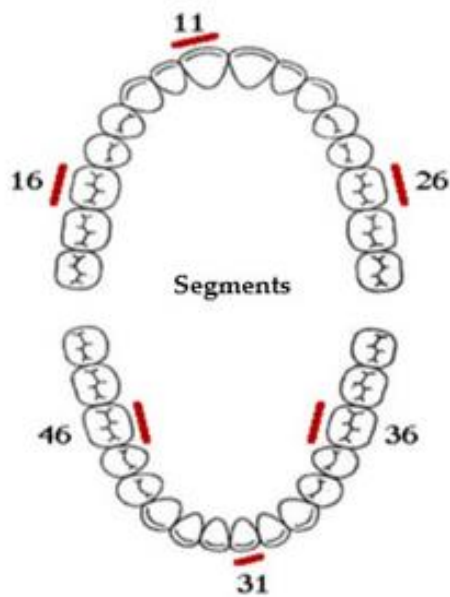
The qualitative assessment of the hygiene index is based on a three-point system:

- o 1 point - no staining;
- o 2 points - weak staining of the tooth crown surface;
- o 3 points - intense staining.

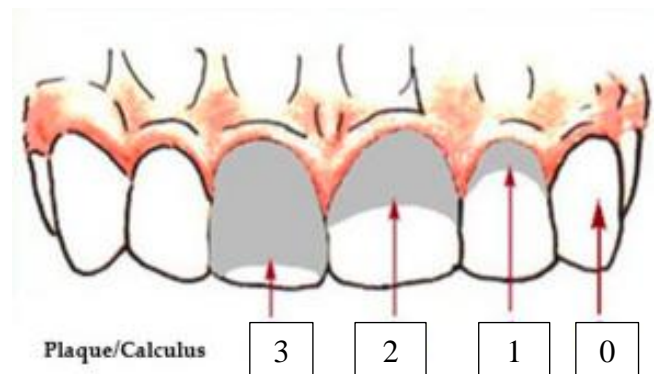
Normally, the hygiene index should not exceed 1.

Hygiene index ONI-S Green-Vermillion (1964)

A simplified index of oral hygiene. To do this, determine the presence of plaque and tartar on the buccal surface of 11, 16, 26, 31 teeth, lingual surface of 36, 46 teeth after staining them with Schiller-Pisarev solution.



- On all surfaces, plaque is first determined and then tartar. The following scores are used:
  - 
  - 0 - no plaque;
  - 1 - plaque covers no more than 1/3 of the tooth surface;
  - 2 - plaque covers 1/3 to 2/3 of the tooth surface;
  - 3 - plaque covers more than 2/3 of the tooth surface.



The plaque index (PI) is determined by the formula:

$$PI = \frac{\text{Sum of 6 teeth}}{6}$$

A score of 3 indicates unsatisfactory oral hygiene, and 0 indicates good oral hygiene.

The tartar index (TI) is assessed in the same way as plaque:

- 0 - no calculus;
- 1 - supragingival calculus on 1/3 of the tooth surface;
- 2 - supragingival calculus on 1/2 of the crown surface or some areas of supragingival calculus;

- 3 - supragingival calculus covers more than the tooth surface, subgingival calculus encircles the neck of the tooth.

CPI = Sum of 6 teeth/6

Simplified hygiene index = HI + HPI.

#### **IV. Control questions for the class topic:**

1. What is oral hygiene?
2. How to properly care for the oral cavity at home?
3. What oral hygiene items do you know?
4. What are hygiene indices and how do you calculate them?
5. How to evaluate the Fedorov-Volodkina HI?
6. How to assess GI according to Green-Vermillion?

#### **V. Control test tasks and/or case tasks:**

1. Hygiene items include what?
  - A. Toothbrushes;
  - B. Dental floss;
  - C. Toothpastes;
  - D. A tongue scraper;
  - E. All of the above.

**The correct answer is: D.**

2. Toothbrushes are used for cleaning:
  - A. Gums;
  - B. Cheeks;
  - C. Teeth;
  - D. Interdental gaps;
  - D. Tongue.

**The correct answer is: C.**

3. Irrigators in oral hygiene are used to:
  - A. Massage the gums;
  - B. Wash away food debris;
  - C. Prevention of dental diseases;
  - D. Wash away soft plaque from the tooth surface;
  - E. All answers are correct.

**The correct answer is: D.**

4. What is the method of brushing teeth according to Leonard?

**The correct answer is:** The toothbrush is placed perpendicular to the surface of the teeth, making vertical movements only in the direction from the gums to the crown of the tooth: on the upper jaw from top to bottom, on the lower jaw from bottom to top. Such movements avoid damage or refraction of the gums. The vestibular surfaces of the teeth are cleaned with the teeth closed, the chewing surfaces are cleaned by moving the brush back and forth.



5. What is the Bass method of toothbrushing?

**The correct answer:** The bristles of the brush should be at an angle of 45° to the tooth axis, with the ends of the bristles partially falling into the gingival sulcus and interdental spaces. When brushing, make vibrating movements back and forth without moving the tips of the bristles. A number of mistakes are possible here: incorrect positioning of the toothbrush head to the surface of the teeth and gums, incorrect brushing motion, i.e., the transition to horizontal movements. Internal surfaces are cleaned in the same way. Chewing surfaces, as with other methods, are cleaned by moving the toothbrush back and forth.

6. What is the correct way to clean the tongue?

**Correct answer:** It should be cleaned twice a day after brushing your teeth. Proper tongue cleaning begins at the root of the tongue, where the largest number of bacteria accumulate. First, you should use gentle pressure to move from the root of the tongue to its tip, and then work on the side surface, on the right and left. Finally, rinse your mouth with water or mouthwash.

#### LIST OF REFERENCES

##### Main literature

1. Stomatology: textbook: in 2 books. Book I / M.M. Rozhko, Z.B. Popovych, V.D. Kuroiedova et al.: edited by M.M. Rozhko. – Kyiv: AUS Medicine Publishing, 2020. – 792 p.: color edition.
2. Periodontal and Oral Mucosa Diseases: textbook. Vol. 2 / A.V. Borsenko, L.V. Lynovytska, O.F. Nesyn et al.; edited by A.V. Borysenko. - Kyiv: AUS Medicine Publishing, 2018. – 624 p.; color edition.
3. Stomatology: textbook: in 2 books. Book 2 / M.M. Rozhko, I.I. Kyrylenko, O. H. Denysenko et al.; edited by M. M. Rozhko. – Kyiv: AUS Medicine Publishing, 2018. – 960 p.; color edition.

##### Additional literature

1. Esthetic Dentistry: A Clinical Approach to Techniques and Materials 3rd Edition by Kenneth W. Aschheim. Publisher: Mosby; 3rd edition, 2014. – 600 p.
2. Esthetic and Restorative Dentistry: Material Selection and Technique 3rd Edition by Douglas A Terry, Willi Geller. Publisher: Quintessence Publishing Co Inc.; 3rd edition, 2017. – 776 p.
3. Dental Composite Materials for Direct Restorations Softcover reprint of the original 1st ed. by Vesna Miletic. Publisher: Springer; 1st edition, 2018. – 327 p.
4. Posterior Direct Restorations 1st Edition by Salvatore Scolavino, Gaetano Paolone. Publisher: Quintessence Pub Co; 1st edition, 2021. – 264 p.

5. Smile Design Integrating Esthetics and Function Essentials of Esthetic Dentistry Volume Two by Jonathan B. Levine. Elsevier Health Sciences, 2015. – 240 p.
6. Cohen's Pathways of the Pulp 12th Edition by Louis H. Berman, Kenneth M. Hargreaves. Publisher: Elsevier; 12th edition, 2020. –992 p.

## Lesson № 9

**TOPIC: Plaque and tartar. Mechanism of formation. Structure, physical properties, chemical composition, microflora. Methods of removal. Carrying out professional oral hygiene. Evaluation of the effectiveness of plaque and tartar removal.**

**I. Topic relevance:** Numerous biochemical, epidemiological, microbiological studies in clinical and experimental conditions have established the pathogenetic significance of plaque and tartar in the development of caries and, consequently, inflammatory and dystrophic periodontal diseases.

### **II. Study goal:**

#### **2.1. Student has to know:**

- Know what plaque is;
- Know what tartar is;
- Know the mechanism of plaque and tartar formation;
- Know the physical properties and structure of dental plaque;
- Know the chemical composition and microflora of dental plaque;
- Know how to remove dental plaque
- Know how to correctly evaluate the effectiveness of removing dental plaque and calculus.

#### **2.2 Be able to:**

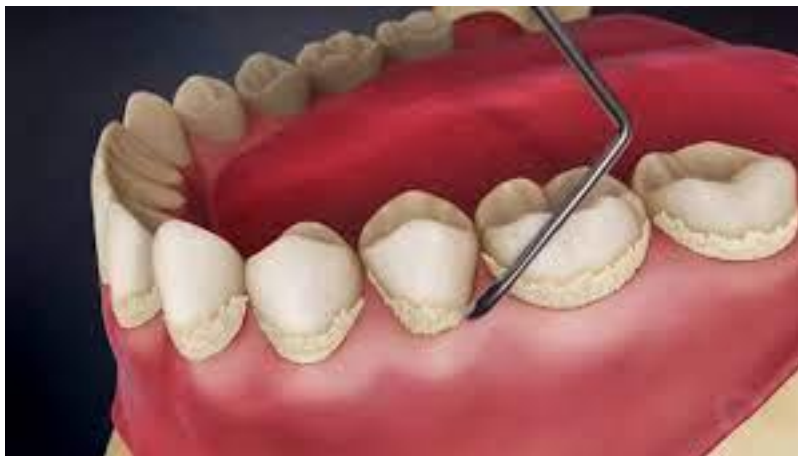- Be able to distinguish plaque from tartar;
- Be able to remove dental plaque using the Air Flow technique;
- To be able to remove tartar with ultrasound;
- To be able to care for the surface of the teeth after ultrasonic cleaning;
- Be able to correctly convey information about oral hygiene to the patient;
- Be able to evaluate the effectiveness of plaque and calculus removal.

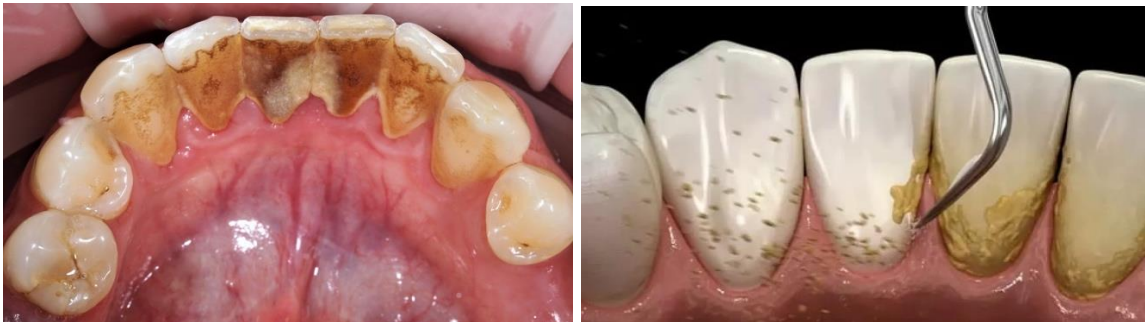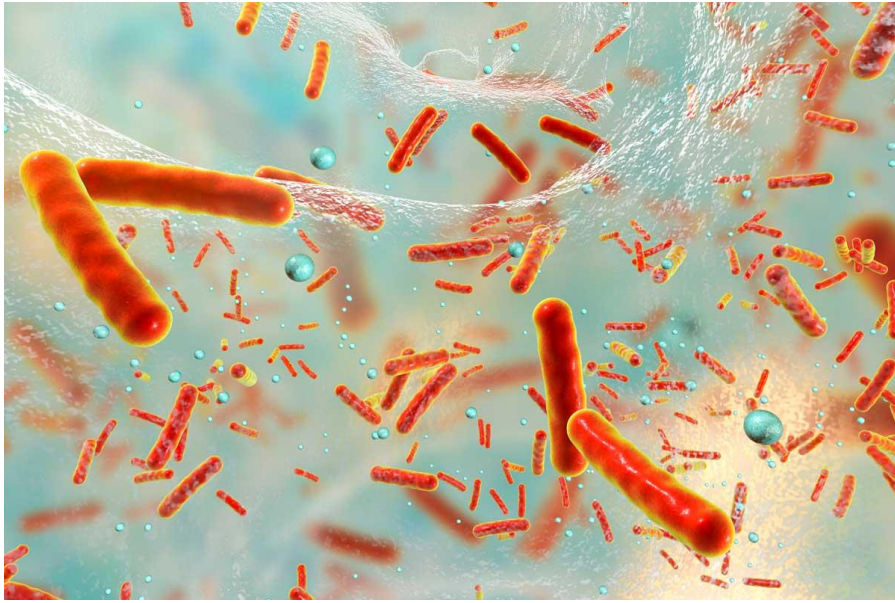### **III. Content of the topic**

The presence of plaque on the labial surfaces of the front teeth of toddlers (1-2 years) has been tested as a predictor of the development of caries lesions during the following 2-3 years, but the accuracy is poor (sensitivity 26%, specificity 88%). Children aged 1-3 years who brush their teeth with fluoride toothpaste at least once a day have a greater chance of remaining free of caries at age 3 than those with poor oral hygiene. However, as only one study on this topic was included, it is not possible to draw any conclusions about the frequency of tooth brushing as a predictor.

**Sensitivity test.** A further diagnostic aid is a sensitivity test. The detection of increased dental sensitivity can be an indication of hidden caries. The simplest way to perform this test is with cold spray, during which cotton wool is sprayed with a special, rapidly evaporating agent. Stronger pain can be triggered especially in teeth with acute pul-pitis but also in teeth with broad pulpal cavities (e.g. in young people). A further option is electrical pulpal irritation with special devices. If sensitivity cannot be triggered, this indicates a devital tooth. Direct dentinal stimulation (test cavity): The test cavity is an invasive procedure that is often used to ensure that a negative response to previous pulp tests was accurate. Because this test is invasive and requires removal of tooth structure and/ or restorative materials, it is used primarily to exclude false negative results. The test can be used in clinical cases in which a tooth does not respond to cold testing and EPT but lacks a distinct etiology for necrosis. In such cases direct dentinal stimulation can be used to reveal necrosis or establish vitality. Direct dentinal stimulation involves removing enamel or restorative materials using a high-speed handpiece without local anaesthesia. If the tooth is vital, the patient will experience a sharp, painful response when dentin is reached. Clinicians must caution patients that they will feel the sensations of vibration and pressure so that they can interpret the test correctly.

**Pulp testing** involves attempting to make a determination of the responsiveness of pulpal sensory neurons. The tests involve thermal or electrical stimulation of a tooth in order to obtain a subjective response from the patient (i.e. to determine whether the pulpal nerves are functional), or the tests may involve a more objective approach using devices that objectively detect the integrity of the pulpal vasculature.





Professional oral hygiene is a set of measures aimed at cleaning teeth, for which various techniques can be used. Almost every clinic can offer the following four:

- Air flow, or the so-called pearl brushing. The doctor directs a stream of air with water and crystals of a special powder mixture under high pressure onto the tooth. The procedure is available even if you have orthodontic structures (dentures, braces), crowns and implants, veneers and lumineers.
- Laser. It is a completely non-contact procedure, so it is suitable for teeth with high sensitivity. Each tooth is cleaned individually by directing a laser beam at it. In fact, a laser is a concentrated effect of sunlight.
- Ultrasound. The doctor uses a dental scaler (scaler) - a device with a tip that emits ultrasonic vibrations. They affect the enamel surface, gently chipping off tartar. The deposit is destroyed as if inside the tooth and then washed off with water.
- Mechanical. The simplest type that is suitable for both adults and children. It is performed using a special brush attachment for a dental drill and paste. In this way, the doctor can remove soft plaque from each tooth, clean the

tooth enamel from dark spots, making it visually lighter. This method is considered the most gentle, this professional cleaning does not cause tooth sensitivity, but it is ineffective for interdental spaces.

### **Indications for professional oral hygiene.**

According to WHO statistics, about 92% of people do not know how to brush their teeth properly. As a result, by the age of 30, more than 60% of patients start using dentures. In this case, professional dental cleaning comes to the rescue. This is a preventive procedure for maintaining oral health performed by a dentist. It allows you to:

- remove plaque (both soft and hard) and prevent its deposition for some time;
- restore the teeth to their natural colour, which the enamel has lost as a result of smoking and contact with food dyes (i.e., in fact, whitening)
- strengthen the enamel, i.e. reduce or eliminate tooth sensitivity;
- reduce the likelihood of developing dental diseases by at least 50%;
- restore fresh breath.

*General situations in which a patient should limit himself to home oral hygiene and cannot afford professional care are as follows*

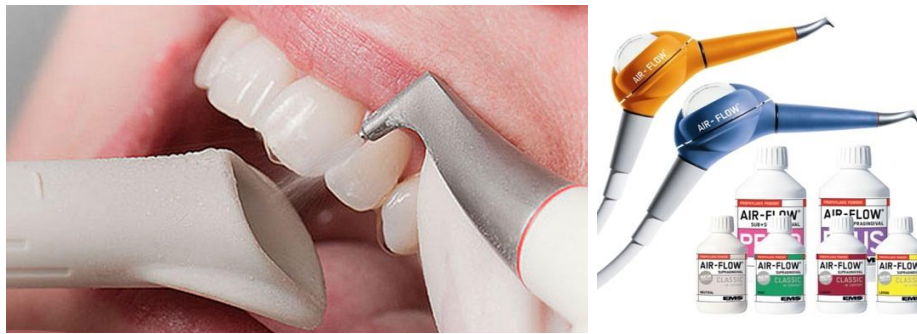- Pregnancy and breastfeeding;
- very high sensitivity of the enamel;
- the presence of bronchitis or bronchial asthma;
- severe infectious diseases;
- cardiovascular pathologies;
- mental disorders, etc.

### **How the Airflow method works.**

An overpressure is created in the chamber of the Air flow device, where powder granules of a certain size are located. As a result, the mixture formed from water, air and powder flies out of the nozzle. This water-air mixture and powder are exposed to the tooth and surface cleaning takes place. The waste ingredients, along with plaque, are captured and removed by a dental vacuum cleaner.

### **There are several types of powder used in Air flow technology.**

- Sodium bicarbonate (baking soda) with a certain particle size and flavouring. A classic option that has been used in Air flow technology for a long time. It has the ability to clean well, but in some patients it can cause temporary gum irritation.
- Calcium carbonate with regular shaped particles. It cleans teeth well and gently, polishes perfectly and does not irritate the oral mucosa.
- Glycine, an amino acid that is highly soluble in water. The powder has a pleasant taste, is low-abrasive, and polishes the surface of teeth very gently. Air flow with glycine can be used more than twice a year.



Air flow does not remove tartar and subgingival plaque, for this purpose an ultrasonic scaler is used. Air flow only brightens and restores the natural colour of the teeth by removing plaque and tartar.

Ultrasonic teeth cleaning allows you to remove all dental plaque in 1-3 sessions. The procedure is performed using a special ultrasonic scaler in the dentist's office. It is absolutely painless and takes no more than an hour per visit.

Ultrasonic tartar removal is used as an independent procedure and as an initial stage of the general sanitation of the oral cavity.

If the patient has no complaints, except for dark plaque on the teeth, it is possible to limit the removal of dental plaque and appropriate recommendations. In cases where additional treatment is required, professional ultrasonic teeth cleaning is an appropriate procedure.

**Indications for ultrasonic teeth cleaning include**

- the presence of mineralised and unmineralised dental plaque on the teeth, which cannot be removed on their own;
- sanitation (complete treatment) of the mouth;
- periodontal diseases.

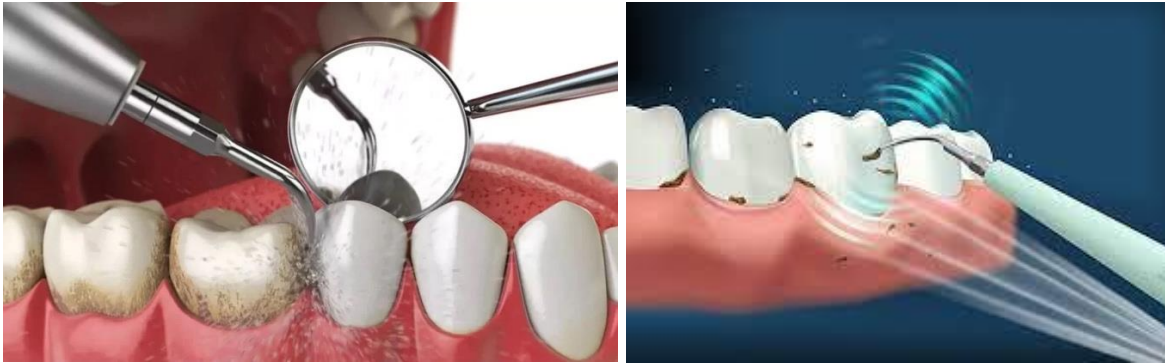**Contraindications:**

- presence of orthopedic structures and implants in the oral cavity;
- presence of infectious, viral diseases (HIV, TB, hepatitis);
- respiratory infections;
- cardiac arrhythmia;
- hyperesthesia of the teeth (hypersensitivity);
- patient complaints of chronic bronchitis, endocarditis or asthma.

Some dentists still practice calculus removal with an iron. But this procedure can hardly be called "professional cleaning". Manipulations with hand-held dental instruments resemble rough chipping, which results in

- scratches
- cracks
- Remnants of dental plaque;
- injured gingival margin.

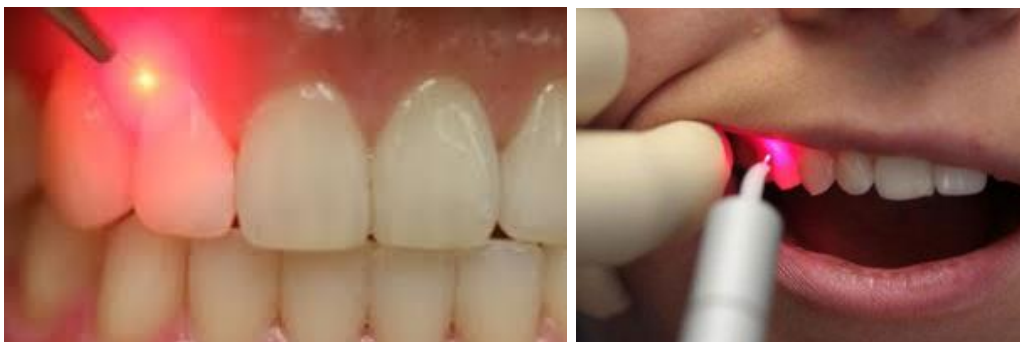Ultrasonic teeth cleaning helps to avoid such troubles. The scaler removes mineralised dental plaque even in the most inaccessible places. Since ultrasound is the main acting factor, there is no damage to the teeth or gums from the instrument.



### Laser teeth cleaning

Professional laser cleaning helps to effectively remove soft plaque and tartar, and is quick and painless. The beam is directed at the tooth surface, the laser evaporates moisture from dental plaque, as a result of which it becomes brittle and easily washed away under a stream of water.

The use of a laser device requires special knowledge from a specialist, and not every clinic has such a device, which is why the price for this service is quite high.



#### IV. Control questions for the class topic:

1. What is the role of oral hygiene in the comprehensive prevention of caries and its complications, periodontal tissue diseases?
2. What methods of oral hygiene do you know?
3. Types of dental plaque: composition, structure.
4. The mechanism of formation of plaque and calculus.
5. Methods of removing dental plaque.
6. The concept of professional oral hygiene. Methods of evaluating its effectiveness.

#### V. Control test tasks and/or case tasks:



1. A complex formation, where the main role is played by uncalcified bacterial masses that are closely adjacent to the tooth surface, is:

- A. Tartar;
- B. Plaque;
- C. Mature dental plaque;
- D. Pelicle;
- D. Cuticle.

**The correct answer is: B.**

2. What develops from several days of plaque:

- A. Dental plaque;
- B. Pelicula;
- C. Tartar;
- D. Plaque;
- E. Cuticle

**The correct answer is: A.**

3. The transition of plaque to tartar occurs through:

- A. 1 - 2 days;
- B. 2 - 5 days;
- C. 5 - 7 days
- D. 7 - 10 days;
- E. more than 10 days.

The correct answer is: D.

4. What is a biofilm?

**The correct answer is:** A biofilm is an active biological entity that interacts with the human body in a complex state. Various types of bacteria that make up the biofilm do not act in single colonies, but work together, acquiring new special qualities that are not characteristic of separately existing bacteria of the same species. The oral biofilm is complex, consisting of multiple - from 50 to 300 - complex layers of cells that are placed one above the other. Colonies of bacteria have a filamentous, mushroom and tower-like shape. Their ability to move depends on the shape of the colony. The biofilm actively develops on closed surfaces where self-cleaning is poor: fissures, cervical and approximal surfaces of teeth and its formation is a constantly ongoing dynamic process.

5. What is the cycle of biofilm formation?

**Correct answer:** The formation of biofilm can be divided into 3 phases:

- 1 - deposition of salivary hypoproteins on the tooth surface - pellicles - occurs a few minutes after active brushing. This process is obviously genetically determined;
- 2 - primary colonisation by gram-positive bacteria and preparation of conditions for the next phase of colonisation. This phase begins 1 hour after active brushing;
- 3 - secondary colonisation by various, including pathogenic, strains of bacteria and internal: maturation of the structure.

6. During professional oral hygiene, a dentist removes tartar. What instrument does he use and what is the next step?

**Correct answer:** Ultrasonic teeth cleaning allows you to remove all dental plaque in a few The procedure is performed using a special ultrasonic scaler in the dentist's office. The scaler removes mineralised dental plaque even in the most inaccessible places. Since ultrasound is the main acting factor, not even minimal damage is left on the teeth or gums by the instrument. After ultrasonic calculus removal, the teeth require special care. The teeth are polished with a special paste, brush, dental gums and discs. This procedure makes the surface of the teeth smoother.

6. What is professional oral hygiene using the Air Flow technique?

**Correct answer:** This is the cleaning of tooth surfaces with a special apparatus. An overpressure is created in the chamber of the Air flow device, where powder granules of a certain size are located. As a result, the mixture formed from water, air and powder flies out of the nozzle. This water-air mixture and powder are exposed to the tooth and surface cleaning takes place. The waste ingredients, together with plaque, are captured and removed by a dental vacuum cleaner.

#### LIST OF REFERENCES

##### Main literature

1. Stomatology: textbook: in 2 books. Book I / M.M. Rozhko, Z.B. Popovych, V.D. Kuroiedova et al.: edited by M.M. Rozhko. – Kyiv: AUS Medicine Publishing, 2020. – 792 p.: color edition.
2. Periodontal and Oral Mucosa Diseases: textbook. Vol. 2 / A.V. Borsenko, L.V. Lynovytska, O.F. Nesyn et al.; edited by A.V. Borysenko. - Kyiv: AUS Medicine Publishing, 2018. – 624 p.; color edition.
3. Stomatology: textbook: in 2 books. Book 2 / M.M. Rozhko, I.I. Kyrylenko, O. H. Denysenko et al.; edited by M. M. Rozhko. – Kyiv: AUS Medicine Publishing, 2018. – 960 p.; color edition.

##### Additional literature

1. Esthetic Dentistry: A Clinical Approach to Techniques and Materials 3rd Edition by Kenneth W. Aschheim. Publisher: Mosby; 3rd edition, 2014. – 600 p.
2. Esthetic and Restorative Dentistry: Material Selection and Technique 3rd Edition by Douglas A Terry, Willi Geller. Publisher: Quintessence Publishing Co Inc.; 3rd edition, 2017. – 776 p.
3. Dental Composite Materials for Direct Restorations Softcover reprint of the original 1st ed. by Vesna Miletic. Publisher: Springer; 1st edition, 2018. – 327 p.
4. Posterior Direct Restorations 1st Edition by Salvatore Scolavino, Gaetano Paolone. Publisher: Quintessence Pub Co; 1st edition, 2021. – 264 p.

5. Smile Design Integrating Esthetics and Function Essentials of Esthetic Dentistry Volume Two by Jonathan B. Levine. Elsevier Health Sciences, 2015. – 240 p.
6. Cohen's Pathways of the Pulp 12th Edition by Louis H. Berman, Kenneth M. Hargreaves. Publisher: Elsevier; 12th edition, 2020. –992 p.

**MODULE 2: «LESIONS OF THE HARD TISSUES OF THE TEETH.  
CARIES AND NON-CARIOUS LESIONS OF THE TEETH»**

**Lesoon №1**

**TOPIC: Tooth caries. Definition of the concept. Statistical indicators of of tooth caries. Classification of caries. The concept of structural and functional resistance of hard tissues of the tooth. Determination of enamel resistance (TER test).**

**I. Topic relevance:** As a human disease, caries has been known since ancient times, with reliable information about the disease found in written sources dating back to about 3000 BC. At that time, caries was not yet widespread, but in a later era (the Middle Ages), its prevalence began to increase. This is associated with changes in people's diet and environmental and living conditions. This is due to a number of factors: the nature of the diet (primarily an excess of carbohydrates and a relative lack of protein in the diet), the content of fluoride and other macro- and microelements in drinking water, and social and climatic conditions.

**II. Study goal:**

**2.1. Student has to know:**

- Know the definition of dental caries;
- Know the classification of caries;
- Know what caries prevalence is and how to calculate it;
- Know what caries intensity is and how to calculate it;
- Know what caries incidence (caries growth) is.
- Know what hard tooth tissue resistance is;
- Know how to perform the TER test correctly.

**2.2 Be able to:**

- Be able to classify caries;
- Be able to determine the prevalence of caries in a patient;
- Be able to determine the intensity of caries in a dental patient;
- Be able to determine the growth of caries of the patient;
- Be able to determine the resistance of hard tooth tissues to caries in a patient.
- To be able to conduct a TER test for a dental patient.

**III. Content of the topic**

When the three essential parameters for dental caries - cariogenic organisms, susceptible teeth and a suitable local substrate — exist in an individual for a considerable time, then dental caries may develop. Caries causes damage by

demineralization and dissolution of tooth structure, resulting from (1) a highly localized drop in the pH at the plaque-tooth interface and (2) tooth demineralization. The local pH drop occurs as the result of plaque metabolism, but only plaque communities with high concentrations of MS and lactobacilli can produce a sufficiently low pH to cause demineralization of teeth. A single exposure of sucrose solution to a cariogenic plaque results in rapid metabolism of the nutrients to organic acids. The organic acids (primarily lactic acid) dissociate to lower the local pH. Single events of lowered pH are not sufficient to produce significant changes in the mineral content of the surfaces of the teeth. However, many episodes of long-duration demineralization (lowered pH), occurring over long periods of time, will produce the characteristic lesions of caries. Frequent sucrose exposure is the single most important factor in maintaining a pH depression at the tooth surface, often resulting in demineralization. The output (production) of acid from caries-active plaques is twice that of caries-inactive plaques per milligram wet weight of plaque. The production of acid from a caries-active plaque can overcome the buffering capacity of salivary bicarbonate available at the tooth-plaque interface, causing the local pH to fall. Once the pH falls below 5.5, tooth mineral is dissolved. At lower pH values, such as 3.0 or 4.0, the surface of enamel is etched and roughened. At a pH of 5.0, the surface remains intact while the subsurface mineral is lost. Cavitation of the surface occurs when the subsurface demineralization is so extensive that the tooth structure surface collapses. Cavitation of enamel is not reversible and is usually associated with the acceleration in the process of carious destruction of the tooth. It occurs when a series of demineralization (pH drop) and remineralization (salivary ions) episodes are dominated by the demineralization process.

There are three distinctly different clinical sites for caries initiation:

- (1) the recesses of developmental pits and fissures of enamel, which is the most susceptible site;
- (2) smooth enamel surfaces that shelter plaque;
- (3) the root surface

**CLASSIFICATION OF CARIES** The clinical features of caries are various enough: from the chalky white spot on the surface of enamel to the expressed destruction of hard tooth tissues. These numerous forms of caries, per se, are only consistently changing each other (in absence of treatment) stages of tooth destruction. The progress of caries lesion leads to the destruction of all bulk hard tooth tissues, perforation of pulp chamber and development of inflammation of pulp (pulpitis) or periodontal ligament (apical periodontitis). Therefore pulpitis and apical periodontitis, other tissues of maxillofacial region, which develop as a result of caries process named complications of caries. A caries may affect either one tooth or almost simultaneously several and even a row of teeth (numerous caries), then in such cases that is a basis to speak about cari-

ous illness. There is definite conformity with the law in localization of caries lesions. These are frequently affecting fissures, pits on the occlusal and contact surfaces of molars and premolars (bicuspid). On frontal teeth caries is localized more frequent on vestibular surfaces in neck areas. Characteristic in a caries development is the retention areas where food residues and microorganisms are most often accumulated. On the basis of clinical features and patterns, dental caries may be classified according to three basic factors: - Morphology, i.e. according to anatomical site of lesions. - Dynamics, i.e. according to severity and rate of progression of lesions. - Chronology, i.e. according to age patterns at which lesions predominate.

Classification Based on Morphology (Anatomical Site of Lesion). Occlusal (Pit and Fissure) and Smooth Surface Caries. Caries lesions can be classified according to their anatomical site. There is nothing chemically special about these sites; they simply reflect the location of a metabolically active biofilm. The most common and simplest classification of dental caries is based on relative susceptibility of surfaces of teeth.

The different surfaces of a tooth may be divided into two morphological types. Type I refers to pit, fissure and occlusal surfaces and type II refers to smooth surfaces of which there are two variations, interproximal and cervical or gingival. Pit and fissure caries are limited to the occlusal surfaces of molars and bicuspid, the buccal pits of molars, and lingual surfaces of maxillary anterior teeth (caries fissus or caries occlusus). These irregular surfaces are inherently more prone to dental caries due to their mechanical characteristics which result in poor self-cleansing features. Occlusal caries usually occur early in life before smooth surface lesions appear. Carious lesions located on surfaces other than pits and fissures are classified as type II, smooth surface lesions. Smooth surface lesions may be further subdivided as interproximal, occurring at mesial or distal contact points, or cervical, occurring on buccal or lingual surfaces near the dentin-enamel junction. The caries localization on the contact surfaces (mesial or distal contact points) of teeth is named the caries of contact surfaces or interproximal caries (caries approximatus s. contactus). Smooth-surface lesions may start on enamel (enamel caries) or on the exposed root cementum and dentin (root caries, caries cervicalis).

At the further progression of caries lesion on these areas (in particular case in baby teeth of weakened, diseased children) it formed specific localization of caries cavity: along the all neck of the tooth. Sometimes practically all neck of tooth is affected by caries like a ring. Such localization of caries named circular caries (caries annularis).

Primary caries is used to differentiate lesions on unrestored surfaces from those that develop adjacent to a filling, which are commonly referred to as recurrent or secondary caries. These two terms are synonyms. It is a carious lesion that develops at the interface of a restoration and the cavosurface of the enamel. Recurrent lesions may indicate an unusual susceptibility to caries attack, a poor

cavity preparation, a defective restoration or a combination of these factors. Residual caries is demineralized tissue that has been left behind before a filling is placed.

Caries lesions may also be classified according to their activity. This is a very important concept and one that impinges directly on management, although the clinical distinction between active and arrested lesions is sometimes difficult. A lesion considered to be progressive would be described as an active caries lesion. In contrast, a lesion that may have formed years previously and then stopped further progression is referred to as an arrested or inactive caries lesion.

There is clinical evidence that incipient and even more advanced carious lesions may become arrested if there is a significant shift in oral environmental conditions from those that predispose to those that tend to slow the caries process. A clinical feature of arrested caries involving dentin is the marked brown pigmentation and induration of the lesion. The first sign of a caries lesion on enamel that can be detected with the naked eye is often called a white-spot lesion. This appearance has also been described as an early, initial or incipient lesion. These terms are meant to say something about the stage of lesion development.

However, a white-spot lesion may have been present for many years in an arrested state and to describe such a lesion as early would be inaccurate. A dictionary definition of incipient is «beginning; nascent stage», in other words, an initial lesion appears as a white, opaque change (a white spot), but any white-spot lesion is not incipient. The terms remineralized or chronic lesions are sometimes used to signify arrested lesions, but the term remineralization should be used with caution. The distinction between active and arrested lesions may not be totally straightforward. Thus, there will be a continuum of transient changes from active to arrested, and vice versa. A lesion (or part of a lesion) may be rapidly progressing, slowly progressing or not progressing at all. This will depend entirely on the ecological balance in the biofilm covering the site and the environmental challenge.

**CLASSIFICATION BASED ON SEVERITY AND RATE OF CARIES PROGRESSION.** Dental caries may be classified according to the severity and rapidity of attack. The severity may be very mild to very severe or rampant (acute). Different teeth and surfaces are involved depending upon the severity of the caries challenge. In mild caries only the most vulnerable teeth and surfaces are attacked such as the occlusal surface of first permanent molars. In moderate caries the occlusal surfaces of other posterior teeth are involved as well as interproximal surfaces. In rampant caries surfaces of anterior teeth which are relatively less frequently attacked become carious. Rampant caries is a common and important manifestation of the disease in children and some adults and merits a further discussion.

*Rampant (acute) Caries:* One of the most distressful clinical conditions for both patient and practitioner is rampant caries in which there occurs a sudden, rapid and almost uncontrollable destruction of teeth. For an acute caries

characteristic is considerable demineralization of hard tooth tissues, relatively rapid progressing of caries lesion. The rampant (acute) caries has typical rapid (within the limits of a few weeks) course with rapid development demineralization of hard tooth tissues and caries lesions (caries defect of tooth crown).

Demineralization spread all over large areas of tooth surfaces - enamel and dentin. The affected enamel has a white chalky like colour, has not characteristic enamel translucency and becomes like a white spot.

These demineralized (friable) enamel margins easily broken during mastication of preparation of caries cavity by instruments (burs, excavators). The progression of caries lead to its spread out of the enamelodentinal junction results in development caries lesion in dentin.

Dentin has less mineralization than enamel so developing caries lesion in dentin formed more quickly. Thus a relatively large area of dentine is affected, in spite of an apparently small lesion in the occlusal surface with narrow opening and overhang margins.

Affected dentin is demineralized and softened, had cartilage like consistence and not practically changed in a colour (yellow or yellow-brown in colour). Such quickly caries progression during rampant caries, lead to considerable destruction of hard tooth tissues and spreading pathologic process into pulp and periodontal membrane. In some cases it is multiple active carious lesions occurring in the same patient.

Rampant caries also involves surfaces of teeth that are ordinarily relatively caries-free. A caries increment of 10 or more new carious lesions over a period of about a year is characteristic of a rampant caries attack. Proximal and cervical surfaces of anterior teeth, including the mandibular incisors which are relatively caries-free, may be affected.

Patients with rampant caries can be classified according to the assumed causality, e.g. bottle or nursing caries, baby caries, early childhood caries, radiation caries or drug-induced caries. Subjectively the rampant caries course is characterized by more expressed pain caused food irritants (sucrose or another chemical, thermal irritant).

Typically are multiple caries lesions. Such caries course often depended on low resistance of organism, systemic and concomitant diseases, and nutritional factors. Among them there are some physiologic conditions (adolescence, pregnancy), systemic exhausting diseases (tuberculosis, inflammatory processes in some inner organs), blood diseases, endocrine disorders and others. Some role play age of patient, anatomical features of different teeth (temporary or permanent dentition) and so on. A chronic caries develops for years, softening of hard tooth tissues expressed in less degree. The state of organism and constitutional factors, carried and concomitant diseases, unfavorable conditions of development in child's age, social conditions and others influence on a different



course of caries. These features cause the necessity of a different approach to their treatment. The chronic caries course has typical slow development caries lesion.

A pathologic process usually lasts for years; subjective pain feeling as a result of different irritants action is insignificant. The areas of demineralization of hard tooth tissues do not occupy such a considerable area as at the rampant caries course. As a result of penetration of food pigments into softened hard tooth tissues, the enamel and dentin become brown or black in colour. The typical for acute caries course overhang enamel margins are broken and formed wide caries cavity opening.

The softened and pigmented hard tooth tissues have more dense consistency, than at the acute caries course. The chronic caries course more often develops in practically healthy people with relatively insignificant violations of metabolic processes, nutritional disorders and so on. On such basis of satisfactory general organism condition the numerous caries lesions developed very rarely, more typically are single caries lesion. The long existence of caries cavity, lead to developing in pulp some defensive formations (for example, the secondary dentin).

Firstly, there is a zone of sclerosis walling off the lesion from the surrounding normal dentine. This zone of sclerosis is often referred to as the translucent zone, which is a defense reaction on the part of the pulp-dentinal unit. A further defense reaction can be seen some distance from the lesion. A region of reactionary, or reparative, dentin is laid down on the pulpal aspect of the lesion. Therefore the caries complication (pulpitis, apical periodontitis) developed considerably rarely. Acute and chronic caries course may change one another - under some conditions chronic caries course may changes rampant caries course. And, vice versa, at the improvement of the general organism status, character of nutrition acute caries may become chronic caries with slow course, or it may be arrested following several active phases. Such caries named arrested caries - caries stataria (Latin).

The more often such caries localized on occlusal surface which sustained attrition during mastication. When the general status of a patient's organism becomes considerably worse this development is so-called caries acutissima. This pathologic process is characterized by the very rapid course of caries process (during two-five weeks), which quickly developes the caries lesions. Such caries course accompanies numerous caries lesions especially in all teeth with one or two cavities in the tooth crown and this caries course is named caries florida. Sometimes caries begins to develop in a filled tooth, affecting hard tooth tissues around the filling or restorations. In these cases it is named caries recidiva s. secundaria.

Regardless of clinical course caries can affected single or numerous teeth. In the last case caries, as a rule, has the rampant course and named numerous (multiple) caries or systemic caries. In pedodontics distinguish compensative, sub compensative and decompensative caries form (after T.F. Vinogradova, 1978).

Hidden caries is a term used to describe lesions in dentin that are missed on a visual examination but which are large and demineralized enough to be detected radiographically. It should be noted that whether a lesion is actually hidden from vision depends on how carefully the area has been cleaned and dried and whether an appropriate clinical examination has been performed. In other words, to talk about hidden caries implies an insufficient clinical examination.

Caries process can affect different hard tooth tissues therefore in accordance to International classification of diseases there is also anatomic classification of caries. According to this classification distinguish enamel caries (caries enameli), dentin caries (caries dentini), cementum caries (caries cementi), arrested caries, odontoclasia, another caries, indefinite caries.

Caries destruction of hard tooth tissues in case of treatment absence may lead to complete destruction of enamel and dentin. In such cases the microorganisms and its toxins penetrate from a carious cavity in pulp and, even periodontal ligament, causing its inflammation development - pulpitis and apical periodontitis. These pathologic processes so named complications of caries. Depending on the degree of this penetration caries process without complications named caries simplex s. incom-plicata and with these complications - caries complicata (with pulpitis and apical periodontitis).

Classification of tooth preparations according to the anatomic areas involved as well as by the associated type of treatment was presented by G. V. Black and is designated as *Class I, Class II, Class III, Class IV, and Class V*. Since Black's original classification, an additional class has been added, *Class VI*. This classification has very practical value for operative treatment of caries by preparation and further filling (restoration) of carious cavities.

**Class I Restorations:** All pit-and-fissure restorations are Class I, and they are assigned to three groups, as follows: Restorations on Occlusal Surface of Premolars and Molars; Restorations on Occlusal Two Thirds of the Facial and Lingual Surfaces of Molars; Restorations on Lingual Surface of Maxillary Incisors.

**Class II Restorations:** Restorations on the proximal surfaces of posterior teeth are Class II: the proximo-occlusal (MO) conventional preparation, the distocclusal preparation (DO) and an MOD preparation has similar walls, line angles, and point angles.

**Class III Restorations:** Restorations on the proximal surfaces of anterior teeth that do not involve the incisal angle are Class III. Walls, line angles, and point angles of a representative conventional tooth preparation. Note that the faciolingual line angle at the incisal is termed the incisal line angle; likewise, the faciolingual incisal point angle is termed the axioincisal point angle.

**Class IV Restorations:** Restorations on the proximal surfaces of anterior teeth that do involve the incisal edge are Class IV.

Class V Restorations: Restorations on the gingival third of the facial or lingual surfaces of all teeth (except pit-and-fissure lesions) are Class V. For posterior teeth the incisal (i) becomes occlusal (o).

Class VI Restorations: Restorations on the incisal edge of anterior teeth or the occlusal cusp heights of posterior teeth are Class VI.

A general anatomical classification of caries penetration into dental tissues includes:

- (1) initial surface caries confined to the enamel,
- (2) penetration of enamel,
- (3) penetration of the dentinoenamel junction,
- (4) early penetration into dentin,
- (5) advanced penetration into the dentin,

(6) penetration to or into the pulp of the tooth. In addition to the above classification several other clinical patterns have been described which relate to the degree and rate of progression of caries. In a clinic topographical classification of caries depending on the depth of destruction of hard tooth tissues is most often used.

In 1948 I.G. Lukomskiy offered to distinguish two basic clinical features of caries - carious spot and carious cavity.

Depending on the depth of caries lesion of enamel and dentine the caries was divided on a superficial, middle and deep caries.

Depending on the caries course distinguish acute (rampant) and chronic caries. Therefore in classification distinguish incipient caries (carious spot), superficial caries, middle and deep caries; acute or chronic course.

**Incipient caries (caries incipiens):** The characteristic feature is development demineralization on the enamel surface. The early carious lesion on visible smooth surfaces of teeth is clinically manifested as a white, opaque region, which is best demonstrated when the area is air-dried. There is not caries cavity in enamel.

**Superficial caries (caries superficialis)** - there is carious defect in enamel; dentinoenamel junction is not destroyed by caries process.

**Middle caries (caries media)** - the caries cavity formed in the dentin: in a mantle dentin. This layer of dentin juxtaposed to the enamel and converted into the initial layer of dentin from the basement membrane.

**Deep caries (caries profunda)** - the caries cavity formed in the dentin: in a circum-pulpal dentin. This layer of dentin localized very close to pulp. The caries cavity may be divided from the pulp chamber only very thin partition or only the layer of secondary dentin.

## CLASSIFICATION OF CARIES

### I. Clinical

1. Incipient caries (acute, chronic).
2. Superficial caries (acute, chronic)
3. Middle caries (acute, chronic).

4. Deep caries (acute, chronic) or another variant:

1. Initial lesion
2. Extensive lesion
3. Moderate lesion
4. Severe lesion

II. Classification based on localization:

1. Occlusal (pit and fissure) caries.
2. Contact (interproximal) caries.
3. Root (cervical) caries.
4. Circular (caries anularis) caries.

III. Classification based on severity and rate of caries progression.

1. Rampant (acute) caries.
2. Chronic caries.
3. Caries acutissima.
4. Caries florida.
5. Recurrent (caries recidiva s. secundaria) caries.

IV. Classification based on number of lesion.

1. Single lesion.
2. Numerous lesions.

Anatomic classification (WHO).

1. Enamel caries.
2. Dentine caries.
3. Cementum caries.
4. Arrested caries.
5. Odontoclasia.
6. Another.
7. Indefinite.

VI. Classification based on the presence of complications.

1. Caries simple (uncomplicated).
2. Complicated caries.

VII. Classification based on severity

1. Very mild caries.
2. Mild caries.
3. Moderate caries.
4. Severe caries.
5. Very severe caries.

CLINICAL FEATURE OF CARIES.

**Incipient caries:** Patients complain at the presence of spots (white, chalky white, opaque or pigmented), rarely on feeling of insignificant sensitiveness, soreness of the mouth from different irritants mainly chemical (sour, sweet). The development of spots is linked with disorders of mineral composition of enamel, its dis-mineralization and demineralization. A process clinically begins from the loss the natural enamel translucency which is characteristic for intact enamel. The

limited enamel area becomes opaque, chalky white or brown colour. The last is caused by penetration of pigments (food, tobacco, pigmented microflora) in the demineralized (hypo mineralized) area of enamel during prolonged development of pathological process. At the acute (rampant) course on the limited areas of dental enamel appeared the opaque, deprived of natural transparency, chalky white colour spots. At the first time spots are small, but, gradually increased in sizes. Frequently it is located on occlusal surfaces in retentive points: pits and fissures of occlusal surfaces of teeth, cervical areas. In children it often localized on a vestibular surface and cervical areas. For the best revealing of caries spots it is recommended to remove from the spot surface debris and dry up the crown of the tooth: intact enamel saves their natural transparency and brilliance, while the surface of caries spot loses transparency and becomes opaque. During probing a roughness, insignificant pliability and sick-likeness of their surface, can be revealed.

*At the caries spots* located in fissures there can be difficulties at their diagnostics and differentiation with other pathological conditions, especially with children. It is linked with accumulation of food remnants in fissures, pigments which can change colour of surface fissures. In such cases it is hard visually to reveal a whitish or some pigmented caries spot in the enamel.

Using another diagnostic method to reveal the clinical caries signs at probing - softening, sensitiveness of surface of enamel. In children these signs may be very subjective, that is caused by insufficient mineralization of enamel in fissures. In such cases it is had to use the additional methods of caries investigation. To reveal caries it is possible to use, except for mechanical, (probing) and also other irritants (thermal, chemical). On the fissures surface placed cold (5—10° C) or hot (60-70° C) water or gutta-percha warmed-up to soft consistency. In intact enamel surface the heating of a fissure within the limits of 10-60° C does not cause a characteristic for a caries pain.

Chemical irritants can be used, such as organic solutions (lactic, apple) acids; and inorganic (hydrochloric, carbolic) acids; for solutions of sucrose, glucose, alcohol and ether. Intensity and frequency of feeling pain almost does not rely on the use of an irritant, but is dependent mainly on its concentration, age of patient (in elderly patients the reaction on the pain feeling low) and organism resistance.

The very effective diagnostic method of acute incipience caries is usage of the reactions with different dyes. They are based on properties of dye to penetrate into the demineralized enamel and, thus, dyeing a caries spot, while in an intact enamel it cannot penetrate. It is used a 2% water solution of methyl blue, a 0.1% water solution of methyl red, carmine, Congo red and others. A tooth is isolated from saliva by cotton rolls, dry out and on its surface with cotton pellet place a dye. In a few minutes the remnants of dye wash off by water and at presence of carious spot the surface of enamel gets the colour of dye (dark blue, rose and others). Another method is the use the solution of nitric acid silver, in a caries spot it is restored to metallic silver under influencing of present in her products

of protein disintegration. A spot here acquires the black colour. More rapid renewal of silver in this reaction can be attained by placed on the treated by nitric acid silver surface of enamel the repairer, for example a 4% solution of hydroquinone. In a carious spot the quantity of mineral components (apatites) of enamel diminishes because of processes of demineralization. It causes changes of conductivity of this hard tooth tissues, namely to its increase, because electric resistance of such area of enamel diminishes. The method of electro diagnostic of initial forms of caries was founded (Novik I. O., 1951; N.A. Kodola, 1956).

By the special device the conductivity is measured between the surfaces of affected by a pathological process (caries) or suspicious on its presence and intact enamel areas. A tooth is isolated, dry out, an active electrode is placed on the suspicious area of enamel surface and the passive is placed in the patient hand. If enamel surface is intact, the conductivity is practically equal to the zero because of large electric resistance of intact enamel. At caries presence the condostics arises Approximately on the same principle based the method of electro diagnostics of caries offered by V.K. Leontyev (1983).

Very useful method for diagnostic caries lesions is transillumination. It is possible to apply the method of luminescent diagnostics, which is based on the phenomenon of fluorescence of intact hard tooth tissues under action on them of ultraviolet rays. The special ultraviolet lamps are used for this purpose. In the black-out apartment the surface of tooth is lighted by a lamp in the distance by 20-30 sm. By fluorescence intact dental enamel shines light-green or bluish light, while areas affected by caries areas do not radiate light. The histological features at an initial caries are characterized development of different degree of enamel demineralization. At the enamel section the body of caries lesion has the triangle appearance with the basis turned of to enamel surface. At the study in the polarized light depending on the structure changes in the enamel lesion distinguish a few areas. The most demineralized is sub superficial lesion layer, which is covered by the mineralized superficial enamel layer. This interesting phenomenon is explained by the remineralization processes of carious lesion by the mineral components of saliva, if an oral fluid is unable to provide remineralization of the demineralized enamel area the rapid development of caries lesion occurs.

The surface texture of an incipient lesion is unaltered and is undetectable by tactile examination with an explorer. A more advanced lesion develops a rough surface that is softer than the unaffected, normal enamel. Softened chalky enamel that can be chipped away with an explorer is a sign of active caries. In the interior layers of white caries spot there are the changes both enamel rods surfaces and prisms themselves. In separate areas the crystals of apatites are destroyed, their orientation in rods changes, in formed micro spaces there are atypical crystals. Fragmentation of crystals, formation of homogeneous fine-grained substance and disappearances of visible border, between prisms is marked in future. Non-cavitated enamel lesions retain most of the original crystalline framework of the

enamel rods and the etched crystallites serve as nucleating agents for remineralization. Calcium and phosphate ions from saliva can then penetrate the enamel surface and precipitate on the highly reactive crystalline surfaces in the enamel lesion. Remineralized (arrested) lesions can be observed clinically as intact, but dis-colored, usually brown or black spots. Depending on the degree of the demineralization G. Gustafson (1975) distinguishes five zones. Most deeply in the enamel there is placed hyper mineralization zone with disappearance enamel structural components. In the second zone there is reduction of its hardness because of partial dissolution of enamel minerals, in the third - increase of mineralization. In a sub superficial fourth demineralization zone the minerals are almost fully washed. In a superficial fifth zone there can be complete disintegration, however it during long time remains enough mineralized and undamaged, even when caries spread on all thickness of enamel.

**At a polarization microscopy five zones (S.N. Onishenko, 1968; V.P. Zenovskiy, 1970) distinguish:**

- 1) superficial,
- 2) sub superficial,
- 3) central — body of caries lesion,
- 4) intermediate and
- 5) internal — translucent zone of enamel.

These zones are characterized by a different degree of transparency, therefore still named as superficial, dark (body of lesion) and semi-translucent zones (A. Darling, 1959)

**There were the four regularly observed zones in a sectioned incipient lesion:** (1) the translucent zone, (2) the dark zone, (3) the body of the lesion, and (4) the surface zone.

**Zone 1: Translucent Zone.** The deepest zone is the translucent zone and represents the advancing front of the enamel lesion. In this zone, the pores or voids form along the enamel prism (rod) boundaries, presumably because of the ease of hydrogen ion penetration during the carious process. The pore volume of the translucent zone of enamel caries is 1%, 10 times greater than normal enamel.

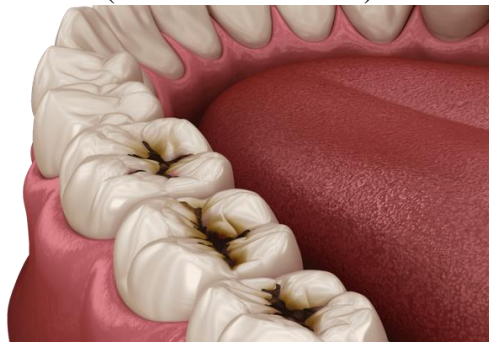
**Zone 2: Dark Zone.** The next deepest zone is known as the dark zone because it does not transmit polarized light. This light blockage is caused by the presence of many tiny pores too small to absorb quinoline. These smaller air- or vapor-filled pores make the region opaque. The total pore volume is 2% to 4%.

**Zone 3: Body of the Lesion.** The body of the lesion is the largest portion of the incipient lesion while in a demineralizing phase. It has the largest pore volume, varying from 5% at the periphery to 25% at the center. The Retzius striae are well marked in the body of the lesion, indicating preferential mineral dissolution along these areas of relatively higher porosity.

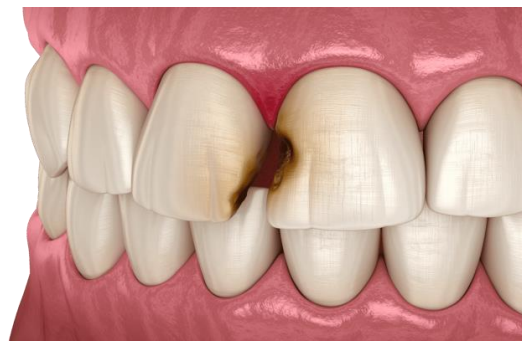**Zone 4: Surface Zone.** The surface zone is relatively unaffected by the caries attack. It has a lower pore volume than the body of the lesion (less than 5%) and a radiopacity comparable to unaffected adjacent enamel. The surface of

normal enamel is hyper mineralized by contact with saliva and has a greater concentration of fluoride ion than the immediately subjacent enamel. As the enamel lesion progresses, conical-shaped defects in the surface zone can be seen by SEM.

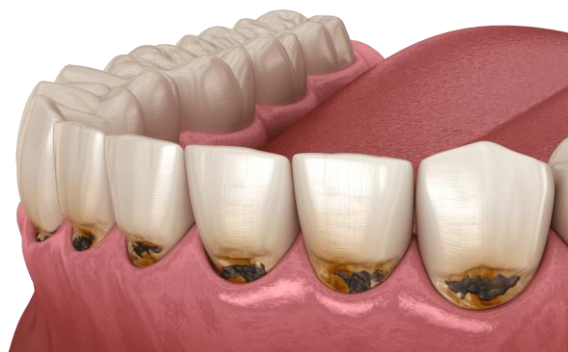Also was revealed, that in the caries enamel lesion (cariou spots) the volume of micro spaces is increased. If in an intact enamel they make approximately 0,2% from the general volume of this tissue, in a carious spot the volume of micro spaces increases to 0,8% in a superficial zone and till about 16% in sub superficial and central zones. There is decline of enamel hardness which is most distinct in the central area of carious lesion. Initial demineralization, namely the decline of calcium content in a superficial layer of white carious spot takes place on the so-called Retzius striae (con-centric lines).



*Occlusal caries*

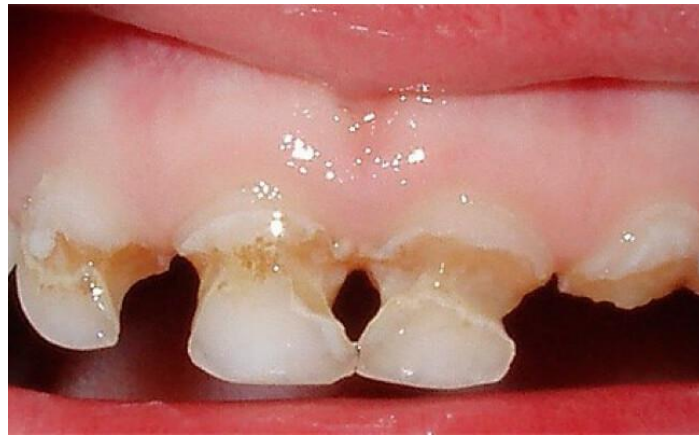

*Contact caries*

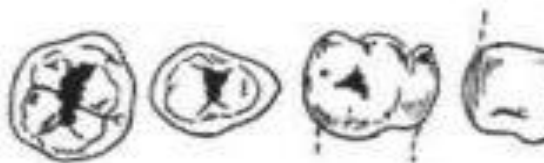



*Cervical caries*



Class I includes carious cavities located in natural fissures and pits on the occlusal (chewing), buccal and lingual (palatal) surfaces of molars and premolars and the lingual (palatal) surface of incisors;



Class II - carious cavities on the contact surfaces of molars and premolars;



Class III - located on the contact surfaces of incisors and

canines;



Class IV - carious cavities of class III with a violation of the integrity of the angle of the cutting edge;



Class V - located in the neck area of all tooth groups.

**IV. Control questions for class topic:**

1. What is the definition of the concept of "dental caries"?
2. What statistical indicators of tooth decay do you know?
3. What is the prevalence of caries and how is it determined?
4. What is caries intensity and how is it determined?
5. What is the clinical classification of caries?
6. Classification of caries by location?
7. Classification of caries by the course and intensity of the lesion?
8. Classification of caries anatomically and in the presence of complications?
9. Classification of tooth lesions by Black?
10. The concept of structural and functional resistance of hard tooth tissues.
11. How to determine the resistance of enamel?

**V. Control test tasks and/or case tasks:**

1. A complex formation, where the main role is played by uncalcified bacterial masses that are closely adjacent to the tooth surface, is:

- A. Tartar;
- B. Plaque;
- C. Mature dental plaque;
- D. Pelicle;
- E. Cuticle.

**The correct answer is: B.**

2. What did Black propose:

- A. Classification of carious cavities depending on their localisation on different surfaces of the crowns of teeth;
- B. Anatomical classification according to WHO;
- C. Use of the CPV + CP indices;
- D. Examination of salivary fluid;
- E. No correct answer.

**The correct answer is: A.**

3. How many classes belong to Black's classification:

- A. 3 classes;
- B. 4 classes;
- C. 5 classes
- D. 6 classes;
- E. more than 10 classes.

**The correct answer is: B.**

4. What is tooth decay?

**The correct answer is:** Caries dentis is a pathological process characterised by demineralisation and progressive destruction of the hard tissues of the tooth with the subsequent formation of a defect (cavity).

5. Anatomical classification of dental caries according to WHO?

**Correct answer:**

WHO anatomical classification:

1. Enamel caries.
  2. Dentin caries.
  3. Cement caries.
  4. Suspended caries.
  5. Odontoclasia.
  6. Other.
  7. Unspecified.
6. What is characteristic of chronic caries?

**The correct answer is:** The chronic course of caries is characterised by the slow development of tooth damage. The process usually lasts for years, and the subjective pain in this case is quite insignificant - under the influence of various stimuli, there is a slight pain. The areas of demineralisation of the hard tissues of the tooth are not as large as in the case of acute disease. If food pigments penetrate the demineralised enamel and dentin, they become dark brown or even black in colour. The overhanging edges of the enamel, which are characteristic of the acute course, break off in the case of a long-lasting carious cavity, and a rather wide entrance hole is formed. Softened and pigmented hard tooth tissues have a denser consistency than in patients with an acute course. Chronic caries is more common in practically healthy people with relatively minor metabolic, nutritional, and other disorders. Against the background of such a satisfactory general condition, multiple caries rarely develops, single carious lesions are more typical. The prolonged existence of a carious cavity causes the development of protective formations in the tooth pulp (e.g., secondary dentin), so complications in patients with chronic caries (pulpitis, periodontitis) develop much less frequently.

7. What is characteristic of an acute caries process?

**Correct answer:** The acute course is characterised by a fairly rapid (within a few weeks) development of demineralisation of the hard tissues of the teeth and the occurrence of a defect in the crown of the teeth. Demineralisation affects large areas of hard tissues - enamel and dentin. The affected enamel has a white, chalk-like colour, loses its characteristic shine and becomes dull. These areas of enamel are easily broken off when chewing solid food or when preparing a carious cavity with instruments (boron, excavator, etc.). The progression of the carious process leads to its spread in dentin, which has a lower degree of mineralisation than enamel. Therefore, the process of dentin destruction and the spread of the carious cavity in depth and breadth is much faster. As a result, the carious cavity acquires a fairly typical shape - it is large in size, with a narrow entrance opening and demineralised enamel edges hanging over the cavity. The dentin affected by the carious process is softened, it acquires a cartilaginous consistency (instead of hard), but its colour is practically unchanged (yellowish or yellow-brown). A fairly rapid (within a few months) progression of the acute course of the caries process leads to significant destruction of the hard tissues of the teeth and the spread of the process to the pulp or even the periodontium.

## LIST OF REFERENCES

**Main literature**

1. Stomatology: textbook: in 2 books. Book I / M.M. Rozhko, Z.B. Popovych, V.D. Kuroiedova et al.: edited by M.M. Rozhko. – Kyiv: AUS Medicine Publishing, 2020. – 792 p.: color edition.
2. Periodontal and Oral Mucosa Diseases: textbook. Vol. 2 / A.V. Borsenko, L.V. Lynovytska, O.F. Nesyn et al.; edited by A.V. Borysenko. - Kyiv: AUS Medicine Publishing, 2018. – 624 p.; color edition.
3. Stomatology: textbook: in 2 books. Book 2 / M.M. Rozhko, I.I. Kyrylenko, O. H. Denysenko et al.; edited by M. M. Rozhko. – Kyiv: AUS Medicine Publishing, 2018. – 960 p.; color edition.

**Additional literature**

1. Esthetic Dentistry: A Clinical Approach to Techniques and Materials 3rd Edition by Kenneth W. Aschheim. Publisher: Mosby; 3rd edition, 2014. – 600 p.
2. Esthetic and Restorative Dentistry: Material Selection and Technique 3rd Edition by Douglas A Terry, Willi Geller. Publisher: Quintessence Publishing Co Inc.; 3rd edition, 2017. – 776 p.
3. Dental Composite Materials for Direct Restorations Softcover reprint of the original 1st ed. by Vesna Miletic. Publisher: Springer; 1st edition, 2018. – 327 p.
4. Posterior Direct Restorations 1st Edition by Salvatore Scolavino, Gaetano Paolone. Publisher: Quintessence Pub Co; 1st edition, 2021. – 264 p.
5. Smile Design Integrating Esthetics and Function Essentials of Esthetic Dentistry Volume Two by Jonathan B. Levine. Elsevier Health Sciences, 2015. – 240 p.
6. Cohen's Pathways of the Pulp 12th Edition by Louis H. Berman, Kenneth M. Hargreaves. Publisher: Elsevier; 12th edition, 2020. –992 p.

## Lesson №2

### TOPIC: Modern ideas about the etiology and pathogenesis of caries.

**I. Topic relevance:** The dynamic process of demineralisation, which takes place numerous times during each day, is usually balanced by the properties of saliva (buffer capacity, levels of saliva secretion, inorganic substances, etc.), which results in remineralisation. When the balance is lost and pathological factors prevail, caries develops.

#### II. Study goal:

##### 2.1. Student has to know:

- Know the definition of dental caries;
- Know the etiology of caries;
- Know the pathogenesis of caries;
- Know what general cariesogenic factors are;
- Know the local cariesogenic factors;
- Know the properties and composition of oral fluid;
- Know how to perform a TER test.

##### 2.2 Be able to:

- Be able to determine the etiology of caries;
- Be able to determine the cause of caries;
- Be able to differentiate the causes of caries.

#### III. Content of the topic

When the three essential parameters for dental caries - cariogenic organisms, susceptible teeth and a suitable local substrate — exist in an individual for a considerable time, then dental caries may develop.

Caries causes damage by demineralization and dissolution of tooth structure, resulting from (1) a highly localized drop in the pH at the plaque-tooth interface and (2) tooth demineralization. The local pH drop occurs as the result of plaque metabolism, but only plaque communities with high concentrations of MS and lactobacilli can produce a sufficiently low pH to cause demineralization of teeth.

A single exposure of sucrose solution to a cariogenic plaque results in rapid metabolism of the nutrients to organic acids. The organic acids (primarily lactic acid) dissociate to lower the local pH. Single events of lowered pH are not sufficient to produce significant changes in the mineral content of the surfaces of the teeth. However, many episodes of long-duration demineralization (lowered pH), occurring over long periods of time, will produce the characteristic lesions of caries. Frequent sucrose exposure is the single most important factor in

maintaining a pH depression at the tooth surface, often resulting in demineralization.

The output (production) of acid from caries-active plaques is twice that of caries-inactive plaques per milligram wet weight of plaque. The production of acid from a caries-active plaque can overcome the buffering capacity of salivary bicarbonate available at the tooth-plaque interface, causing the local pH to fall. Once the pH falls below 5.5, tooth mineral is dissolved. At lower pH values, such as 3.0 or 4.0, the surface of enamel is etched and roughened. At a pH of 5.0, the surface remains intact while the subsurface mineral is lost.

Cavitation of the surface occurs when the subsurface demineralization is so extensive that the tooth structure surface collapses. Cavitation of enamel is not reversible and is usually associated with the acceleration in the process of carious destruction of the tooth. It occurs when a series of demineralization (pH drop) and remineralization (salivary ions) episodes are dominated by the demineralization process.

**There are three distinctly different clinical sites for caries initiation:**

- (1) the recesses of developmental pits and fissures of enamel, which is the most susceptible site;
- (2) smooth enamel surfaces that shelter plaque;
- (3) the root surface.

#### **IV. Control questions for the class topic:**

1. What is tooth decay?
2. The etiology of caries.
3. Pathogenesis of caries.
4. What cariesogenic factors of general nature do you know?
5. What cariesogenic factors of local nature do you know?
6. What nutrition affects the occurrence of caries in patients?
7. How do past and concomitant diseases affect the development of caries?
8. What role do dental plaque play in the development of caries?
9. What are the consequences of food debris accumulating on the surface of the teeth and in the interdental spaces?

#### **V. Control test tasks and/or case tasks:**

1. General cariesogenic factors include:
  - A. Malnutrition;
  - B. Drinking water;
  - C. Mature dental plaque;
  - D. Tartar;
  - E. An unfavourable genetic code.

**The correct answer is: A, B.**

2. Local cariesogenic factors include:
  - A. Dental plaque;
  - B. Malnutrition;
  - C. Drinking water;

- D. Microphyllora;
- E. No correct answer.

**The correct answer is: A, D.**

3. Etiology is:

- A. Mechanisms of the occurrence and development of the disease and its individual manifestations at different levels of the body - from molecular disorders to changes in organs and systems;
- B. A theoretical branch of medicine that studies the causes of diseases;
- C. A set of measures and studies aimed at establishing a diagnosis, i.e. the exact cause of the disease;
- D. A method that allows you to exclude possible diseases in a patient that do not fit any factors and symptoms, and to establish the only correct diagnosis.
- E. All answers are correct

**The correct answer is: B.**

4. Pathogenesis is:

- A. Mechanisms of the occurrence and development of the disease and its individual manifestations at different levels of the body - from molecular disorders to changes in organs and systems;
- B. A theoretical branch of medicine that studies the causes of diseases;
- C. A set of measures and studies aimed at establishing a diagnosis, i.e. the exact cause of the disease;
- D. A method that allows you to exclude possible diseases in a patient that do not fit any factors and symptoms, and to establish the only correct diagnosis.
- E. All answers are correct

**The correct answer is: A.**

5. How does ionising radiation affect dental health?

**Correct answer:** Of the adverse extreme effects on the human body, ionising radiation has the most damaging effect on teeth. It disrupts the functioning of the salivary glands in the mouth, resulting in a decrease in saliva production and a soft and sticky white coating on the teeth. Over time, these areas form foci of demineralisation and necrosis of the hard tooth tissues. A direct damaging effect of ionising radiation on hard tooth tissues was also found. In the future, the pathological process progresses rapidly along the surface of the tooth crown and into the enamel and dentin.

6. Under what circumstances does enamel dissolution occur?

**Correct answer:** Enamel dissolution begins when the pH drops to 5.5, so this pH value is considered critical.

7. How does the consumption of carbohydrates affect the development of caries?

**Correct answer:** It has been proven that the consumption of carbohydrates with food causes hyperglycaemia, hyposalivation, increased salivary oxygen uptake and salivary P/Ca ratio. The specific effect of carbohydrates is that they significantly activate glycolysis. This stimulates the acidogenic activity of oral microorganisms ("metabolic explosion"), resulting in a 4 to 5-fold increase in the

amount of organic acids in saliva compared to the normal level. These changes significantly increase the susceptibility to caries, which is often multiple with an active acute course.

8. What happens to food debris that accumulates on the teeth and in the interdental spaces?

**Correct answer:** If they are retained and accumulate in the retention areas, they represent a nutrient medium and material from which microorganisms can form acids. The most important in this case are easily digestible carbohydrates, especially sucrose and glucose. Carbonaceous food residues are very easily transformed not only into acids, but also into dextrans and levans, which play a significant role in the formation of plaque and its attachment to the tooth surface. A rather significant thickness of food residues also prevents the penetration of components of the saliva buffer system through them, which further creates conditions for the accumulation of acids under them.



### Lesson №3

**TOPIC: Acute and chronic caries in the spot stage**  
**Pathomorphology, clinic, diagnosis, differential diagnosis, treatment methods.**

**I. Topic relevance:** Dental caries is the most common disease among the population of all age groups. Complications caused by caries lead to a significant impairment of chewing efficiency, which is subsequently manifested by various pathologies of the gastrointestinal tract and disruption of many types of metabolism. Cosmetic defects in carious lesions often cause a lot of moral suffering and psycho-emotional trauma to patients. It is logical that future dentists need to know the clinical manifestations of caries at its various stages for successful diagnosis, effective treatment and reliable prevention of the most common dental disease.

#### **II. Study goal:**

##### **2.1. Student has to know:**

- Know the definition of dental caries;
- Know the course of acute form of initial caries;
- Know the course of chronic form of initial caries;
- Know the pathomorphology of caries in the spot stage;
- Know the clinic of initial caries in a patient;
- Know how to diagnose caries in the spot stage;
- Know the methods of treatment of initial caries.

##### **2.2 Be able to:**

- Be able to determine the course of caries in the spot stage;
- Be able to diagnose acute initial caries;
- Be able to diagnose chronic caries in the spot stage;
- Be able to carry out differential diagnosis of acute initial caries
- Be able to carry out differential diagnosis of chronic primary caries;
- To be able to treat tooth caries in the spot stage.

#### **III. Content of the topic**

Actually the formation of *brown pigment in a spot* is connected with the accumulation in spot of amino acid such as tyrosine with further its transformation into pigment melanin. Under a white caries spot does not still revealed changes of dentinoenamel junction, under pigmented spots such changes is revealed. The reactive changes were revealed in dentin: the narrowing of dentinal tubules, appearances of layer of translucent (sclerotic) dentin; the odontoblasts changing in the pulp areas according to the caries lesion. Electron microscopic studies of den-tine with an incipient caries allowed to revealed two

phases of pathological process development in spot. At the first phase there are the rough changes of odontoblastic processes, destruction of collagen fibres of dentine matrix.

Disorganization of odontoblasts layer, pathological changes of nervous fibres and vessels were revealed in pulp. At the second phase, on a background of further progress of these changes, the destroying of form and dimension of dentin apatites crystals developed, in its tubules begins the deposition of mineral salts. Superficial caries: In some period of time in the center of caries spot the superficial layer of enamel loses the integrity and in enamel defect appears.

The first sign of a caries lesion on enamel that can be detected with the naked eye is often called a white-spot lesion. This appearance has also been described as an early, initial or incipient lesion. These terms are meant to say something about the stage of lesion development. However, a white-spot lesion may have been present for many years in an arrested state and to describe such a lesion as early would be inaccurate.

A dictionary definition of incipient is «beginning; nascent stage», in other words, an initial lesion appears as a white, opaque change (a white spot), but any white-spot lesion is not incipient. The terms remineralized or chronic lesions are sometimes used to signify arrested lesions, but the term remineralization should be used with caution. The distinction between active and arrested lesions may not be totally straightforward. Thus, there will be a continuum of transient changes from active to arrested, and vice versa. A lesion (or part of a lesion) may be rapidly progressing, slowly progressing or not progressing at all. This will depend entirely on the ecological balance in the biofilm covering the site and the environmental challenge.

**Incipient caries:** Patients complain at the presence of spots (white, chalky white, opaque or pigmented), rarely on feeling of insignificant sensitiveness, soreness of the mouth from different irritants mainly chemical (sour, sweet). The development of spots is linked with disorders of mineral composition of enamel, its dis-mineralization and demineralization.

A process clinically begins from the loss the natural enamel translucency which is characteristic for intact enamel. The limited enamel area becomes opaque, chalky white or brown colour. The last is caused by penetration of pigments (food, tobacco, pigmented microflora) in the demineralized (hypo mineralized) area of enamel during prolonged development of pathological process.

*At the acute (rampant) course* on the limited areas of dental enamel appeared the opaque, deprived of natural transparency, chalky white colour spots. At the first time spots are small, but, gradually increased in sizes. Frequently it is located on occlusal surfaces in retentive points: pits and fissures of occlusal surfaces of teeth, cervical areas. In children it often localized on a vestibular surface and cervical areas. For the best revealing of caries spots it is recommended to remove from the spot surface debris and dry up the crown of the

tooth: intact enamel saves their natural transparency and brilliance, while the surface of caries spot loses transparency and becomes opaque. During probing a roughness, insignificant pliability and sick-likeness of their surface, can be revealed.

**Incipient caries (caries incipiens):** The characteristic feature is development demineralization on the enamel surface. The early carious lesion on visible smooth surfaces of teeth is clinically manifested as a white, opaque region, which is best demonstrated when the area is air-dried. There is not caries cavity in enamel.

The surface texture of an incipient lesion is unaltered and is undetectable by tactile examination with an explorer. A more advanced lesion develops a rough surface that is softer than the unaffected, normal enamel. Softened chalky enamel that can be chipped away with an explorer is a sign of active caries. In the interior layers of white caries spot there are the changes both enamel rods surfaces and prisms themselves. In separate areas the crystals of apatites are destroyed, their orientation in rods changes, in formed micro spaces there are atypical crystals. Fragmentation of crystals, formation of homogeneous fine-grained substance and disappearances of visible border, between prisms is marked in future. Non-cavitated enamel lesions retain most of the original crystalline framework of the enamel rods and the etched crystallites serve as nucleating agents for remineralization. Calcium and phosphate ions from saliva can then penetrate the enamel surface and precipitate on the highly reactive crystalline surfaces in the enamel lesion.

In case of incipient caries it is possible to speak about demineralization affected hard tooth tissues. A white carious spot can fully disappear.

### **BACKGROUNDS OF REMINERALIZATION THERAPY**

1. Ability of restoration the level of hard tooth tissues mineralization during incip- ience caries.

2. Phenomenon of enamel permeability for mineral matters.

3. Dynamic balance processes of demineralization and remineralization in enamel.

4. Ability of fluoride for restoration enamel mineral structure.

5. Phenomenon of «enamel maturation» in children. in favour to primary atraumatic restorative treatment or minimal invasive treatment with the subsequent control of surfaces affected by caries. Neither of the varieties of restoration treatment of dental caries may be fully «curing».

Destroyed by a caries hard tooth tissues (and adjoining areas of healthy enamel) are not substituted for by formed again enamel and dentin. Besides, there is no existing restorative material capable during all life to protect hard tooth tissues from further destructive caries processes.

Tooth restoration is only symptomatic treatment which does not eliminate the etiologic factors of dental caries. Therefore the prevention of development caries lesions (prophylactic measures) is the basic principle of caries treatment, rather than the necessary medical treatment (remineralization therapy) and, in the

last turn, as the forced measure of restoration the caries cavity with restorative materials, conducted along with the measures of the second caries prophylaxis.

**Thus, now there are two main methods of local caries treatment:**

1) caries treatment without preparation and restoration - remineralization therapy,

2) operative caries treatment by the operative preparation of demineralized hard tooth tissues with the subsequent restoration of carious cavity. The choice of treatment method depends of the stage of caries development, activity of caries (rampant or chronic), localization of carious cavity, age and general condition of patient. Preventive treatment methods are designed to limit tooth demineralization caused by cariogenic bacteria, thereby preventing cavitated lesions.

**They include:**

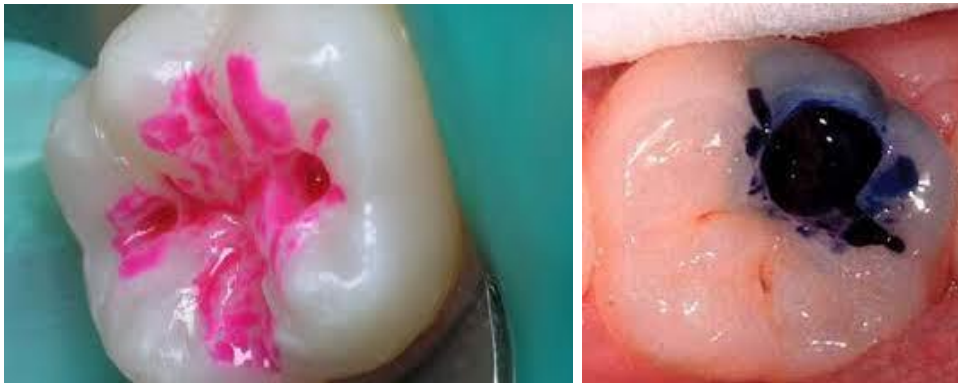(1) limiting pathogen growth and metabolism,

(2) increasing the resistance of the tooth surface to demineralization.

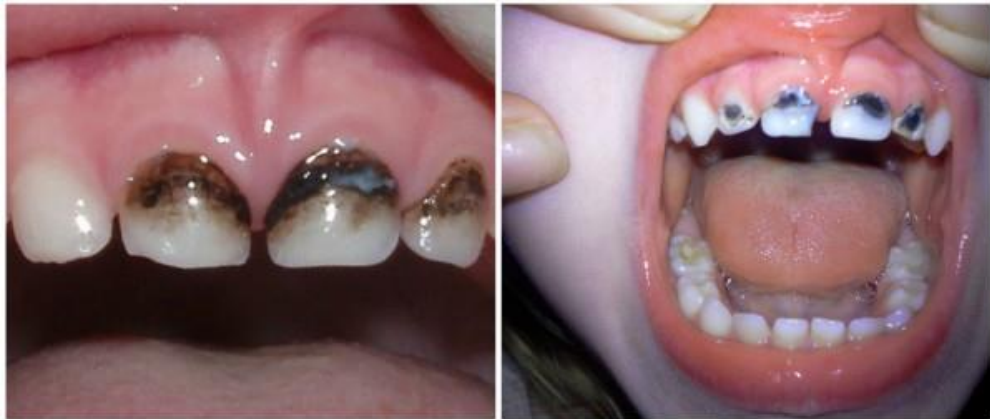Disease caries control concerns influencing biofilm formation and growth, or modifying the dissolution kinetics of the apatites, or both.

The following may have a role to play:

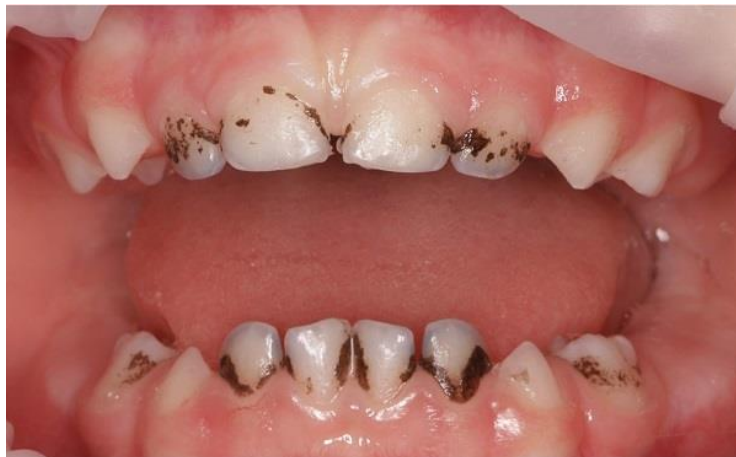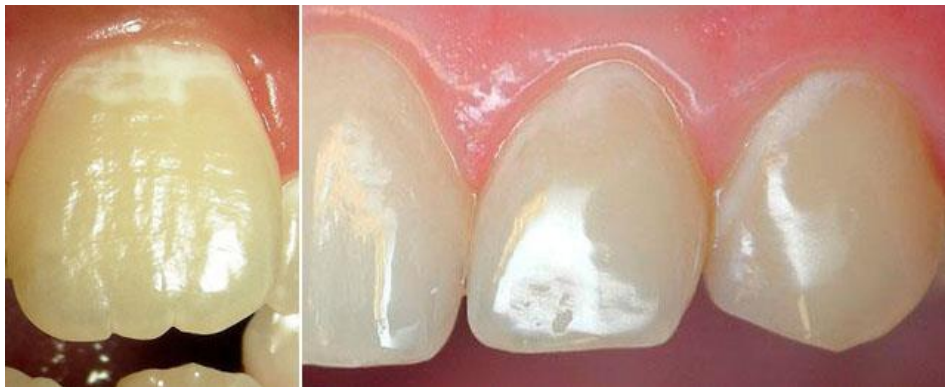- mechanical/chemical removal of plaque (oral hygiene)
- chemical (antimicrobial) modification of plaque
- use of fluorides
- dietary composition
- salivary composition and stimulation.



If there is a carious spot, it is the colour of the dye (blue, pink, etc.). Another method has been proposed: instead of dyes, a silver nitrate solution is used, which is reduced to metallic silver in the carious spot under the influence of protein breakdown products present in it.



In this case, the stain becomes black. A faster recovery of silver in this reaction can be achieved by applying a 4% hydroquinone solution to the silver nitrate-treated enamel surface.



*Pristley's plaque*

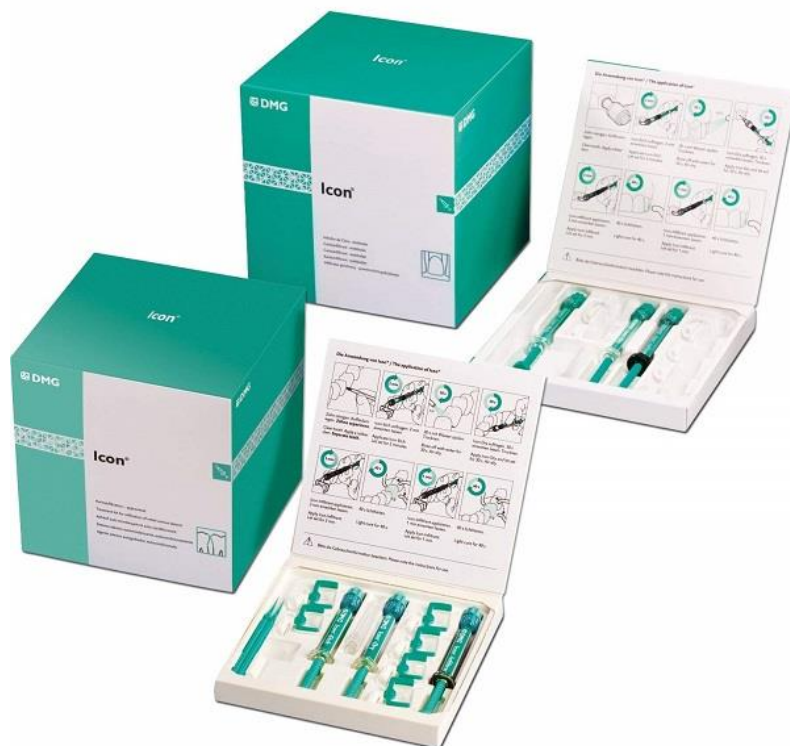### **Treatment of caries with the Icon system**

Icon caries treatment is a non-invasive technique that allows to cure early caries and preserve tooth tissue without treating it with a dental drill.

The system is a set of special gels and a liquid polymeric substance. This German innovation, which allows treating caries without a drill, quickly became

popular and in demand. The use of Icon in paediatric dentistry can be compared to a real magic wand, which makes caries disappear without pain and tears.

The useful elements of the product literally saturate and fill the tooth tissues, preventing the carious process from developing.



#### **IV. Control questions for the class topic:**

1. What is tooth decay?
2. Etiology of initial caries.
3. Pathogenesis of initial caries.
4. What is the course and clinic of acute initial caries?
5. What is the course and clinic of chronic primary caries?
6. What is the diagnosis of caries in the spot stage?
7. What diseases do we carry out differential diagnosis with?
8. What are the methods of treatment of initial caries?

#### **V. Control test tasks and/or case tasks:**

1. Patients complain of initial caries of:
  - A. Pain while eating;
  - B. Night pain;
  - C. A cosmetic defect;
  - D. Reaction of the tooth to sweets;
  - E. Pain radiating to the temple.

**The correct answer is: B.**

2. Differential diagnosis of caries in the spot stage is carried out with:
  - A. Hypoplasia;

- B. Pulpitis;
- C. Medium caries;
- D. Deep caries;
- E. Periodontitis.

**The correct answer is: A.**

3. Differential diagnosis is carried out with the help of:

- A. Anaesthesia test;
- B. Caries markers;
- C. Test for preparation
- D. X-ray diagnostics
- E. EOD

**The correct answer is: B.**

4. Pathogenesis is:

- A. Mechanisms of the occurrence and development of the disease and its individual manifestations at different levels of the body - from molecular disorders to changes in organs and systems;
- B. A theoretical branch of medicine that studies the causes of diseases;
- C. A set of measures and studies aimed at establishing a diagnosis, i.e. the exact cause of the disease;
- D. A method that allows you to exclude possible diseases in a patient that do not fit any factors and symptoms, and to establish the only correct diagnosis.
- E. All answers are correct

**The correct answer is: A.**

5. What is remineralising therapy and at what stages is it used?

The correct answer is: Remineralising therapy is a direction in dentistry that helps to preserve the integrity of enamel and prevent caries. The procedure is performed with the use of a wide range of drugs containing minerals that restore the natural hardness of tooth enamel. The process is painless and does not cause discomfort. It is indicated for patients with a tendency to caries in the absence of contraindications. The procedure can be performed both for preventive and therapeutic purposes.

6. What is the differential diagnosis of caries at the stage of a spot with fluorosis?

**Correct answer:** It is most often carried out with the erosive form of fluorosis - wider and deeper defects, or erosions, are formed in the chalky enamel. When the enamel loses its lustre and becomes dull, it may have small, rounded defects - a chalky-mottled form of fluorosis. Patients with this form of fluorosis often have teeth of different groups. Sometimes the entire surface of the enamel is depigmented and has a chalky tint, but unlike demineralised enamel in caries, it retains its lustre. Against this background, there are often separate areas of light brown or dark brown pigmentation.

7. What is the differential diagnosis of initial caries with hypoplasia?

**Correct answer:** An essential differential feature is the localisation of the lesions. In patients with hypoplasia, the spots are most often located on the

convex vestibular surface of the anterior teeth and the tubercles of molars and premolars. Caries, on the contrary, is very rarely localised on convex, smooth surfaces of the teeth, more often on contact surfaces, pits and fissures of molars. Stains in the presence of hypoplasia have a pronounced symmetry - they are located on the same surfaces of the teeth on the right and left, even their shape and colour can be very similar. Caries is also characterised by symmetrical lesions, but the spots may not appear simultaneously (i.e., they may appear on one half of the jaw much earlier), the shape and colour of the carious lesion may differ.

8. How does the Icon system treat caries?

**Correct answer:** Firstly, the preparation of the working surface of the tooth - isolation of the tooth with a latex handkerchief (cofferdam), cleaning of the surface;

The next step is to etch the affected surface with a special gel so that the active substance penetrates into the pores of the tooth as much as possible. The etching is washed off and the tooth is thoroughly dried; Next, a gel infiltrate is applied to the surface, which performs the main job - it fills all branches, pores and small cavities, blocking the further pathological process; The final stage is the fixation of the material with a polymerisation lamp. Depending on the degree of tooth damage, stages 3 and 4 are repeated.



## Lesson №4

### **TOPIC: Acute and chronic superficial caries: pathomorphology, clinic, diagnosis, differential diagnosis, treatment.**

**I. Topic relevance:** All experts say that the main reason for this undesirable consequence is insufficient compliance with the well-known rules of oral hygiene. The accumulation of food debris in the mouth creates ideal conditions for the growth of carcinogenic bacteria, which is the main cause of surface caries.

#### **II. Study goal:**

##### **2.1. Student has to know:**

- Know the definition of dental caries;
- Know the etiology of superficial caries;
- Know the pathogenesis of superficial caries;
- Know the clinic of superficial caries;
- Know the diagnosis and differential diagnosis of superficial caries;
- Know the methods of treatment of superficial caries.

##### **2.2 Be able to:**

- Be able to determine the etiology of superficial caries;
- Be able to determine the cause of superficial caries;
- Be able to determine the course of caries;
- Be able to differentiate superficial caries from other dental diseases;
- Be able to diagnose superficial caries;
- Be able to choose the right treatment for superficial caries.

#### **III. Content of the topic**

**Superficial caries (caries superficialis)** - there is carious defect in enamel; dentin-enamel junction is not destroyed by caries process.

Superficial caries: In some period of time in the center of caries spot the superficial layer of enamel loses the integrity and in enamel defect appears. In an acute superficial caries the patients complains of insignificant pain, more frequent on feeling of soreness of the mouth and affected tooth, which caused by chemical irritants and quickly disappeared after stopping of irritant action. Sometimes there can be short-term pain from thermal and mechanical irritants, more frequent in a place of caries lesion. At the examination of tooth in the area of chalky white colour spot revealed of defeat of a shallow enamel defect (cavity) is determined, placed within the enamel borders. The enamel wall of lesion is softened, yellow-grey colour by and some sensible at probing. Sometimes may be only rough surface, but after removing softened enamel surface the lesion (cavity) was found.

A *chronic superficial caries* has course mainly without the pain feeling. Rarely may be insignificant pains from chemical irritants which at once disappeared after their removal. On the surface of enamel revealed small enamel lesion (cavi-ty), with enough dense yellow-brown or brown colour enamel walls. A cavity has wide, exposed, without overhanging margins entrance opening. Probing of carious defect is practically painless. When superficial caries located in fissures the margins of lesions remained undamaged.

Superficial caries is diagnosed on such basis:

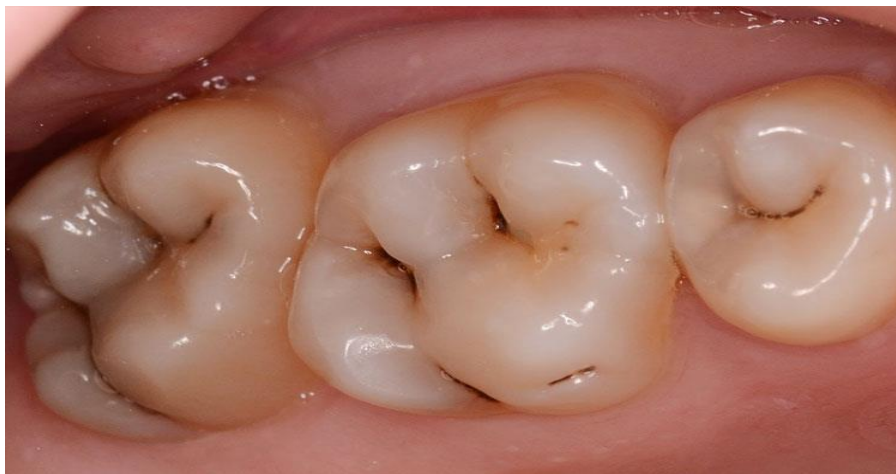a) patient complaints of short-term pain feeling mainly from chemical irritants; pain disappeared after stopping of irritant action;

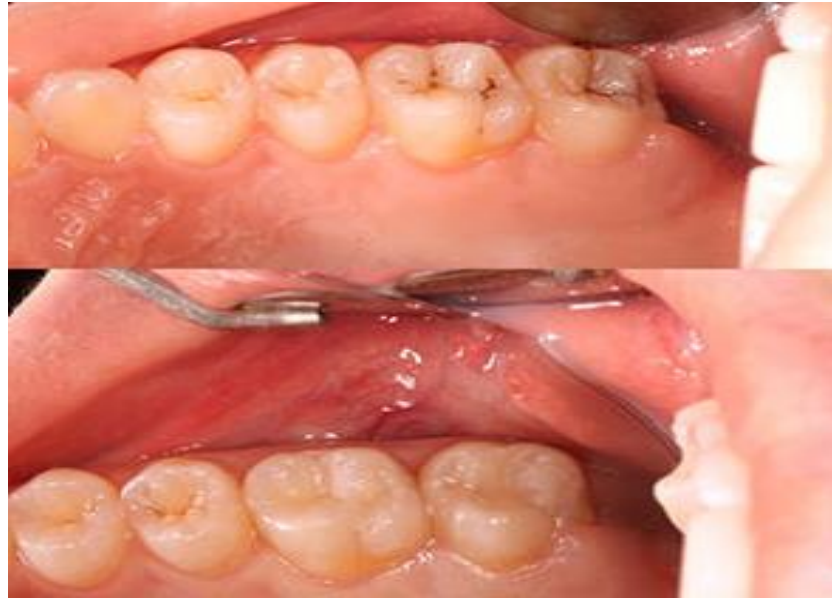b) revealing of shallow carious cavity, located within the limits of enamel, or of fissures pigmentation on occlusal surface, in which by probing the softened demineralized enamel is revealed:

c) painful preparation of hard tooth tissues especially at the dentinoenamel junction.

**Histopathology:** The main features consist of complete destruction of all enamel rods (prisms) in the body of lesion. Around it there is disintegration peripheral areas of enamel prisms, increase of inter-prism distances with the further involving in the pathological process of dentinoenamel junction. Thus in enamel formed a different sizes cone-shaped lesion. The apex of lesion reaches a dentine in which also the process of demineralization and initial destruction begins.

All these changes are more expressed at the acute caries course and less at chronic, in the last case the widening inter-prism distances contain the large amount of pigments (mainly brown). In the areas of dentine, which located closer to the caries enamel lesion the characteristic changes are also revealed. Directly near dentinoenamel junction dentinal tubules are widening and filled microorganisms. In deeper dentin layers the tubules are narrowed, sclerotic; the dentin matrix hyper mineralized forming zone translucent or sclerotic dentin. In pulp according to localization of caries cavity odontoblasts are deformed, reduction in quantity, the subodontoblastic plexus capillaries are widening.





**IV. Control questions for the class topic:**

1. Determine the etiology of superficial caries?
2. Determine the cause of superficial caries?
3. Determine the course of caries?
4. Differential diagnosis of superficial caries with other dental diseases.
5. Diagnosis of superficial caries.
6. How to properly treat superficial caries?

**V. Control test tasks and/or case tasks:**

1. Patients with superficial caries complain of:
  - A. Pain while eating;
  - B. Night pain;
  - C. Pain when biting down;
  - D. Reaction of the tooth to sweets;
  - E. Pain radiating to the temple.

**The correct answer is: D.**

2. Differential diagnosis of initial caries is carried out with:
  - A. Hypoplasia;
  - B. Fluorosis;
  - C. Medium caries;
  - D. Wedge-shaped defect;
  - E. All answers are correct.

**The correct answer is: E.**

3. Differential diagnosis is carried out with the help of:
  - A. Anaesthesia test;
  - B. Caries markers;
  - C. Test for preparation

D. X-ray diagnostics

E. EOD

**The correct answer is: B, D.**

4. When a carious cavity is located on the vestibular surface of the anterior teeth and premolars, it is filled with: composites, compomers, glass ionomer, silicate cements;

A. Composites;

B. Composites;

C. Glass ionomer cements;

D. Silicate cements;

E. All answers are correct

**The correct answer is: D.**

5. What is the differential diagnosis of superficial caries with hypoplasia?

**The correct answer is:** Superficial caries can resemble hypoplasia with the presence of erosions, pits and furrows on the enamel surface. Most of the features that distinguish them are similar to the differential differences of primary caries: characteristic location, time of onset (before or after eruption), dynamics of defects, simultaneous damage to different groups of teeth. In addition, hypoplasia is characterised by a peculiar transverse-linear arrangement of pits and furrows on the crowns of teeth. The surface of hypoplasia defects is dense, shiny, painless during probing, softening of hard tissues and overhanging enamel edges are absent. When applying a dye (methylene blue, for example), demineralised carious hard tissues of the teeth are stained; on the contrary, the dye does not penetrate into hypoplasia defects.

6. What is the differential diagnosis of superficial caries with fluorosis?

**Correct answer:** Most often it is carried out with the erosive form of fluorosis - wider and deeper defects - erosions - are formed in the chalk-like enamel. When the enamel loses its lustre and becomes dull, it may have small, rounded defects - a chalky-mottled form of fluorosis. Patients with this form of fluorosis often have teeth of different groups. Sometimes the entire surface of the enamel is depigmented and has a chalky tint, but unlike demineralised enamel in caries, it retains its lustre. Against this background, there are often separate areas of light brown or dark brown pigmentation.

7. What is the differential diagnosis of superficial caries with medium caries?

**Correct answer:** Superficial caries differs from medium caries primarily in subjective sensations: medium caries is practically not characterised by painful sensations from chemical irritants. A cavity in superficial caries is localised only within the enamel, while in medium caries it is also located in the dentin cape layer. In superficial caries, even in the case of acute caries, there are no pronounced overhanging edges of the enamel, while in acute medium caries they are almost always present.

8. What recommendations does the doctor give to the patient after treatment of superficial caries?

**Correct answer:** First, recommendations on rational oral hygiene and toothbrushing techniques; then on the prescription of individual hygiene products (medium-hard toothbrushes, flosses) and the prescription of therapeutic and prophylactic pastes containing fluorides, calcium salts and mineral salts.

#### LIST OF REFERENCES

##### **Main literature**

1. Stomatology: textbook: in 2 books. Book I / M.M. Rozhko, Z.B. Popovych, V.D. Kuroiedova et al.: edited by M.M. Rozhko. – Kyiv: AUS Medicine Publishing, 2020. – 792 p.: color edition.
2. Periodontal and Oral Mucosa Diseases: textbook. Vol. 2 / A.V. Borsenko, L.V. Lynovytska, O.F. Nesyn et al.; edited by A.V. Borysenko. - Kyiv: AUS Medicine Publishing, 2018. – 624 p.; color edition.
3. Stomatology: textbook: in 2 books. Book 2 / M.M. Rozhko, I.I. Kyrylenko, O. H. Denysenko et al.; edited by M. M. Rozhko. – Kyiv: AUS Medicine Publishing, 2018. – 960 p.; color edition.

##### **Additional literature**

1. Esthetic Dentistry: A Clinical Approach to Techniques and Materials 3rd Edition by Kenneth W. Aschheim. Publisher: Mosby; 3rd edition, 2014. – 600 p.
2. Esthetic and Restorative Dentistry: Material Selection and Technique 3rd Edition by Douglas A Terry, Willi Geller. Publisher: Quintessence Publishing Co Inc.; 3rd edition, 2017. – 776 p.
3. Dental Composite Materials for Direct Restorations Softcover reprint of the original 1st ed. by Vesna Miletic. Publisher: Springer; 1st edition, 2018. – 327 p.
4. Posterior Direct Restorations 1st Edition by Salvatore Scolavino, Gaetano Paolone. Publisher: Quintessence Pub Co; 1st edition, 2021. – 264 p.
5. Smile Design Integrating Esthetics and Function Essentials of Esthetic Dentistry Volume Two by Jonathan B. Levine. Elsevier Health Sciences, 2015. – 240 p.
6. Cohen's Pathways of the Pulp 12th Edition by Louis H. Berman, Kenneth M. Hargreaves. Publisher: Elsevier; 12th edition, 2020. –992 p.

## Lesson №5

### **TOPIC: Acute and chronic medium caries: pathomorphology, clinic, diagnosis, differential diagnosis, treatment.**

**I. Topic relevance:** Dental caries is the most common disease among the population of all age groups. Complications caused by caries lead to a significant impairment of chewing efficiency, which is subsequently manifested by various pathologies of the gastrointestinal tract and disruption of many types of metabolism. Cosmetic defects in carious lesions often cause a lot of moral suffering and psycho-emotional trauma to patients. It is logical that future dentists need to know the manifestations of caries at its various stages for successful diagnosis, effective treatment and reliable prevention of the most common dental disease.

### **II. Study goal:**

#### ***2.1. Student has to know:***

- Know the definition of dental caries;
- Know the etiology of medium caries;
- Know the pathomorphology of medium caries;
- To know the patient's complaints with medium caries;
- Know the diagnosis and differential diagnosis of medium caries;
- Know the methods of treatment of medium caries.

#### ***2.2 Be able to:***

- Be able to determine the etiology of medium caries;
- Be able to determine the course of medium caries;
- Be able to differentiate medium caries from other dental diseases;
- Be able to diagnose medium caries;
- Be able to choose the right treatment for medium caries.

### **III. Content of the topic**

**Middle caries (caries media):** After destruction by the pathological process of dentinoenamel junction caries begins quickly to spread in a dentine. As a middle caries (caries media) mean such pathological condition, when a caries cavity located in mantle dentin. The patient with acute middle caries often complains of feeling pain. More frequent the pain has weak intensity and appeared only at action of irritants: chemical, thermal, mechanical. On the tooth surface there is a chalky white colours caries spot with the enamel defect in a center. Examination of the cavity is difficult because of narrow entrance opening. A cavity usually has a depth 1.5-2 mm, is filled by food residue and softened dentin.

Complete examination of carious cavity is possible only after removing by the instruments (burs, excavators) of overhanging chalky white colour enamel margins. Cavity is most wide near dentinoenamel junction and gradually narrows towards pulp. The softened dentine which covers a cavity, has grey-white or yellow colour, rarely is it pigmented.

The degree of dentine softening depend of activity of caries process: at acute (rampant) caries the hard tooth tissues are most softened like a cartilage, at chronic course it may be harder and pig-mented. Probing of carious cavity is practically painless except dentinoenamel junction. A chronic middle caries has practically little clinical symptoms. In some case may be weak pain which appeared because of action of chemical, rarely thermal and mechanical irritants and is at once stopped after their removal. At the examining a caries cavity with the enough wide entrance opening is revealed, it located in mantle dentin, depth of cavity is 1.5-2 mm depending on the surface of tooth. The caries cavity is covered with enough dense pigmented dentin; floor and walls of cavity are painless at probing. During electric pulp testing (electro odonto-diagnostic method) the pulp reacts on strength of current 6—12 mA.

**Histopathology:** The development of caries leads to some path histological changes in hard tooth tissues and pulp. In an enamel it have practically the same character, as at incipience caries with addition the lesion with the walls consist of broken and accordingly changed enamel prisms. More various are the histological features in a dentine and distinguish such zones.

**Zones of Dentinal Caries (J.B. Summit et al., 2001).**

Caries advancement in dentin proceeds through three changes:

- (1) weak organic acids demineralize the dentin;
- (2) the organic material of the dentin, particularly collagen, degenerates and dis-solves; and
- (3) the loss of structural integrity is followed by invasion of bacteria. Five different zones have been described in carious dentin. The zones are most clearly distinguished in slowly advancing lesions.

In rapidly progressing caries, the difference between the zones becomes less distinct.

**1. Zone of disintegration.** It is characterized by the complete loss of any dentin structure, its almost complete demineralization and softening.

The areas of dentin closer to periphery of lesion are practically destroyed, brown or rather yellow-brown colour. There is considerable accumulation of microorganisms in this dentin, at the chronic caries course - also and pigments. The depth of this destruction zone is different depending on duration and caries: it is enough considerable at acute caries and less at chronic course.

**2. Zone of demineralization.** It is located deeper than previous zone; in it a dentin still saves its structure, but is considerably changed. Dentinal tubules are unevenly extended on comparison with normal. At caries first changes the processes of odontoblasts and not diameter of dentinal tubules. The tubules

broaden unevenly forming cavities, which contain great numbers microorganisms, mainly streptococci. The same bacteria also accumulated in tubules, infected the products of disintegration odontoblasts processes and penetrated into peritubular dentin. There is considerable reduction of quantity of mineral matters revealed in the of dentine matrix.

In the demineralization zone in the direction of pulp there are revealed more frequently the areas of sound dentine with the right structures. These areas are lighter on tooth section. In these areas dentinal tubules are narrower, some of them obliterated and do not contain bacteria. Towards pulp these areas connected together in the continuous layer of so called transparent dentin.

**3. Zone of transparent (sclerotic) dentin.** In this area a dentin completely saves the tubular structure, but its organic matrix heavy mineralized and therefore dentinal tubules are narrowed. Mineral salts are settled down in dentinal tubules and dentin becomes a homogeneous structure. These areas become more transparent on teeth section than surrounding hard tooth tissues.

The high mineralization of dentinal tubules diminishes a difference between the indexes of light refraction of separate structural elements of dentin - obliterated dentinal tubules and organic matrix, therefore a dentin becomes optically homogeneous. A transparent dentine frequently meets at a chronic caries and is almost absent at acute caries. The clinical observations and experimental researches proved a transparent dentine as a protective structure which represents resistance of organism to the pathologic process - caries. A transparent dentin which appears at a chronic caries is characterized by more high micro hardness (R. G. Sinitsin, 1970).

On comparison with normal a transparent dentine is characterized in one case by the increase, and in other - reduction of general degree of mineralization. Thus, its homogeneity does not rely on absolute contents of mineral components, and is connected only with reduction of differences between the light refraction indexes of different dentin structures.

**4. Zone of the visible unchanged dentin** (it can be sometimes almost absent). In it dentin has practically unchanged, dental tubules correctly oriented and contains the odontoblasts processes. The dentin organic matrix also practically unchanged and contained the usual quantity of mineral components. In those case, very strong stimuli (microflora and others), which influence on hard tooth tissues and pulp exceeds their protective possibilities; the protective layer of transparent dentine does not appear. As a result of such irritant action on the odontoblasts some tooth area; their processes in dentinal tubules are undergoing disintegration and the tubules filled by air and bacteria. On tooth section such empty tubules are black painted and known as «dead tracts». Clinically at probing of such areas there are practically complete absence of sensitiveness.

**5. Zone of the secondary (reparative) dentin.** As a defence reaction on caries development the cellular elements of pulp - odontoblasts — react by increasing of dentinogenesis - formation of the secondary dentin. It produced



directed against a specific area in places closer to caries cavity and served as protective barrier for pulp. A new formed dentin has an enough irregular structure: there are areas which contain dentinal tubules (regular dentine) and present areas without tubules (irregular dentine). Secondary dentin is more mineralized than primary dentine, and that is more resistance to caries development. Formation of the secondary dentine is the defence pulp reaction. **There is another systematic of these zones.**

**Zone 1: Normal dentin.** The deepest area is normal dentin, which has tubules with odontoblastic processes that are smooth, and no crystals are in the lumens. The intertubular dentin has normal cross-banded collagen and normal dense apatite crystals. No bacteria are in the tubules. Stimulation of the dentin (e.g., by osmotic gradient from applied sucrose or salt], a bur, a dragging instrument, or desiccation from heat or air), produces a sharp pain.

**Zone 2: Sub transparent dentin.** Next is the sub transparent layer, which is a zone of demineralization of the intertubular dentin and initial formation of very fine crystals in the tubule lumen at the advancing front. Damage to the odontoblastic process is evident; however, no bacteria are found in the zone. Stimulation of the dentin produces pain, and the dentin is capable of remineralization.

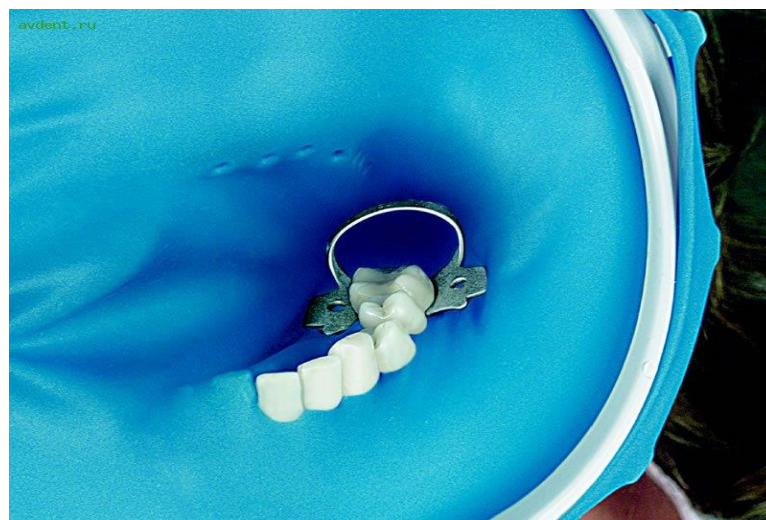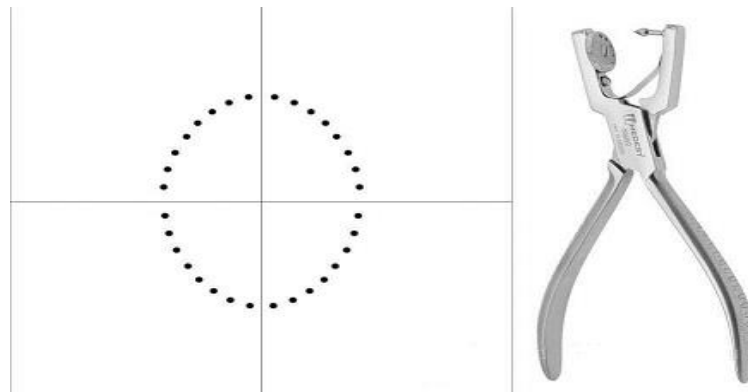
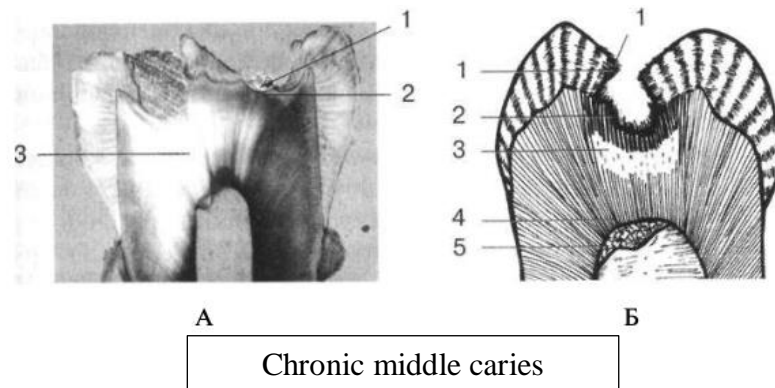
**Zone 3: Transparent dentin.** The transparent layer is a zone of carious dentin that is softer than normal dentin and shows further loss of mineral from the inter-tubular dentin and many large crystals in the lumen of the dentinal tubules. Stimulation of this region produces pain. No bacteria are present.

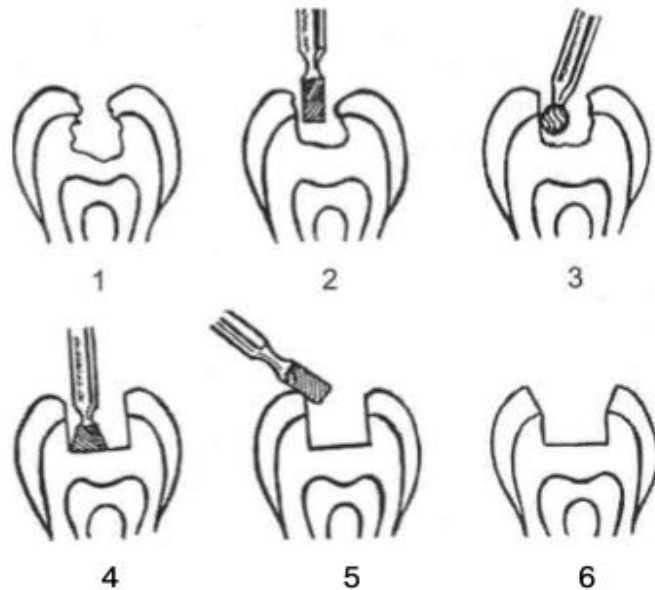
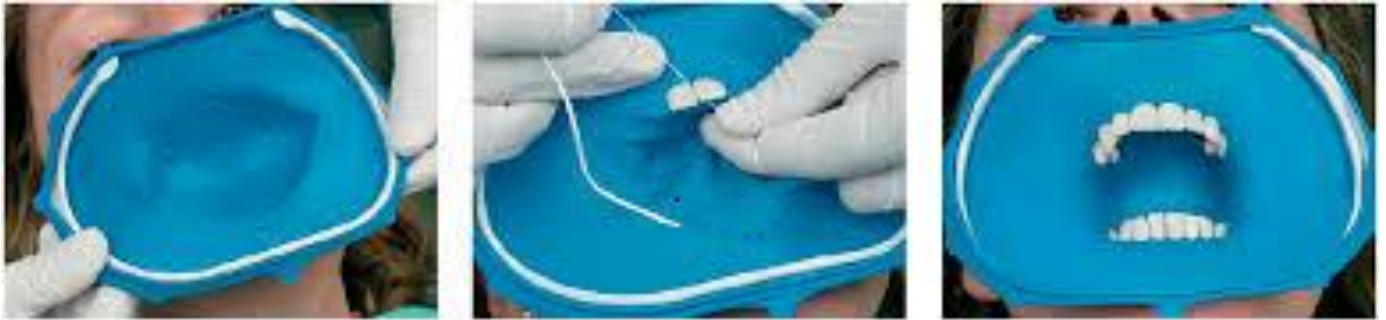Although organic acids attack both the mineral and organic content of the dentin, the collagen cross-linking remains intact in this zone. The intact collagen can serve as a template for remineralization of the intertubular dentin, and thus this region remains capable of self-repair provided the pulp remains vital.

**Zone 4: Turbid dentin.** Turbid dentin is the zone of bacterial invasion and is marked by widening and distortion of the dentinal tubules, which are filled with bacteria. There is very little mineral present and the collagen in this zone is irreversibly denatured. The dentin in this zone will not self-repair. This zone cannot be remineralized and must be removed before restoration.

**Zone 5: Infected dentin.** The outermost zone, infected dentin, consists of decomposed dentin that is teeming with bacteria. There is no recognizable structure to the dentin and collagen and mineral seem to be absent. Great numbers of bacteria are dispersed in this granular material. Removal of infected dentin is essential to sound, successful restorative procedures as well as prevention of spreading the infection. All these areas are best distinguished at the chronic course of middle caries. At acute caries it prevailed that the processes of destruction and demineralization in all dentin depth up to the pulp. Also there is not formation transparent and secondary dentin, therefore proper zones on tooth sections are absent. The substantial changes of different pulp components are revealed: the intercellular matter becomes transparent, widening distances

between separate collagen fibres. Odontoblasts lose their specific structure, their cytoplasm becomes homogeneous and electron dense, which evidenced of the odontoblasts damage. Blood vessels widened, there are breaks of capillaries walls, penetration leucocytes and erythrocytes into pulp tissue. There is disorganization of odontoblastic er, destruction of nervous fibres and further development of inflammatory changes in pulp. These changes depend of the caries course: they are most expressed at acute course.



*Rubber dam***IV. Control questions for the class topic:**

1. What is the etiology of medium caries?
2. What is the pathomorphology of medium caries?
3. What types of medium caries do you know and what is their course?
4. Differential diagnosis of medium caries with other dental diseases.
5. Diagnosis of medium caries.
6. How to treat medium caries?

**V. Control test tasks and/or case tasks:**

1. Patients with acute medium caries complain of:
  - A. Pain while eating;
  - B. Night pain;
  - C. Pain when biting;
  - D. Tooth reaction to sweets;
  - E. Pain radiating to the temple.

**The correct answer is: A, D.**

2. Differential diagnosis of medium caries is carried out with:
  - A. Hypoplasia;
  - B. Fluorosis;

- C. Initial caries;
- D. Chronic periodontitis;
- E. All answers are correct.

**The correct answer is D.**

3. Differential diagnosis of medium caries is carried out with the help of:

- A. Anaesthesia test;
- B. Caries markers;
- C. Test for preparation
- D. X-ray diagnostics
- E. EOD

**The correct answer is: D, E.**

4. When a carious cavity is located on the vestibular surface of the anterior teeth and premolars, it is filled with: composites, compomers, glass ionomer, silicate cements;

- A. Composites;
- B. Composites;
- C. Glass ionomer cements;
- D. Silicate cements;
- E. All answers are correct

**The correct answer is: E.**

5. What is the differential diagnosis of medium caries with deep caries?

**The correct answer is:** The differential diagnosis of medium and deep caries is based on the patient's complaints, the depth and size of the carious cavity, and the sensitivity of its various areas during probing. Particular attention should be paid to carious cavities located on the contact surfaces of the lower frontal teeth, where, due to the small thickness of the hard tissues, deep caries has very small linear dimensions in depth. In acute deep caries, after careful necrectomy of softened dentin, a pink pulp begins to show through at the bottom of the cavity.

6. What is the differential diagnosis of medium caries with chronic periodontitis?

**Correct answer:** Medium caries can occur without significant pain, which necessitates its differential diagnosis with chronic periodontitis. They are distinguished by the absence of pain during probing and preparation of the carious cavity, the presence of an open tooth cavity with necrotic pulp, discolouration of the crowns of the teeth, and characteristic radiological manifestations in the periodontium. Percussion of such teeth is painless, in the case of electroodontodiagnostics they react to a current of more than 100  $\mu\text{A}$  (in case of caries - 2-6  $\mu\text{A}$ ).7. What is the differential diagnosis of superficial caries with medium caries?

7. What is the treatment of medium caries?

**Correct answer:** Conservative remineralisation therapy is ineffective in the case of a carious defect in the hard tissues of the teeth (superficial, medium and deep caries), as enamel and dentin are unable to regenerate and restore the lost areas. To treat hard tissue caries, it is necessary to replace the defect with artificial filling

materials. Prior to this, appropriate surgical treatment, i.e. preparation of the carious cavity, is carried out according to the relevant rules. Its purpose is to completely remove (excise) pathologically altered hard tooth tissues and create conditions for reliable fixation of the filling. Then the prepared carious cavity is filled with filling materials, which restores the anatomical shape and function of the tooth.

## LIST OF REFERENCES

### Main literature

1. Stomatology: textbook: in 2 books. Book I / M.M. Rozhko, Z.B. Popovych, V.D. Kuroiedova et al.: edited by M.M. Rozhko. – Kyiv: AUS Medicine Publishing, 2020. – 792 p.: color edition.
2. Periodontal and Oral Mucosa Diseases: textbook. Vol. 2 / A.V. Borsenko, L.V. Lynovytska, O.F. Nesyn et al.; edited by A.V. Borysenko. - Kyiv: AUS Medicine Publishing, 2018. – 624 p.; color edition.
3. Stomatology: textbook: in 2 books. Book 2 / M.M. Rozhko, I.I. Kyrylenko, O. H. Denysenko et al.; edited by M. M. Rozhko. – Kyiv: AUS Medicine Publishing, 2018. – 960 p.; color edition.

### Additional literature

1. Esthetic Dentistry: A Clinical Approach to Techniques and Materials 3rd Edition by Kenneth W. Aschheim. Publisher: Mosby; 3rd edition, 2014. – 600 p.
2. Esthetic and Restorative Dentistry: Material Selection and Technique 3rd Edition by Douglas A Terry, Willi Geller. Publisher: Quintessence Publishing Co Inc.; 3rd edition, 2017. – 776 p.
3. Dental Composite Materials for Direct Restorations Softcover reprint of the original 1st ed. by Vesna Miletic. Publisher: Springer; 1st edition, 2018. – 327 p.
4. Posterior Direct Restorations 1st Edition by Salvatore Scolavino, Gaetano Paolone. Publisher: Quintessence Pub Co; 1st edition, 2021. – 264 p.
5. Smile Design Integrating Esthetics and Function Essentials of Esthetic Dentistry Volume Two by Jonathan B. Levine. Elsevier Health Sciences, 2015. – 240 p.
6. Cohen's Pathways of the Pulp 12th Edition by Louis H. Berman, Kenneth M. Hargreaves. Publisher: Elsevier; 12th edition, 2020. –992 p.

## Lesson №6

### **TOPIC: Acute and chronic deep caries: pathomorphology, clinic, diagnosis, intra- and extra-syndromic differential diagnosis.**

**I. Topic relevance:** Complications caused by caries lead to a significant impairment of chewing efficiency, which is subsequently manifested by various pathologies of the gastrointestinal tract and disruption of many types of metabolism. Cosmetic defects in carious lesions often cause a lot of moral suffering and psycho-emotional trauma to patients. Knowledge of the manifestations of caries at its various stages is essential for future dentists to successfully diagnose, treat and reliably prevent the most common dental disease.

### **II. Study goal:**

#### **2.1. Student has to know:**

- Know the definition of dental caries;
- Know the etiology of deep caries;
- Know the pathomorphology of deep caries;
- Know the patient's complaints in case of deep caries;
- Know the diagnosis and differential diagnosis of deep caries;
- Know the methods of treatment of deep caries.

#### **2.2 Be able to:**

- Be able to determine the etiology of deep caries;
- Be able to determine the course of deep caries;
- Be able to differentiate deep caries from other dental diseases;
- Be able to diagnose deep caries;
- Be able to choose the right treatment for deep caries.

### **III. Content of the topic**

**Deep caries (caries profunda):** It is characterized by formation of caries cavity which affected almost all layers of dentine practically to pulp and located in cir-cumpulpal dentin. Patients with acute deep caries complain of causal pain which arises up because of action of thermal, mechanical, chemical irritants and disappears after their removal. Inserting into the carious cavity a cotton pellet with hot (no more than 50 degrees C) or cold water, and also either, as a rule, is accompanied by the sharp pain reaction, nevertheless, pain disappears after the removal of the irritant from the cavity. Carious cavity is located within the limits of cir-cumpulpal dentin with the overhanging margins of enamel. Enamel around the entrance of the cavity softened chalky white colour.

A caries cavity is filled with softened dentin, grey-whitish or yellow colour. At probing it revealed a painful area at the floor of the cavity and dentinoenamel junction. Frequently it is the places of projection of pulp horns, which directly react on irritants; nevertheless, perforation of carious cavity is absent. At acute deep caries, probing of caries cavity floor must be made very carefully. In the points of pulp horns projection of the dentinal wall is very thin, a dentine is softened and may be easily pierced by a probe and injures the pulp. It is accompanied by a sharp pain and the appearance in the carious cavity a drop of blood.

*At the chronic deep caries* the complaints on pain can be absent or an insignificant, brief pain after thermal, chemical and mechanical irritants is revealed. Defect of hard tooth tissues located in limits of circumpulpal dentin, large enough in size and occupies a considerable part of tooth crown. Cavity is wide opened outside (the overhanging edges of enamel are broken off because of their fragility). Hereupon the transversal sizes of cavity exceed its depth. A wall and floor of carious cavity is filled to enough dense, pigmented dentin but without sclerotic brilliance.

*Pigmentation* of its walls and floor has an enough wide spectrum - from yellow-brown to brown and even almost black colour. Probing of walls and floor of cavity is painless, because of development under them well expressed areas of transparent and secondary dentin. Surface of carious dentine is rough when probing and it is heavy enough to excavate. Development of such cavity lasts for years. Along with the traditional methods of examination in caries diagnostics, use of an electric method - electro testing of nervous receptors of pulp and periodontal ligament - electro odonto-diagnostic. It was revealed that intact tooth pulp and also teeth with caries reacts on strength of current within the limits of 2-6 mA. In case of a deep caries degenerative changes in pulp are more expressed, so it reacts on 15-20 mA. After the correct medical treatment the excitability of pulp is gradually restored.

Decline of excitability within the limits of 15-60 mA point at the prevailing inflammatory process crown pulp, 60-100 mA - diffuse inflammation in all (crown and root) pulp. Decline of excitability more than 100 mA, point at death of pulp and reaction on the electric current nervous receptors of periodontal ligament.

**Histopathology:** The pathohistological features in hard tooth tissues are practically the same as at a middle caries. Sometimes, because of small thickness of dentinal partition between a carious cavity and pulp, not all zones of lesion can be expressed. At the acute caries course there is the predominance of the demineralization processes. Common reduction of the cellular elements number, hyperemia and edema of pulp, perivascular infiltrates, and increase nervous fibres thickness are revealed in pulp. Except of the acute and chronic caries course in a clinical conditions there is distinguished the most rampant caries - caries acutissima and arrested (stationary caries or caries stationary).

**Caries acutissima** often arises up in a child's age weakened by different systemic children's' diseases. In adults it can arise as a complication after surgical removing of salivary glands and because of the absence a selection of saliva, the xerostomia («dry mouth») develops. Thus the processes of remin-eralization of the hard tooth tissues by saliva are seriously violated and results in the caries development. It is characterized by the very rapid (within the limits of 2-5 weeks) development of carious lesions. The numerous lesions developed on most teeth with formation of a few cavities on the one tooth crown.

Enamel on the areas of lesion heavy demineralized, chalky white colour, a dentine is softened to cartilage consistency, its layers easily removed by excavator. The carious lesions developed very quickly from the incipience lesion to deep cavity and almost develop caries complications - inflammation of pulp (pulpitis) and periodontal ligament (apical periodontitis). Histopathology: The pathohistological features of this caries form are characterized by the predominance of the demineralization processes with the destruction of hard tooth tissues. The defence reactive zones (sclerotic, secondary dentin) are practically absent. The clinical variant of such caries course is known as caries florida.

**Arrested (stationary) caries or halted caries** is considered as variant of chronic caries development. At favorable conditions and sufficient organism resistance the caries development stopped and carious cavity does not spread deep into hard tooth tissues. In hard tooth tissues this caries form may be consider as an original «scar», that indicates on the caries process, because of the hard tooth tissues are not regenerated. In case of incipient caries it is possible to speak about demineralization affected hard tooth tissues.

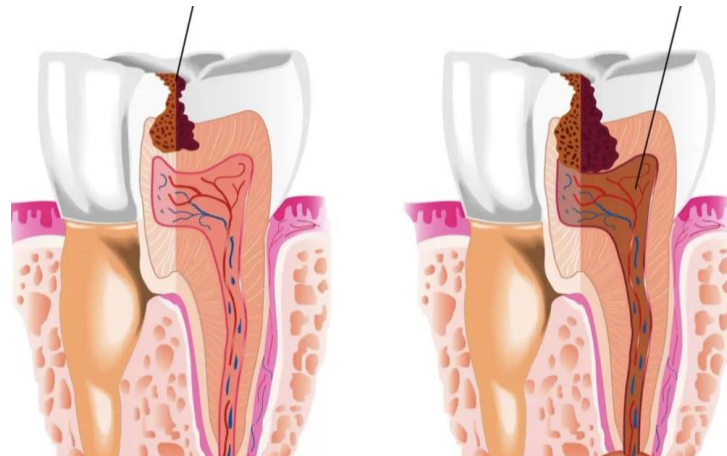
A white carious spot can fully disappeared; brown (pig-mented) carious spots because of the expressed pigmentation are remained pigmented on enamel even after stopping of the caries process. Initial and the subsequent stages of arrested caries development are characterized by the intensive (dark-brown) dentine colour in the lesion. The pain feeling are fully absent because of high enamel and dentine mineralization in carious cavity. The affected hard tooth tissues had practically the same or and even more high degree of mineralization of hard tooth tissues. In some cases protective mineralization is so expressed, that a dentin becomes glassy and had considerable barrier properties. Even in a deep carious cavity is not feeling of pain in action of any (chemical, mechanical, thermal and that similar) irritants. The high level of mineralization of the affected hard tooth tissues results in such a state, that when because of unfavorable conditions begin, there is further caries progress so new lesions appear on other surfaces of the tooth and not at the place of high mineralized arrested (stationary) caries.

**A stationary caries** is frequently the result of the original development of chronic caries. The defects of hard tooth tissues have the wide entrance opening, which exposed a saucer like form. At very deep carious cavities their floor can



already be within limits of the secondary dentine, that it is placed below than level of vault pulp chambers. It is explained by very slow development of caries, which destroyed not only primary dentine and spread within the limits of the secondary dentine.

Because of such chronic caries course the pulp has enough time to form the considerable protective layer of the secondary dentin. There is not the perforation of pulp chamber, infection of pulp and pulpitis development. The caries is characterized by causal pain, which arises only because of the action of different (chemical, thermal, mechanical) irritants and disappears at once after stopping of irritant action. Unlike pulpitis pain it is localized and never is there an irradiation of pain into other places of maxillary-facial regions. The disease duration in case of acute course can be within the limits of a few months, while at chronic - months and for years.



#### **IV. Control questions for the class topic:**

1. What etiology of deep caries do you know?
2. What is the pathomorphology of deep caries?
3. What types of deep caries do you know and what is their course?
4. Differential diagnosis of deep caries with other dental diseases.
5. Diagnosis of deep caries.

#### **V. Control test tasks and/or case tasks:**

1. Patients with acute medium caries complain of:
  - A. Pain while eating;
  - B. Night pain;
  - C. Pain when biting;
  - D. Tooth reaction to sweets;
  - E. Pain radiating to the temple.

**The correct answer is: A, D.**

2. Differential diagnosis of deep caries is carried out with:
  - A. Hypoplasia;

- B. Fluorosis;
- C. Gangrenous pulpitis;
- D. Chronic periodontitis;
- E. All answers are correct.

**The correct answer is: D.**

3. Differential diagnosis of medium caries is carried out with the help of:

- A. Anaesthesia test;
- B. Caries markers;
- C. Test for preparation
- D. X-ray diagnostics
- E. EOD

**The correct answer is: D, E.**

4. When a carious cavity is located on the vestibular surface of the anterior teeth and premolars, it is filled with: composites, compomers, glass ionomer, silicate cements;

- A. Composites;
- B. Composites;
- C. Glass ionomer cements;
- D. Silicate cements;
- E. All answers are correct

**The correct answer is: E.**

5. What is the differential diagnosis of medium caries with deep caries?

**The correct answer is:** The differential diagnosis of medium and deep caries is based on the patient's complaints, the depth and size of the carious cavity, and the sensitivity of its various areas during probing. Particular attention should be paid to carious cavities located on the contact surfaces of the lower frontal teeth, where, due to the small thickness of the hard tissues, deep caries has very small linear dimensions in depth. In acute deep caries, after careful necrectomy of softened dentin, a pink pulp begins to show through at the bottom of the cavity.

6. What is the differential diagnosis of deep caries with chronic simple pulpitis?

**Correct answer:** The similarity with chronic simple pulpitis lies in the presence of a deep carious cavity, but in acute deep caries the entrance opening is narrow, and in chronic simple pulpitis it is wide. In both cases, chemical, temperature, mechanical irritants cause pain, but after the irritant is eliminated, the pain disappears in caries, and in pulpitis it disturbs the patient for some time. In chronic pulpitis, the carious cavity communicates with the tooth cavity in 70% of cases, probing is sharp and painful at the junction, and may bleed.

In case of deep acute caries, EOD causes pain at 10-18  $\mu$ A, and in case of chronic simple pulpitis, pain occurs in response to irritation at 30-40  $\mu$ A.

7. What is the differential diagnosis of deep caries with chronic hypertrophic and chronic gangrenous pulpitis?

**Correct answer:** The diagnosis of chronic hypertrophic and chronic gangrenous pulpitis can be excluded immediately, because in these forms of pulpitis, the

carious cavity is widely communicated with the pulp chamber. Moreover, in hypertrophic pulpitis, pathologically overgrown granulations are visible from the perforation hole, and in gangrenous pulpitis, only deep probing is painful.

## LIST OF REFERENCES

### Main literature

1. Stomatology: textbook: in 2 books. Book I / M.M. Rozhko, Z.B. Popovych, V.D. Kuroiedova et al.: edited by M.M. Rozhko. – Kyiv: AUS Medicine Publishing, 2020. – 792 p.: color edition.
2. Periodontal and Oral Mucosa Diseases: textbook. Vol. 2 / A.V. Borsenko, L.V. Lynovytska, O.F. Nesyn et al.; edited by A.V. Borysenko. - Kyiv: AUS Medicine Publishing, 2018. – 624 p.; color edition.
3. Stomatology: textbook: in 2 books. Book 2 / M.M. Rozhko, I.I. Kyrylenko, O. H. Denysenko et al.; edited by M. M. Rozhko. – Kyiv: AUS Medicine Publishing, 2018. – 960 p.; color edition.

### Additional literature

1. Esthetic Dentistry: A Clinical Approach to Techniques and Materials 3rd Edition by Kenneth W. Aschheim. Publisher: Mosby; 3rd edition, 2014. – 600 p.
2. Esthetic and Restorative Dentistry: Material Selection and Technique 3rd Edition by Douglas A Terry, Willi Geller. Publisher: Quintessence Publishing Co Inc.; 3rd edition, 2017. – 776 p.
3. Dental Composite Materials for Direct Restorations Softcover reprint of the original 1st ed. by Vesna Miletic. Publisher: Springer; 1st edition, 2018. – 327 p.
4. Posterior Direct Restorations 1st Edition by Salvatore Scolavino, Gaetano Paolone. Publisher: Quintessence Pub Co; 1st edition, 2021. – 264 p.
5. Smile Design Integrating Esthetics and Function Essentials of Esthetic Dentistry Volume Two by Jonathan B. Levine. Elsevier Health Sciences, 2015. – 240 p.
6. Cohen's Pathways of the Pulp 12th Edition by Louis H. Berman, Kenneth M. Hargreaves. Publisher: Elsevier; 12th edition, 2020. –992 p.

## METHODOLOGICAL RESEARCH №7

### TOPIC: One-session and two-session methods of treatment of acute deep caries. Therapeutic pastes: groups, properties, methods of use.

**I. Topic relevance:** Modern methods of caries treatment and prevention require certain knowledge and skills from the student. Planning the treatment and prevention of caries, taking into account etiological, pathogenetic factors based on clinical, laboratory, instrumental research methods, allows you to plan and implement treatment and prevention measures.

#### II. Study goal:

##### 2.1. Student has to know:

- Know the definition of dental caries;
- Know the methods of treatment of deep caries;
- To know the peculiarities of the one-session method of treating deep caries;
- To know the peculiarities of the two-session method of deep caries treatment;
- Know the groups of therapeutic pastes and their properties;
- Know the methods of using therapeutic pastes.

##### 2.2 Be able to:

- Be able to determine the method of treatment of deep caries;
- Be able to determine the course of deep caries;
- To be able to treat acute caries with a one-session technique;
- To be able to treat deep caries using a two-session technique;
- To be able to select therapeutic pastes for deep caries.

#### III. Content of the topic

Medical treatment of caries consists of a row of measures of both general and local character depending on the stage of development of pathological process and character of its course.

When a pathological process spreads to enamelodentinal junction, strikes a dentine and appears carious cavity, conservative (remineralization) therapy can not result in success. It is connected with such condition that hard tooth tissues do not possess property to regenerate the primary form in the area of caries lesion. Therefore for local medical treatment of carious cavities their preparation is used, with the subsequent restoration of cavity and renewal of anatomic form of tooth by filling material. How justly mark B. Helvig, Y. Klimek, T. Attin 1999) it is presently observed the tendency to refuse of principle «only restoration effectively protects from caries» in favour to primary atraumatic restorative

treatment or minimal invasive treatment with the subsequent control of surfaces affected by caries. Neither of the varieties of restoration treatment of dental caries may be fully «curing». Destroyed by a caries hard tooth tissues (and adjoining areas of healthy enamel) are not substituted for by formed again enamel and dentin. Besides, there is no existing restorative material capable during all life to protect hard tooth tissues from further destructive caries processes. Tooth restoration is only symptomatic treatment which does not eliminate the etiologic factors of dental caries.

Therefore for local medical treatment of carious cavities their preparation is used, with the subsequent restoration of cavity and renewal of anatomic form of tooth by filling material. How justly mark B. Helvig, Y. Klimek, T. Attin 1999) it is presently observed the tendency to refuse of principle «only restoration effectively protects from caries» in favour to primary atraumatic restorative treatment or minimal invasive treatment with the subsequent control of surfaces affected by caries. Neither of the varieties of restoration treatment of dental caries may be fully «curing».

Destroyed by a caries hard tooth tissues (and adjoining areas of healthy enamel) are not substituted for by formed again enamel and dentin. Besides, there is no existing restorative material capable during all life to protect hard tooth tissues from further destructive caries processes. Tooth restoration is only symptomatic treatment which does not eliminate the etiologic factors of dental caries. Therefore the prevention of development caries lesions (prophylactic measures) is the basic principle of caries treatment, rather than the necessary medical treatment (remineralization therapy) and, in the last turn, as the forced measure of restoration the caries cavity with restorative materials, conducted along with the measures of the second caries prophylaxis.

Thus, now there are two main methods of local caries treatment: 1) caries treatment without preparation and restoration - remineralization therapy, and 2) operative caries treatment by the operative preparation of demineralized hard tooth tissues with the subsequent restoration of carious cavity. The choice of treatment method depends of the stage of caries development, activity of caries (rampant or chronic), localization of carious cavity, age and general condition of patient.

Preventive treatment methods are designed to limit tooth demineralization caused by cariogenic bacteria, thereby preventing cavitated lesions.

**They include:**

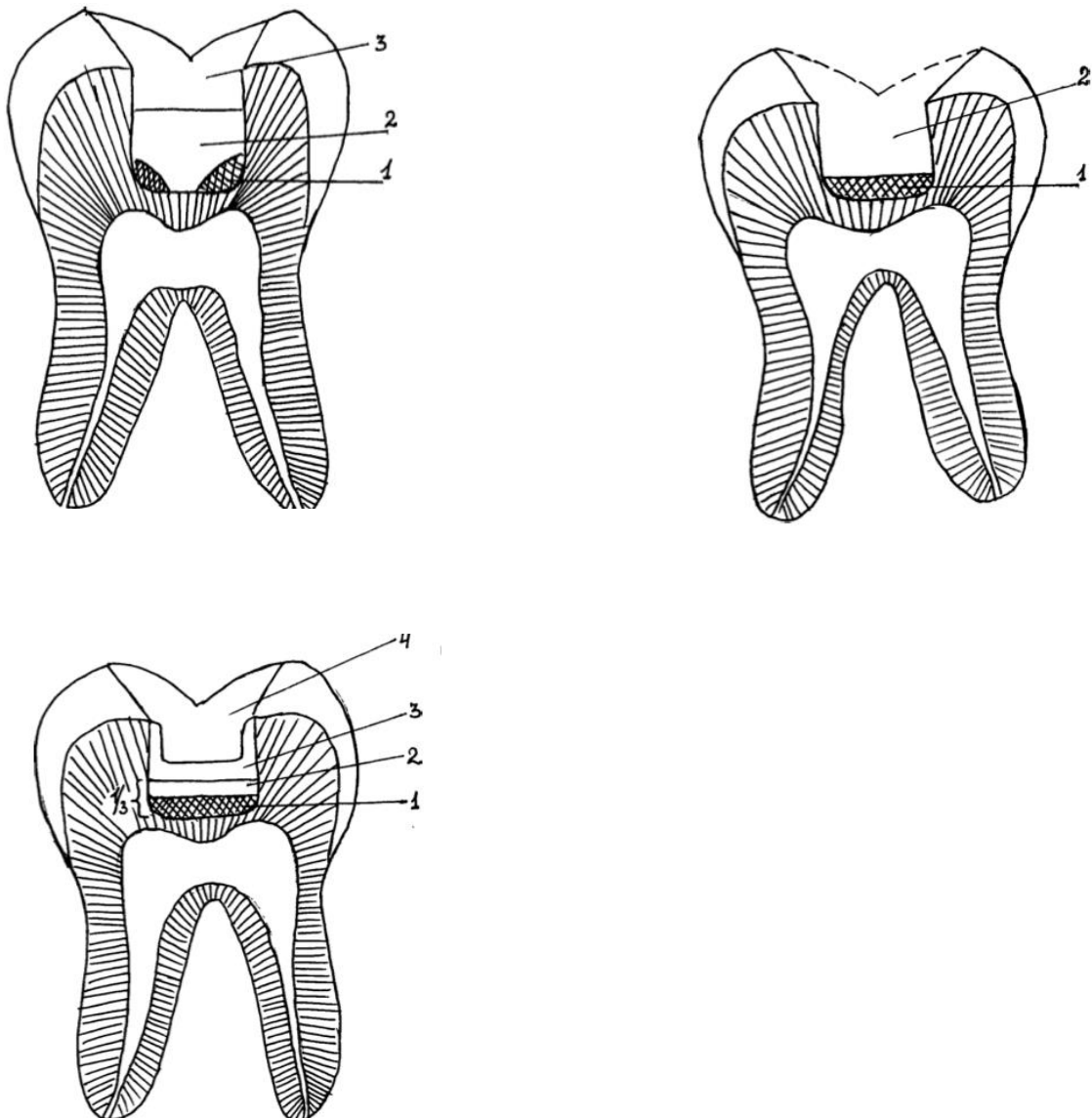
- (1) limiting pathogen growth and metabolism
- (2) increasing the resistance of the tooth surface to demineralization.

Disease caries control concerns influencing biofilm formation and growth, or modifying the dissolution kinetics of the apatites, or both.

The following may have a role to play:

- mechanical/chemical removal of plaque (oral hygiene)
- chemical (antimicrobial) modification of plaque

- use of fluorides
- dietary composition
- salivary composition and stimulation.



#### IV. Control questions for the class topic:

1. What types of treatment for deep caries do you know?
2. What is the difference between one-session and two-session treatment of deep caries?
3. How is the treatment of deep caries carried out using the one-session method?
4. How is the treatment of deep caries carried out using the two-session method?
5. What medicinal pastes do you know?

#### V. Control test tasks and/or case tasks:

1. A 35-year-old patient complains of a cavity in the left lower jaw tooth, pain from sweet, sour and solid foods. Examination of tooth 36 revealed a deep carious cavity filled with light softened dentin. Probing is sensitive along the bottom of the carious cavity, the reaction to cold is painful and quickly passes. What is the most likely diagnosis?

- A. Acute deep caries.
- B. Chronic deep caries.
- C. Acute medium caries.
- D. Chronic medium caries.
- E. Hyperemia of the pulp.

**The correct answer is: A.**

2. The patient complains of food stuck in the tooth on the upper jaw on the right. Four months ago, this tooth had pain from sweet and cold foods. After cessation of the irritant, the pain quickly subsided. The examination of 15 revealed a deep carious cavity. The dentin of the cavity floor and walls was dense and pigmented. When probing the bottom and walls in the area of the enamel-dentin border, a slight tenderness is determined. EOD gives the sensitivity of the tooth to a current of 10  $\mu$ A. Make a diagnosis.

- A. Chronic deep caries.
- B. Acute deep caries.
- C. Acute medium caries.
- D. Chronic medium caries.
- E. Hyperemia of the pulp.

**The correct answer is: A.**

3. Patient K. complains of a carious cavity in the tooth on the upper jaw. When sour, sweet, cold foods get into the cavity, pain occurs in the tooth. The pain disappears after rinsing the tooth with warm water. Examination of the chewing surface of tooth 16 reveals a carious cavity with a narrow entrance hole within the peri pulp dentin. The dentin of the bottom and walls of the cavity is light, softened. The bottom and walls of the cavity are painful to probe. EOD gives a result of 12  $\mu$ A. Make a diagnosis.

- A. Acute deep caries.
- B. Chronic deep caries.
- C. Acute medium caries.
- D. Chronic medium caries.
- E. Hyperemia of the pulp.

**The correct answer is: A.**

4. Patient D., 35 years old, was diagnosed with chronic deep caries 33. The composite material "Degufil" was chosen for filling. What material is most appropriate for the gasket?

- A. Glass ionomer cement.
- B. Cement phosphate with silver.
- C. Dentin paste.

- D. Zinc-eugenol paste.
- E. Eugenol-thymol paste.

**The correct answer is: A.**

5. A 25-year-old woman consulted a dentist with complaints of acute pain in the right lower jaw, which occurs when eating. Objectively: (on the distal chewing surface 45, a deep carious cavity filled with light softened dentin is determined. Probing is slightly painful along the entire bottom, percussion is painless. Cold water causes transient pain. Which of the following agents should be placed at the bottom of the cavity?

- A. Calcium-containing paste.
- B. A paste containing an antibiotic.
- C. Paste containing a corticosteroid.
- D. Bactericidal cement.
- E. Phosphate cement.

**The correct answer is: A.**

## LIST OF REFERENCES

### Main literature

1. Stomatology: textbook: in 2 books. Book I / M.M. Rozhko, Z.B. Popovych, V.D. Kuroiedova et al.: edited by M.M. Rozhko. – Kyiv: AUS Medicine Publishing, 2020. – 792 p.: color edition.
2. Periodontal and Oral Mucosa Diseases: textbook. Vol. 2 / A.V. Borsenko, L.V. Lynovytska, O.F. Nesyn et al.; edited by A.V. Borysenko. - Kyiv: AUS Medicine Publishing, 2018. – 624 p.; color edition.
3. Stomatology: textbook: in 2 books. Book 2 / M.M. Rozhko, I.I. Kyrylenko, O. H. Denysenko et al.; edited by M. M. Rozhko. – Kyiv: AUS Medicine Publishing, 2018. – 960 p.; color edition.

### Additional literature

1. Esthetic Dentistry: A Clinical Approach to Techniques and Materials 3rd Edition by Kenneth W. Aschheim. Publisher: Mosby; 3rd edition, 2014. – 600 p.
2. Esthetic and Restorative Dentistry: Material Selection and Technique 3rd Edition by Douglas A Terry, Willi Geller. Publisher: Quintessence Publishing Co Inc.; 3rd edition, 2017. – 776 p.
3. Dental Composite Materials for Direct Restorations Softcover reprint of the original 1st ed. by Vesna Miletic. Publisher: Springer; 1st edition, 2018. – 327 p.
4. Posterior Direct Restorations 1st Edition by Salvatore Scolavino, Gaetano Paolone. Publisher: Quintessence Pub Co; 1st edition, 2021. – 264 p.



5. Smile Design Integrating Esthetics and Function Essentials of Esthetic Dentistry Volume Two by Jonathan B. Levine. Elsevier Health Sciences, 2015. – 240 p.
6. Cohen's Pathways of the Pulp 12th Edition by Louis H. Berman, Kenneth M. Hargreaves. Publisher: Elsevier; 12th edition, 2020.

## Lesson № 8

### **TOPIC: Prevention of caries. The importance of individual and social prevention. Means of prevention. Organisation of prevention of dental caries in pregnant women, conscripts, workers in certain industries. Evaluation of effectiveness.**

**I. Topic relevance:** The problem of dental caries and periodontal disease has a long history. This interest and constant attention of specialists is due to the high prevalence of these diseases among the majority of the population. At the same time, the world's dental practice convincingly proves that at present, it is possible to preserve intact teeth and periodontal tissues and improve the current situation only through the introduction of dental disease prevention methods into everyday practice. The main goal of prevention is to eliminate the causes of disease onset and development, as well as to create conditions for increasing the body's resistance to environmental factors.

#### **II. Study goal:**

##### **2.1. Student has to know:**

- Know the definition of caries prevention;
- Know what individual prevention is;
- To know public prevention;
- Know what means of caries prevention exist;
- To know how dental caries prevention is organised for pregnant women, conscripts, and workers in certain industries;
- Know how to evaluate the effectiveness of caries prevention.

##### **2.2 Be able to:**

- Be able to explain to the patient the importance of preventive measures;
- To be able to prescribe individual preventive measures to a patient;
- To be able to classify preventive measures;
- To be able to organise caries prevention for patients of different groups.

#### **III. Content of the topic**

*The prevention of development caries lesions (prophylactic measures) is the basic principle of caries treatment, rather than the necessary medical treatment (remineralization therapy) and, in the last turn, as the forced measure of restoration the caries cavity with restorative materials, conducted along with the measures of the second caries prophylaxis.*

Similar properties of hard tooth tissues, and also property of enamel in the physiological condition for mineralization after of teeth eruption (maturation of enam-el) were served as pre-conditions for creation of artificial sources of addition to hard tooth tissues macro - and microelements with the purpose of medical treatment and prophylaxis of caries. On this basis were developed different methods of patho-genetic medical treatment of early stages of tooth (incipience caries) by remineral-ization its hard tissues.

Preventive treatment methods are designed to limit tooth demineralization caused by cariogenic bacteria, thereby preventing cavitated lesions.

**They include:**

- (1) limiting pathogen growth and metabolism
- (2) increasing the resistance of the tooth surface to demineralization.

Disease caries control concerns influencing biofilm formation and growth, or modifying the dissolution kinetics of the apatites, or both.

**The following may have a role to play:**

- mechanical/chemical removal of plaque (oral hygiene)
- chemical (antimicrobial) modification of plaque
- use of fluorides
- dietary composition
- salivary composition and stimulation.

Pit-and-fissure sealants provide a safe and effective method of preventing caries. Sealants are most effective in children when they are applied to the pits and fissures of permanent posterior teeth immediately upon eruption of the clinical crowns. Adults also can benefit from the use of sealants if the individual experiences a change in caries susceptibility because of a change in their diet or medical condition.

**Fluoride treatment** is capable of rendering tooth surfaces more acid resistant and in some circumstances also may arrest active caries. Sealants were designed as a preventive measure, yet studies have shown that deliberately sealing active carious lesions effectively arrests the caries progress by cutting off the nutrient supply to the pathogenic plaque trapped under the sealant. Pits and fissures typically result from an incomplete coalescence of enamel and are particularly prone to caries.

These areas are insufficiently mineralized (as compared with cusps) after tooth eruption. Pits and fissures are the retentive places for accumulation food remnants which can lead to caries development. The fissures sealing hinder these retention and demineralization of enamel by means of microorganism's acid. From the other hand during treatment of incipience.

Regardless of age, caries risk of an individual should be the major factor for selecting teeth for sealant application. Sealants may be indicated for either preventive or therapeutic uses, depending on the patient's caries risk, tooth morphology, or presence of incipient enamel caries. Clinical studies also show

that sealants can be applied even over small, cavi-tated lesions, with no subsequent progression of caries. However, it is recommended that sealants be used for the prevention of caries rather than for the treatment of existing carious lesions. Therefore a recent bitewing radiograph should be made and evaluated before sealant placement, to ensure no dentinal caries is evident.

Only caries-free pits and fissures or incipient lesions in enamel not extending to the den-tinoenamel junction (DEJ) currently are recommended for treatment with pit-and-fissure sealants. Clinical Technique: Because materials and techniques vary, it is important to follow the manufacturer's instructions for the sealant material being used. A standard method for applying sealants to posterior teeth is presented. The tooth is isolated by a rubber dam (or cotton rolls). The isolation of the area is critical to the success of the sealant.

Because sealant placement in younger patients is more common, the molar teeth are often not fully erupted, and therefore isolation is difficult. If proper isolation cannot be obtained, the bond of the sealant material to the occlusal surface will be compromised, resulting in either loss of the sealant or recurrent caries under the seal-ant. The area is cleaned with slurry of pumice on a bristle brush. Bristles reach into faulty areas better than a rubber prophy cup, which tends to burnish debris and pumice into the pits and fissures. The tooth is rinsed thoroughly while the explorer tip is used carefully to help remove residual pumice or additional debris. After the area is dried, a liquid acid etchant (35% to 50% phosphoric acid) may be placed on the occlusal surface with a small sponge, brush, or applicator tip for 30 seconds.

Gel etchants, traditionally used for most restorative procedures, may have less ability to effectively penetrate into the pits and fissures. Next, the tooth is rinsed with water for 20 seconds while the area is evacuated, and then dried of all visible moisture. The properly acid-etched enamel surface has a lightly frosted appearance. Fluoride-rich, resistant enamel may need to be etched lon-ger. Any brown stains that originally may have been in the pits/fissures may still be present and should be allowed to remain. The self-cured sealant is mixed and applied with a small applicator provided in the sealant kit. The sealant is gently teased place, to avoid entrapping air, and it should slightly overfill all pits and fissures. Some operators prefer light-cured sealants, which also work well. After polymerization of the sealant, the rubber dam is removed, and the occlusion is evaluated using articulating paper.

If necessary, a round 12-bladed carbide finishing bur or white stone is used to remove the excess. The surface usually does not require further polishing. Deep penetration into dentin of components forming the composite adhesive system and reliable hermetic sealing of dentinal tubules served by foundation for the empiric use of the adhesive systems at medical treatment of the hyperesthesia of enamel and dentine. Besides the diminishing of the hyperesthesia this preparation protect hard tooth tissues from the abrasion. The manufacturer proposed special preparation - «Seal&Protect» («Dentsply»). It is the mixture of methyl

methacrylate (MMA) monomers on an acetone basis, contains nano fillers and antibacterial remedy — triclosan.

#### **IV. Control questions for the class topic:**

1. What types of caries prevention do you know?
2. What is the function of individual caries prevention?
3. What are the functions of public caries prevention?
4. What is the difference between primary, secondary and tertiary prevention?
5. What methods of group prevention do you know?
6. What is prevention according to the method of application of prophylactic agents?

#### **V. Control test tasks and/or case tasks:**

1. Primary prevention is

A. a system of state, social, hygienic and medical measures aimed at preventing dental diseases by eliminating the causes and conditions of their occurrence, as well as increasing the body's resistance to adverse environmental, industrial and domestic factors.

B. a set of state, social, hygienic, medical measures that can be collective, family and individual and aimed at maintaining health and preventing disease.

C. a set of measures designed for patients who are united by common risk factors for the development of major dental diseases

D. a set of measures aimed at early detection of the disease, prevention of complications, progression and recurrence of dental diseases.

E. a set of measures aimed at rehabilitation of the dental status, based on the preservation of the functional capabilities of organs and tissues of the maxillofacial area, by the method of replacement. These measures in practice are carried out mainly by orthopedists and dental surgeons.

**The correct answer is: A.**

2. Secondary prevention is

A. a system of state, social, hygienic and medical measures aimed at preventing dental diseases by eliminating the causes and conditions of their occurrence, as well as increasing the body's resistance to adverse environmental, industrial and domestic factors.

B. a set of state, social, hygienic, medical measures that can be collective, family and individual and aimed at maintaining health and preventing disease.

C. a set of measures designed for patients who are united by common risk factors for the development of major dental diseases

D. a set of measures aimed at early detection of the disease, prevention of complications, progression and recurrence of dental diseases.

E. a set of measures aimed at rehabilitation of the dental status, based on the preservation of the functional capabilities of organs and tissues of the maxillofacial area, by the method of replacement. These measures in practice are carried out mainly by orthopedists and dental surgeons.

**The correct answer is: D.**

## 3. Tertiary prevention is

A. a system of state, social, hygienic and medical measures aimed at preventing dental diseases by eliminating the causes and conditions of their occurrence, as well as increasing the body's resistance to adverse environmental, industrial and domestic factors.

B. a set of state, social, hygienic, medical measures that can be collective, family and individual and aimed at maintaining health and preventing disease.

C. a set of measures designed for patients who are united by common risk factors for the development of major dental diseases

D. a set of measures aimed at early detection of the disease, prevention of complications, progression and recurrence of dental diseases.

E. a set of measures aimed at rehabilitation of the dental status, based on the preservation of the functional capabilities of organs and tissues of the maxillofacial area, by the method of replacement. These measures in practice are carried out mainly by orthopedists and dental surgeons.

**The correct answer is: E.**

## 4. What are the requirements for a regional prevention programme?

**Correct answer:** The regional prevention programme is developed taking into account local environmental features, social conditions, and the level of health of the population. Requirements for a regional prevention programme (V.G. Suntsov et al., 2001), which should be: comprehensive; long-term; specific; consistent; controlled; medically sound; economically affordable; massive.

## 5. What are the methods of mass prevention of major dental diseases?

**Correct answer:** Methods of mass prevention of major dental diseases include: fluoridation of drinking water, salt, milk in regions with low fluoride content in drinking water; production of therapeutic and preventive oral care products; inclusion of hygiene education aimed at improving the health and medical literacy of the younger generation in school curricula, as well as a number of measures aimed at protecting maternal and child health; improvement of working and living conditions, creation of various children's health centres, and other measures to improve the health of the population.

## LIST OF REFERENCES

**Main literature**

1. Stomatology: textbook: in 2 books. Book I / M.M. Rozhko, Z.B. Popovych, V.D. Kuroiedova et al.: edited by M.M. Rozhko. – Kyiv: AUS Medicine Publishing, 2020. – 792 p.: color edition.

2. Periodontal and Oral Mucosa Diseases: textbook. Vol. 2 / A.V. Borsenko, L.V. Lynovytska, O.F. Nesyn et al.; edited by A.V. Borysenko. - Kyiv: AUS Medicine Publishing, 2018. – 624 p.; color

edition.

3. Stomatology: textbook: in 2 books. Book 2 / M.M. Rozhko, I.I. Kyrylenko, O. H. Denysenko et al.; edited by M. M. Rozhko. – Kyiv: AUS Medicine Publishing, 2018. – 960 p.; color edition.

### **Additional literature**

1. Esthetic Dentistry: A Clinical Approach to Techniques and Materials 3rd Edition by Kenneth W. Aschheim. Publisher: Mosby; 3rd edition, 2014. – 600 p.
2. Esthetic and Restorative Dentistry: Material Selection and Technique 3rd Edition by Douglas A Terry, Willi Geller. Publisher: Quintessence Publishing Co Inc.; 3rd edition, 2017. – 776 p.
3. Dental Composite Materials for Direct Restorations Softcover reprint of the original 1st ed. by Vesna Miletic. Publisher: Springer; 1st edition, 2018. – 327 p.
4. Posterior Direct Restorations 1st Edition by Salvatore Scolavino, Gaetano Paolone. Publisher: Quintessence Pub Co; 1st edition, 2021. – 264 p.
5. Smile Design Integrating Esthetics and Function Essentials of Esthetic Dentistry Volume Two by Jonathan B. Levine. Elsevier Health Sciences, 2015. – 240 p.
6. Cohen's Pathways of the Pulp 12th Edition by Louis H. Berman, Kenneth M. Hargreaves. Publisher: Elsevier; 12th edition, 2020. –992 p.

## Lesson №9

### TOPIC: Non-carious lesions of the teeth.

**Classification, pathomorphology, clinic and diagnostics of non-carious lesions occurring before the eruption of teeth: hypo-, hyperplasia, endemic fluorosis. Classification of dental fluorosis according to A.K. Nikolishin.**

**I. Topic relevance:** In recent years, a number of studies have been conducted to reveal the etiology and pathogenesis of various non-carious lesions that occur before the eruption of teeth, which has allowed the introduction of a number of pathogenetically targeted treatments in the clinic. Therefore, the study of this pathology is undoubtedly relevant and of great interest in the process of forming the clinical thinking of future dentists.

## **II. Study goal:**

### **2.1. Student has to know:**

- Know the etiology of non-carious dental lesions;
- To know the classification of non-carious lesions that occur before the eruption of teeth;
- Know the clinic of diseases of non-carious origin;
- Know the diagnosis of non-carious lesions that develop before the eruption of teeth;
- Know the classification of dental fluorosis.

### **2.2 Be able to:**

- To be able to diagnose non-carious lesions of the hard tissues of the teeth that occur before the eruption of teeth;
- To be able to make a preliminary diagnosis based on the clinic and the course of the disease;
- To be able to diagnose non-carious lesions of the hard tissues of the teeth that occur before the eruption of teeth;
- Be able to classify fluorosis;

## **III. Content of the topic**

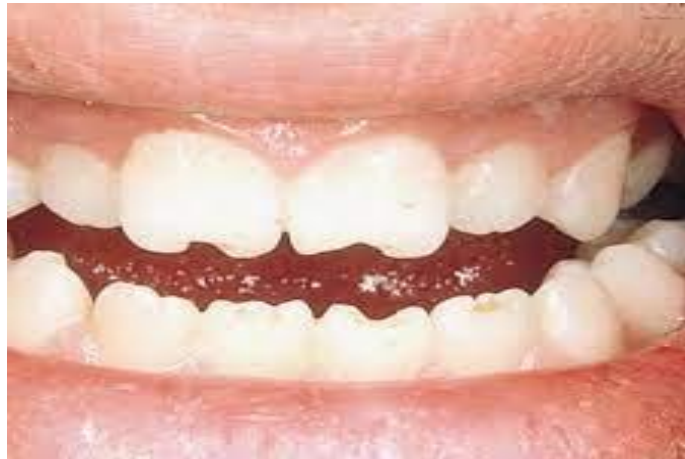### **Non-carious lesions of the teeth**

In addition to caries, the most common dental disease, there is another pathology of hard tissues - non-carious lesions of the teeth.

Non-carious tissue lesions occur without softening of tissues and without the participation of microorganisms. At the heart of these processes is a violation of the mineralization of the hard tissues of the teeth under the influence of external



or internal factors. These pathologies occur in approximately 25% of patients, but seek their help for dental care no more than 5%, because non-carious lesions of the teeth, as a rule, do not cause pain or other subjective sensations, and often only worsen the appearance. However, if left untreated, a number of complications can occur, including early tooth loss.



Dental enamel hypoplasia is an enamel defect characterized by thin or absent enamel. In some cases, the defect occurs on only part of a tooth's surface, resulting in pits or grooves in the tooth's enamel. In other cases, an entire tooth may have an overly thin layer of dental enamel or may have no enamel at all.

Enamel hypoplasia is a *developmental* enamel defect, meaning that is already present at the time the affected tooth first erupts from the gums. In contrast, enamel *wear*, such as dental abrasion and erosion, occurs after a tooth has erupted.

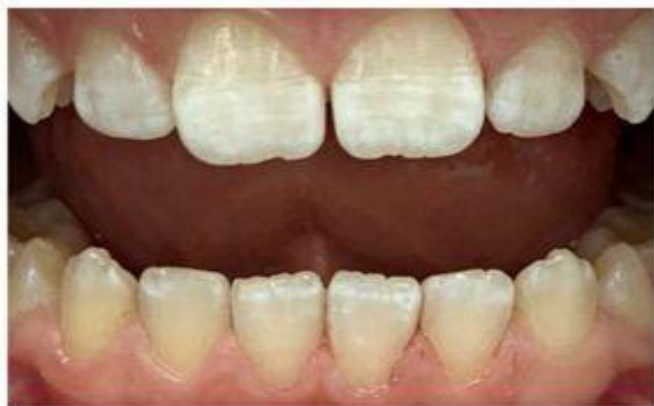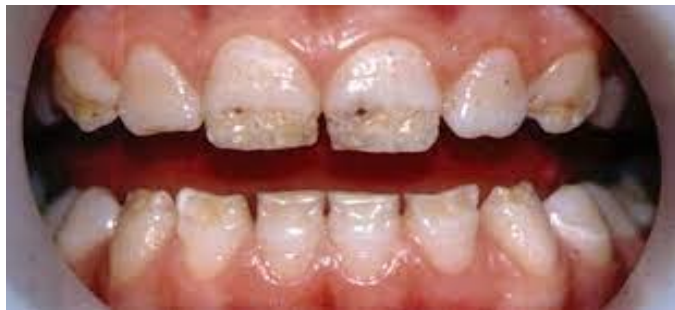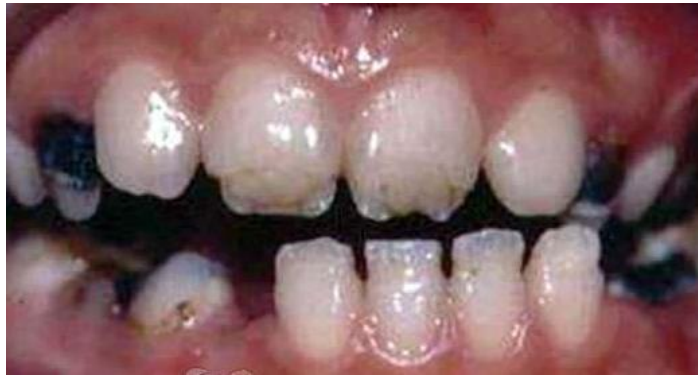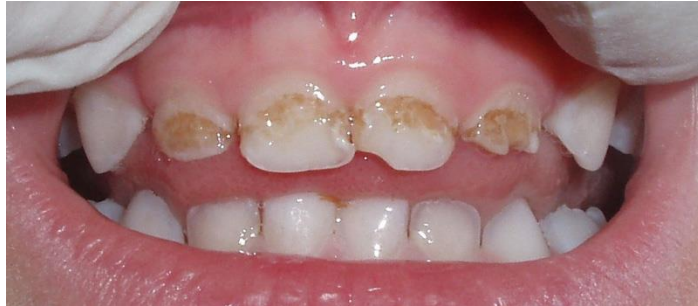**Enamel hypoplasia** occurs when the special cells that produce dental enamel are disturbed during a particular stage of enamel formation (the matrix formation stage). A wide variety of factors can potentially cause such a disturbance, including both genetic and environmental factors.

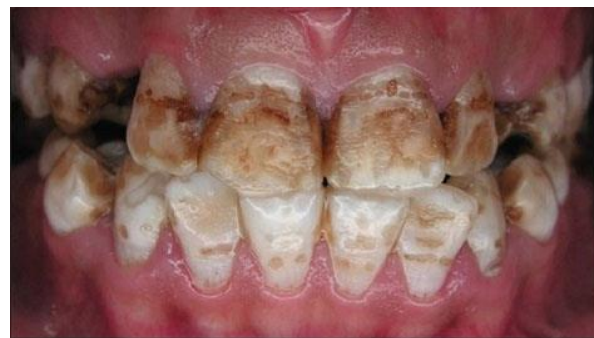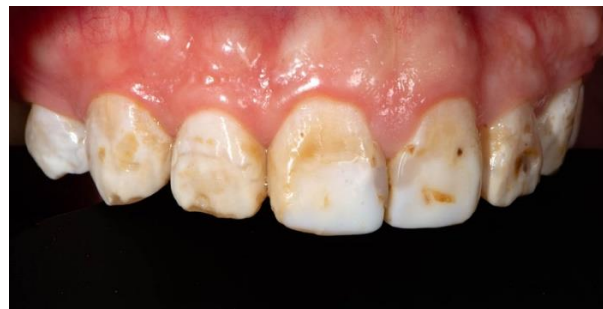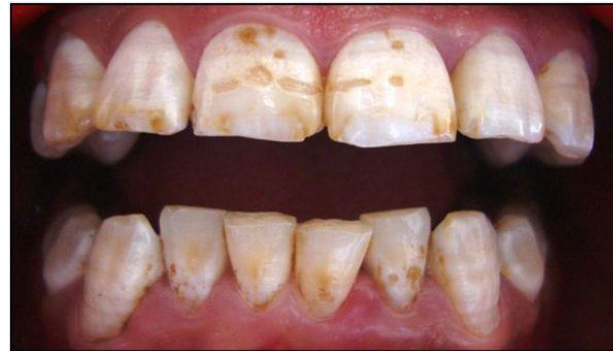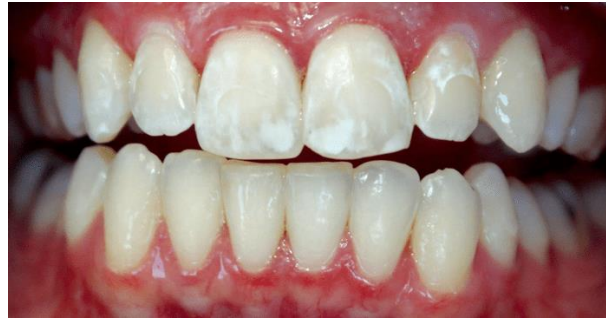The hereditary factors that lead to enamel hypoplasia in children consist primarily of relatively rare genetic disorders, such as amelogenesis imperfecta and Ellis van-Creveld syndrome.

Current research suggests that environmental factors that may increase the risk of enamel hypoplasia in children include the following:

- Premature birth
- Low birth weight
- Malnutrition, including vitamin D deficiency rickets
- Hypoparathyroidism
- Diabetes
- Gestational diabetes in the child's mother
- Viral and bacterial infections, including congenital syphilis

- Inflammation
- Dental trauma
- Ingestion of large amounts of fluoride





**Fluorosis in different forms**

**IV. Control questions for the class topic:**

1. What are non-carious dental lesions?
2. What is the classification of non-carious lesions of teeth before teething?
3. What is enamel hypoplasia?
4. What types of hypoplasia do you know?
5. What is the clinic and diagnosis of enamel hypoplasia?
6. What is the treatment of enamel hypoplasia depending on the course?

7. What classification of fluorosis do you know?
8. What is the clinic and diagnosis of dental fluorosis?
9. What types of dental fluorosis treatment do you know?

**V. Control test tasks and/or case tasks:**

1. Non-carious lesions that occur before the eruption of teeth, according to the Patrykeev classification, include:
  - A) enamel hyperplasia;
  - B) wedge-shaped defect;
  - C) acid necrosis;
  - D) hyperesthesia;
  - E) tooth erosion.

**The correct answer is: A.**

2. Non-carious lesions that occur before the eruption of teeth, according to the Patrykeev classification, include:
  - A) fluorosis;
  - B) wedge-shaped defect;
  - C) acid necrosis;
  - D) hyperesthesia;
  - E) dental erosion.

**The correct answer is: A.**

3. Non-carious lesions that occur before the eruption of teeth, according to the Patrykeev classification, include:
  - A) acid necrosis;
  - B) hyperesthesia;
  - C) tooth erosion;
  - D) hereditary disorders of dental development;
  - E) wedge-shaped defect.

**The correct answer is: D.**

4. Non-carious lesions that occur before the eruption of teeth, according to the Patrykeev classification, include:
  - A) wedge-shaped defect;
  - B) acid necrosis;
  - C) hyperesthesia;
  - D) tooth erosion;
  - E) enamel hypoplasia.

**The correct answer is: E.**

5. A 20-year-old patient complains about the unaesthetic appearance of 24 from the moment of eruption. Objectively: in 24 enamel is partially absent, dentin is yellow. In childhood, 64 was repeatedly treated, however, due to frequent exacerbations, swelling, fistula on the gums, 64 was forced to be removed at the age of 9. What is the most likely diagnosis?

- A. Localised hypoplasia
- B. Systemic hypoplasia

- C. Primary caries
- D. Fluorosis
- E. Enamel aplasia

**The correct answer is: A.**

6. A 23-year-old patient turned to a dentist with complaints of a cosmetic defect in the form of light spots on the teeth. At the place of residence, the presence of fluoride in drinking water is 1 mg/l. Objectively: on the vestibular surface of the crowns of 11, 12, 21, 22 and the humps of 16, 26, 36, 46 teeth there are chalk-like spots with a shiny surface that have existed since the eruption of the teeth. What is the most likely diagnosis?

- A. Systemic enamel hypoplasia
- B. Endemic fluorosis
- C. Imperfect amelogenesis
- D. Multiple initial caries
- E. Enamel erosion

**The correct answer is: A.**

## LIST OF REFERENCES

### Main literature

1. Stomatology: textbook: in 2 books. Book I / M.M. Rozhko, Z.B. Popovych, V.D. Kuroiedova et al.: edited by M.M. Rozhko. – Kyiv: AUS Medicine Publishing, 2020. – 792 p.: color edition.
2. Periodontal and Oral Mucosa Diseases: textbook. Vol. 2 / A.V. Borsenko, L.V. Lynovytska, O.F. Nesyn et al.; edited by A.V. Borysenko. - Kyiv: AUS Medicine Publishing, 2018. – 624 p.; color edition.
3. Stomatology: textbook: in 2 books. Book 2 / M.M. Rozhko, I.I. Kyrylenko, O. H. Denysenko et al.; edited by M. M. Rozhko. – Kyiv: AUS Medicine Publishing, 2018. – 960 p.; color edition.

### Additional literature

1. Esthetic Dentistry: A Clinical Approach to Techniques and Materials 3rd Edition by Kenneth W. Aschheim. Publisher: Mosby; 3rd edition, 2014. – 600 p.
2. Esthetic and Restorative Dentistry: Material Selection and Technique 3rd Edition by Douglas A Terry, Willi Geller. Publisher: Quintessence Publishing Co Inc.; 3rd edition, 2017. – 776 p.
3. Dental Composite Materials for Direct Restorations Softcover reprint of the original 1st ed. by Vesna Miletic. Publisher: Springer; 1st edition, 2018. – 327 p.

4. Posterior Direct Restorations 1st Edition by Salvatore Scolavino, Gaetano Paolone. Publisher: Quintessence Pub Co; 1st edition, 2021. – 264 p.
5. Smile Design Integrating Esthetics and Function Essentials of Esthetic Dentistry Volume Two by Jonathan B. Levine. Elsevier Health Sciences, 2015. – 240 p.
6. Cohen's Pathways of the Pulp 12th Edition by Louis H. Berman, Kenneth M. Hargreaves. Publisher: Elsevier; 12th edition, 2020. –992 p.

## Lesson №10

**TOPIC: Non-carious lesions of the teeth occurring after eruption. Pathomorphology, clinic, diagnosis and treatment of enamel erosion, wedge-shaped defects. Traumatic and chemical damage. Hyperesthesia of the hard tissues of the teeth. Elimination of hyperesthesia with the help of modern desensitizers: composition, properties, methods of use**

**I. Topic relevance:** Treatment of non-carious lesions has been ineffective in most cases to date and has usually consisted of filling severe defects and prescribing medications to eliminate hyperesthesia. In recent years, a number of studies have been conducted that reveal the etiology and pathogenesis of various non-carious lesions, which has allowed the introduction of a number of pathogenetically targeted treatments into the clinic. Therefore, the study of this pathology is undoubtedly relevant and is of great importance in the process of forming the clinical thinking of future dentists.

### **II. Study goal:**

#### ***2.1. Student has to know:***

- To know the pathomorphology of non-carious lesions of the teeth that occur after the eruption of teeth;
- To know the classification of non-carious lesions that occur after the eruption of teeth;
- Know the clinic of diseases of non-carious origin;
- To know the diagnosis of non-carious lesions that develop after teething;
- To know what traumatic and chemical lesions of the teeth exist.

#### ***2.2 Be able to:***

- To be able to diagnose non-carious lesions of the hard tissues of the teeth that occur after the eruption of teeth;
- To be able to make a preliminary diagnosis based on the clinic and the course of the disease;
- To be able to diagnose non-carious lesions of the hard tissues of the teeth that occur after the eruption of teeth;
- Be able to choose the treatment for a particular non-carious disease.

### **III. Content of the topic**

**Symptoms of tooth enamel erosion can vary. They often include:**

- increased sensitivity to taste, textures, and temperature
- cracks and chips
- discoloration

- indentations known as cups on the surface of your teeth

**Patient may have significant enamel erosion if they experience:**

- pain
- high sensitivity when exposed to cold, hot, acidic, and spicy food and drink
- discoloration in teeth

**Over time, enamel erosion can lead to complications, such as:**

- yellow, stained teeth
- overly sensitive teeth
- rough edges on teeth
- shiny spots on teeth
- increased tooth decay
- gradual wearing of enamel, leading to clear, slightly translucent teeth
- fractured teeth

### **Causes of enamel erosion**

One of the main causes of enamel erosion are acids found in the foods and liquids patient consumes. Saliva constantly neutralizes acid in a mouth to protect teeth.

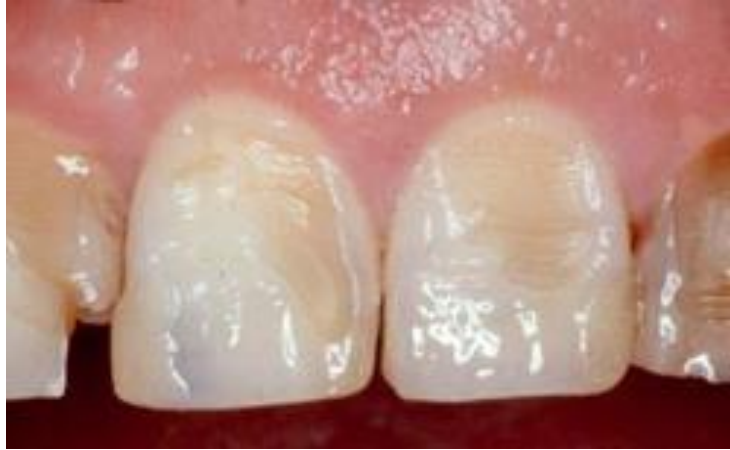**Enamel erosion can be caused by what patients eat, particularly:**

- sugary foods, such as ice cream, syrups, and caramel
- starchy foods, such as white breads
- acidic foods, such as apples, citrus fruits, berries, and rhubarb
- fruit drinks and juices
- sodas, which typically contain damaging citric acid and phosphoric acid in addition to sugar
- excess vitamin C, found in citrus fruits

**Other causes of enamel erosion include:**

- teeth grinding
- chronic acid reflux, also known as gastroesophageal reflux disease (GERD)
- low salivary flow, also known as xerostomia, which is a symptom of conditions like diabetes
- regular use of certain medications, such as antihistamines and aspirin
- eating disorders like bulimia, which disrupts the digestive system and exposes teeth to stomach acid
- genetic disorders, including amelogenesis imperfecta or enamel hypoplasia, that affect tooth development



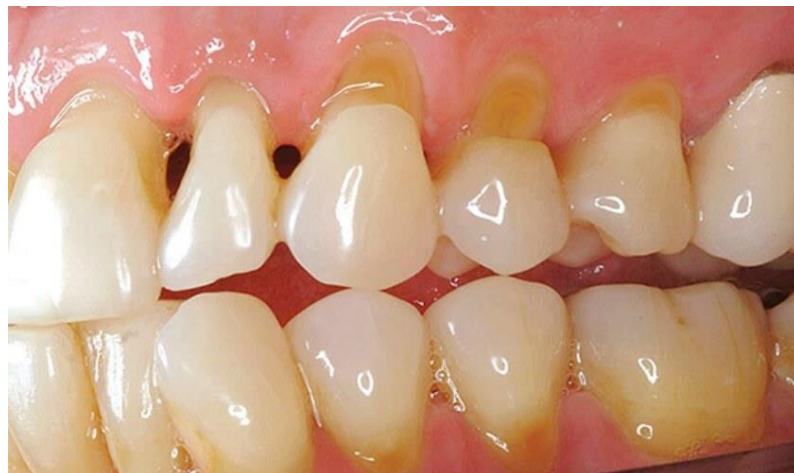

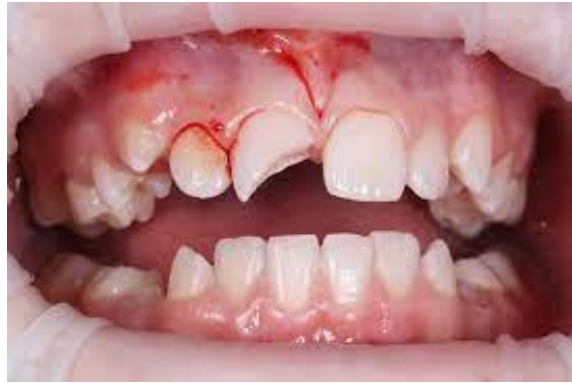**Wedge-shaped defects** - a type of damage to dental tissues located near the walls of the teeth, on the cheek and lip surfaces. The defect is wedge-shaped with the base to the neck of the tooth and the tip to the cutting edge or chewing surface. Wedge-shaped defect, as a rule, does not bother the patient: pain is rare (only briefly from thermal and chemical stimuli), the tooth cavity is not affected and does not open, the defects slowly deepen, softening is not defined (this defect is different from caries) .

The causes of the wedge-shaped defect are not fully established. There is a view that it occurs under the influence of uneven load on the teeth, due to malocclusion.

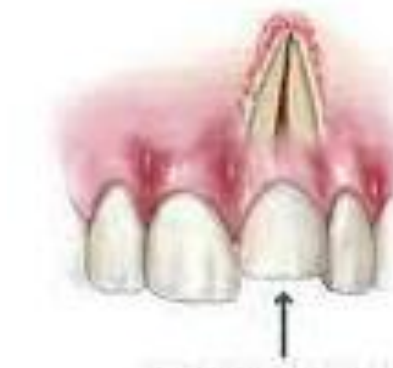
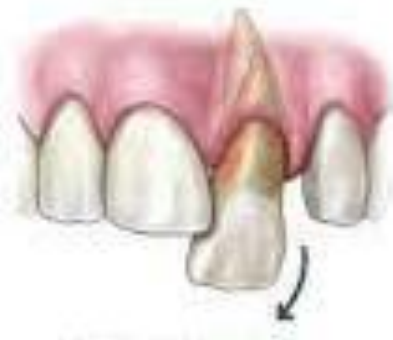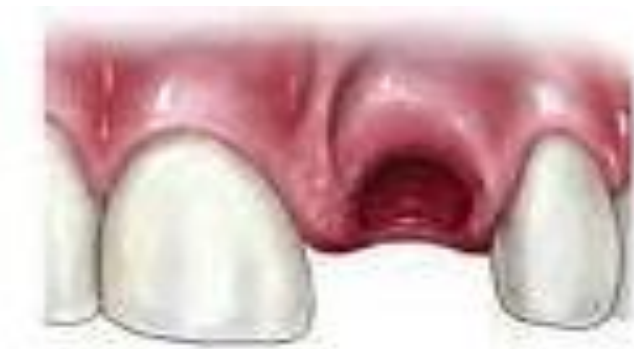It is sometimes believed that because the wedge-shaped defect begins after the exposure of the tooth wall, it is one of the manifestations of periodontal disease. There is evidence of the role of endocrine disorders, diseases of the central nervous system and gastrointestinal tract in the occurrence of a wedge-shaped defect.

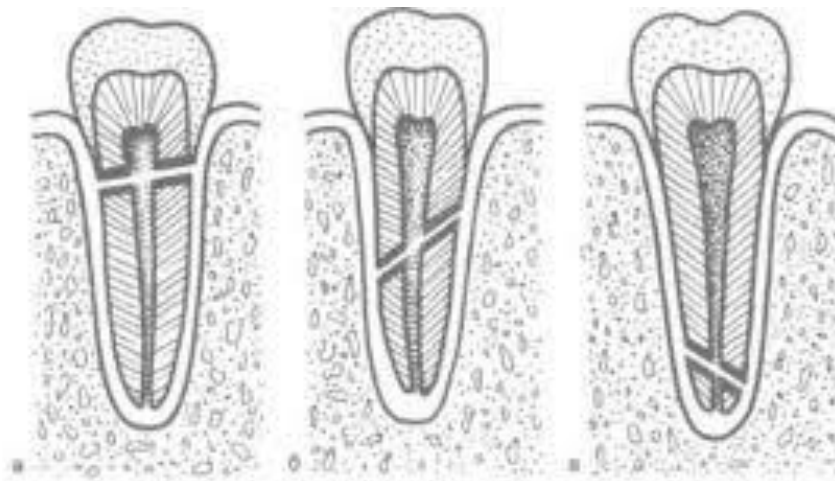
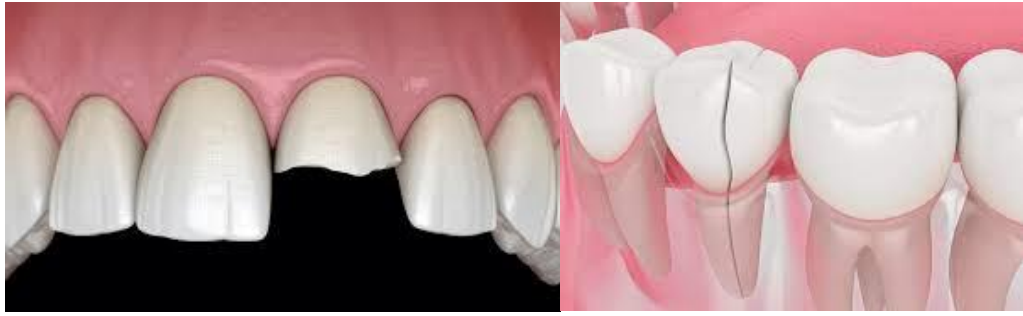Treatment of wedge-shaped defect is aimed at strengthening the hard tissues of the teeth through the use of remineralizing therapy (application of calcium, phosphorus, fluoride, fluoride varnish, fluorogel, etc.).





Dental trauma refers to trauma (injury) to the teeth and/or periodontium (gums, periodontal ligament, alveolar bone), and nearby soft tissues such as the lips, tongue, etc. The study of dental trauma is called dental traumatology.





## Dental injuries

Dental injuries include:

- Enamel infraction
- Enamel fracture
- Enamel-dentine fracture
- Enamel-dentine fracture involving pulp exposure
- Root fracture of tooth

### IV. Control questions for the class topic:

1. What non-carious tooth lesions that occur after eruption do you know?
2. What is the pathomorphology of a wedge-shaped defect?
3. What is the clinic and diagnosis of wedge-shaped defects in patients?
4. What is the pathomorphology of tooth erosion?
5. What is the clinic and diagnosis of tooth erosion?
6. What is the differential diagnosis of a wedge-shaped defect and erosion of hard tooth tissues?
7. What is hyperesthesia?
8. What are the traumatic and chemical lesions of the teeth you know?
9. What is the current treatment of hyperesthesia?

### V. Control test tasks and/or case tasks:

1. Clinical picture of a wedge-shaped defect:

- A) a wedge-shaped defect near the necks of the teeth on the buccal and labial surfaces;
- B) hard tissue defect with signs of demineralisation, rough bottom and walls;
- C) oval or rounded enamel defect on the most convex part of the vestibular surface of the crown;
- D) loss of enamel gloss, formation of chalk-like spots with subsequent defect formation;
- E) white or yellowish spots on the entire surface of the enamel

**The correct answer is: A.**

2. A 44-year-old patient complains of a cosmetic defect of 12, 11, 21, 22 teeth, pain from temperature stimuli. From the survey it was found that the patient consumes a large amount of citrus fruits and their juices. He noticed the first signs of defects about 5 years ago. On examination, in the cervical region of the vestibular surface of the teeth, the enamel defects are oval saucer-shaped. The bottom is smooth, shiny, hard. Short-term pain on cold water. What is the most likely diagnosis?

- A. Enamel erosion
- B. Enamel hypoplasia
- C. Superficial caries
- D. Enamel necrosis
- E. Wedge-shaped defect

**The correct answer is: A.**

3. A 35-year-old patient complained of a feeling of ossification, sticking together of the teeth when closing, sensitivity of the anterior teeth to thermal and mechanical stimuli. Objectively: change in the appearance of enamel 13, 12, 11, 21, 22, 23. The enamel is matte, rough, with no pitting on the cutting edges. Probing of the vestibular surface of these teeth is painful, the thermal test is positive. From the anamnesis it was established that the patient works in the production of inorganic acids. Indicate the most likely diagnosis:

- A. Necrosis of the hard tissues of the tooth
- B. Pathological abrasion of teeth
- C. Enamel hypoplasia
- D. Fluorosis
- E. Enamel erosion

**The correct answer is: A.**

4. A 52-year-old patient complains of cosmetic dental defects that she noticed several years ago. Objectively: on the vestibular surfaces in the cervical region of premolars and incisors there are slit-like defects within the dentin cloak, formed by smooth, shiny surfaces. The necks of the teeth are exposed, the gums are dense, pale pink in colour. Probing of the defects is painless. Establish the diagnosis:

- A. Wedge-shaped defect

- B. Erosion of hard tooth tissues
- C. Necrosis of hard tooth tissues
- D. Chronic medium caries
- E. Acute medium caries

**The correct answer is: A.**

5. A 63-year-old patient came to the dentist with complaints of bruising while brushing his teeth and eating sour food (lemon). For the last 10 years, he has been observed by a periodontist for periodontal disease. Objectively: at 15, 14, 13, 23, 24, 25, 35, 34, 33, 43, 44, 45, on the vestibular surfaces near the necks of the teeth, cavities with smooth surfaces forming an angle. Probing the bottom is painful. What is the most likely diagnosis?

- A. Acute medium caries
- B. Wedge-shaped defect
- C. Chronic deep caries
- D. Chronic medium caries
- E. Enamel hypoplasia

**The correct answer is: B.**

## LIST OF REFERENCES

### Main literature

1. Stomatology: textbook: in 2 books. Book I / M.M. Rozhko, Z.B. Popovych, V.D. Kuroiedova et al.: edited by M.M. Rozhko. – Kyiv: AUS Medicine Publishing, 2020. – 792 p.: color edition.
2. Periodontal and Oral Mucosa Diseases: textbook. Vol. 2 / A.V. Borsenko, L.V. Lynovytska, O.F. Nesyn et al.; edited by A.V. Borysenko. - Kyiv: AUS Medicine Publishing, 2018. – 624 p.; color edition.
3. Stomatology: textbook: in 2 books. Book 2 / M.M. Rozhko, I.I. Kyrylenko, O. H. Denysenko et al.; edited by M. M. Rozhko. – Kyiv: AUS Medicine Publishing, 2018. – 960 p.; color edition.

### Additional literature

1. Esthetic Dentistry: A Clinical Approach to Techniques and Materials 3rd Edition by Kenneth W. Aschheim. Publisher: Mosby; 3rd edition, 2014. – 600 p.
2. Esthetic and Restorative Dentistry: Material Selection and Technique 3rd Edition by Douglas A Terry, Willi Geller. Publisher: Quintessence Publishing Co Inc.; 3rd edition, 2017. – 776 p.
3. Dental Composite Materials for Direct Restorations Softcover reprint of the original 1st ed. by Vesna Miletic. Publisher: Springer; 1st edition, 2018. – 327 p.

4. Posterior Direct Restorations 1st Edition by Salvatore Scolavino, Gaetano Paolone. Publisher: Quintessence Pub Co; 1st edition, 2021. – 264 p.
5. Smile Design Integrating Esthetics and Function Essentials of Esthetic Dentistry Volume Two by Jonathan B. Levine. Elsevier Health Sciences, 2015. – 240 p.
6. Cohen's Pathways of the Pulp 12th Edition by Louis H. Berman, Kenneth M. Hargreaves. Publisher: Elsevier; 12th edition, 2020. –992 p.

## Lesson № 11

### **TOPIC: Errors and complications in the diagnosis and treatment of caries. Secondary caries of depulped and non-depulped teeth: cause, clinic, diagnosis, differential diagnosis. Treatment and prevention.**

**I. Topic relevance:** During the treatment of dental caries, the dentist performs a number of different manipulations, which can lead to complications if not performed carefully or incorrectly. These mistakes can occur both during the actual surgical treatment, preparation and filling of the carious cavity, and at different times after the filling. Therefore, it is advisable to divide them into complications that occur during the preparation and filling of a carious cavity and complications that occur after caries treatment.

#### **II. Study goal:**

##### **2.1. Student has to know:**

- Know the mistakes in the diagnosis and treatment of caries;
- Know the complications in the diagnosis and treatment of caries;
- Know what secondary caries is and its course;
- To know the clinic of secondary caries of depulped and non-depulped teeth;
- Know the treatment and prevention of secondary caries.

##### **2.2 Be able to:**

- Be able to identify errors in the diagnosis and treatment of caries;
- Be able to identify complications during the diagnosis and treatment of caries;
- Be able to identify and classify secondary caries in a patient;
- To be able to choose the treatment of secondary caries of depulped and non-depulped teeth.

#### **III. Content of the topic**

During treatment of dental caries, doctor performs a variety of manipulations, not very thorough or improper performance of which can lead to some kind of complications. These errors can occur both during the actual surgical treatment, preparation of carious cavities and on the stages of carious cavity filling and at a different times after sealing. It is therefore advisable to divide them into complications arising during the preparation of carious cavities and during filling of carious cavity, and the complications that arise after treatment of caries.

**Errors and complications arising during carious cavity preparation are:**

1. Insufficient carious cavity preparation may lead to secondary caries, thus progressing of caries process and possible development of pulpitis or filling loss.
2. Perforation of the carious cavity bottom or carious cavity wall and fracture of the carious cavity wall may happen due to not proper fixed hand of clinical thus leading to such complications. Perforation of carious cavity floor may happen in the case of acute deep dental caries, when bottom is softened and thin layer of demineralised dentine separates carious cavity from tooth cavity.
3. Injury of adjacent tooth crown by bur may happen when visible control of operative field is not provided.
4. Injury of gingival margin by bur may happen during preparation of carious cavities that goes deep under the gums or good vision of operative field was not provided.

**Errors and complications arising during carious cavity filing are:**

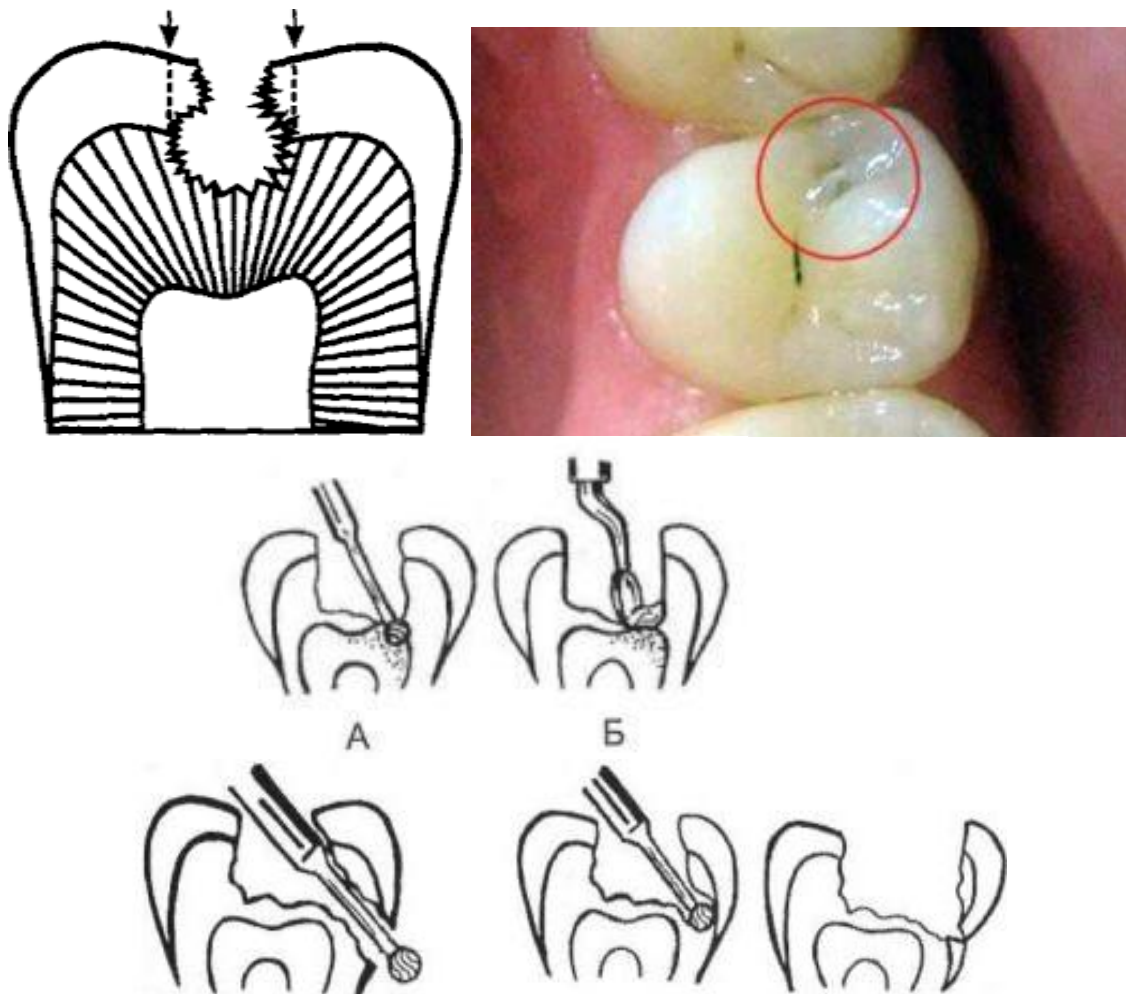
1. Absence of a contact point, hanging edges of a filling and placement of a single filling in adjacent carious cavities will lead to inflammation papilla, thus causing pain to the patient and development of periodontal diseases. That is why during restoration of proximal cavities it is necessary to use matrix holder and matrices in order to restore contact point, thus preventing these complications.
2. Formation of high occlusion usually happen when filling is not adjusted to the bite , when high spots are left, this will lead to development of apical periodontitis in future, such tooth will change its color to grey shades and will be painful while biting.

Errors and complications arising after dental caries treatment are:

1. Inflammation or necrosis of the pulp.
2. Inflammation of an intradental papila or papilitis.
3. Acute or chronic course of an apical periodontitis.
4. Color change of the tooth crown.
5. Displacement, fracture and loss of filling.
6. Inadequate color of filling to the color of tooth anamel.

The main task of therapeutic dentistry is to prevent dental caries and its complications – pulpitis, periodontitis, papilitis. Knowledge of possible mistakes and errors during carious cavity preparation and filling material placement will prevent young clinician from the complications arising as the result of mistakes.





#### IV. Control questions for the class topic:

1. What mistakes do you know when diagnosing caries?
2. What mistakes do you know in the treatment of caries?
3. What complications in the diagnosis of caries do you know?
4. What complications in the treatment of caries do you know?
5. Secondary caries. Causes, clinic, diagnosis.
6. Treatment of secondary caries.
7. What role does prevention play in the spread of caries?
8. What types of caries prevention do you know?

#### V. Control test tasks and/or case tasks:

1. The patient complained of a constant aching pain in the tooth, which worsens when biting. 3 days ago, the tooth was filled due to deep caries. Objectively: at 16, there is a filling on the chewing surface, vertical percussion is painful. The dentition does not close in the bite. The mucous membrane in the area of the projection of the apex of the root of 16 is unchanged; thermodiagnosics is painless, EOD - 6  $\mu$ A. On the radiograph: periodontal tissues are unchanged. What is the doctor's tactic?

- A. Correction of the filling
- B. Prescribe antiseptic rinses
- C. Prescribe physical therapy
- D. Removal of the filling
- E. Providing anaesthesia

**The correct answer is: A.**

2. In a 24-year-old patient, during the treatment of medium caries 35 (Black's class V), the tooth cavity was accidentally opened. What should be the doctor's tactics?

- A. Apply odontotropic paste
- B. Perform a vital pulp amputation
- C. Devitalise the pulp with a devitalising extraction
- D. Perform a vital pulp extraction
- E. Apply mummifying paste

**The correct answer is: A.**

3. A 47-year-old patient complains of a carious cavity near the filling in the 44th tooth. From the medical history it was found that the tooth was previously treated, the filling was placed 6 months ago, the defect near the filling appeared several months ago. On examination, a filling was found on the apical-medial surface of tooth 44 with a marginal abutment. After the filling was removed, a carious cavity was observed within the near-pulpal dentin, filled with pigmented dense dentin. Probing, percussion and palpation are painless, the EDP is 12  $\mu$ A. What is the most likely diagnosis?

- A. Pulp hyperaemia 44
- B. Secondary chronic deep caries 44
- C. Acute deep caries 44
- D. Chronic medium caries 44
- E. Chronic fibrous pulpitis 44

**The correct answer is: B.**

4. When examining a tooth with secondary caries of a depulped tooth, one can observe:

- A. a large filling, along the perimeter of which there is a change in the colour of the hard tissues of the tooth, the tooth is discoloured;
- B. a filling that does not match the colour of the tooth, the adhesion of the filling to the tooth tissues is not disturbed;
- C. a carious cavity with a wide entrance hole within the pulp dentin;
- D. a carious cavity with a wide entrance hole within the dentin cloak;
- E. a carious cavity with a wide entrance opening within the peri pulp dentin that communicates with the tooth cavity.

**The correct answer is: A.**

5. Causes of secondary caries:

- A. incomplete removal of necrotic dentin from the bottom of the carious cavity;

- B. drug treatment with potent antiseptic solutions;
- C. compliance with the principles of preparation;
- D. penetration of microflora into the microspace between the filling and the tooth tissue;
- E. compliance with the filling technology.

**The correct answer is: A, D.**

## LIST OF REFERENCES

### Main literature

1. Stomatology: textbook: in 2 books. Book I / M.M. Rozhko, Z.B. Popovych, V.D. Kuroiedova et al.: edited by M.M. Rozhko. – Kyiv: AUS Medicine Publishing, 2020. – 792 p.: color edition.
2. Periodontal and Oral Mucosa Diseases: textbook. Vol. 2 / A.V. Borsenko, L.V. Lynovytska, O.F. Nesyn et al.; edited by A.V. Borysenko. - Kyiv: AUS Medicine Publishing, 2018. – 624 p.; color edition.
3. Stomatology: textbook: in 2 books. Book 2 / M.M. Rozhko, I.I. Kyrylenko, O. H. Denysenko et al.; edited by M. M. Rozhko. – Kyiv: AUS Medicine Publishing, 2018. – 960 p.; color edition.

### Additional literature

1. Esthetic Dentistry: A Clinical Approach to Techniques and Materials 3rd Edition by Kenneth W. Aschheim. Publisher: Mosby; 3rd edition, 2014. – 600 p.
2. Esthetic and Restorative Dentistry: Material Selection and Technique 3rd Edition by Douglas A Terry, Willi Geller. Publisher: Quintessence Publishing Co Inc.; 3rd edition, 2017. – 776 p.
3. Dental Composite Materials for Direct Restorations Softcover reprint of the original 1st ed. by Vesna Miletic. Publisher: Springer; 1st edition, 2018. – 327 p.
4. Posterior Direct Restorations 1st Edition by Salvatore Scolavino, Gaetano Paolone. Publisher: Quintessence Pub Co; 1st edition, 2021. – 264 p.
5. Smile Design Integrating Esthetics and Function Essentials of Esthetic Dentistry Volume Two by Jonathan B. Levine. Elsevier Health Sciences, 2015. – 240 p.
6. Cohen's Pathways of the Pulp 12th Edition by Louis H. Berman, Kenneth M. Hargreaves. Publisher: Elsevier; 12th edition, 2020. –992 p.

## Lesson №12

### TOPIC: Writing an extended card for an outpatient with various forms of caries and non-cariou lesions.

**I. Topic relevance:** Writing an extended card of a dental patient allows the student to summarise the material studied and use their theoretical knowledge in practice when examining a patient and filling out an outpatient card of a dental patient in a therapeutic dentistry clinic. This will enable the future specialist to clearly and accurately keep medical records, correctly formulate a diagnosis based on the knowledge of the clinic, diagnosis and differential diagnosis of various forms of caries and non-cariou lesions.

#### **II. Study goal:**

##### **2.1. Student has to know:**

- Know the scheme of examination of a dental patient;
- To know the sequence of collecting complaints in case of dental caries and non-cariou lesions of hard tissues, life history and disease;
- Know the features of objective examination of a patient with caries (basic and additional methods of examination);
- Know the features of treatment of a patient diagnosed with caries and non-cariou lesions (including the clinical course of the disease).

##### **2.2 Be able to:**

- Be able to consistently describe the subjective examination of the patient;
- Be able to describe the objective examination of the patient;;
- Be able to describe step by step the treatment of a patient with a specific diagnosis
- Be able to choose the treatment of secondary caries of depulped and

#### **III. Content of the topic**

##### **Instructions**

**for filling in the form of primary accounting documentation No. 043/o "Medical record of a dental patient"**

1. This Instruction defines the procedure for filling out the primary record form No. 043/o "Medical record of a dental patient" (hereinafter referred to as form No. 043/o).

2. Form No. 043/o is filled in by responsible persons of outpatient health care institutions that provide dental care to the population: dental clinics, dental departments and offices of outpatient clinics, polyclinics, hospitals, dispensaries, research institutes, higher education institutions of III-IV accreditation levels, hospitals for disabled veterans, women's clinics, health care facilities regardless of subordination and form of ownership.

3. The patient's passport data (surname, name, patronymic, gender, place of residence, year of birth) is filled in by a nurse or registrar.

4. The diagnosis and other sections of form No 043/o are filled in directly by the attending physician. Depending on the complaints and the initial clinical

diagnosis, the doctor must refer the patient for laboratory tests, X-rays, and the conclusions of specialists of the relevant profile, including general somatic ones, with the submission of an extract from the dental patient's card, tests and other medical documentation. The said documentation shall be entered or pasted into the form No. 043/o in the section "Data of X-ray examinations, laboratory tests".

4.1 Further clarification of the diagnosis, expansion or even replacement is allowed with the obligatory indication of the date. The diagnosis should be detailed, only dental diseases should be described.

5. In line 6, "Complaints", the patient or relatives should write down the complaints that most accurately reflect the patient's condition in relation to the dental disease. 6. In line 7 "Past and concomitant diseases", data on past and concomitant diseases shall be indicated according to the patient's words, as well as data confirmed by

by specialists from other departments of the healthcare facility. It is necessary to indicate whether the patient is registered with a dispensary and for what disease.

7. In line 8 "Development of the current disease" indicate: the time of the first symptoms of the disease, what the patient associates them with, the nature of the disease and previous treatment and its effectiveness.

8. In line 9 "Objective examination data, external examination, dental condition", the external examination data is described, indicating the condition of the skin, bone skeleton of the face, red lip border, etc. This line indicates the results of palpation of the temporomandibular joint, submandibular, parotid salivary glands. Recording of oral cavity examination data begins with determination of the condition of the hard tissues of the teeth and periodontal tissue. The first row above and below the teeth arranged schematically is reserved for entering data on the condition of the crown part of the tooth with conventional designations, including the presence of various denture designs.

8.1. The numerator indicates the state at the time of the examination, the denominator - the state after treatment. Above and below the second row of schematically depicted teeth, the data of the objective examination of the periodontal state, its norm (N), the degree of atrophy - 1/4, 1/2, 3/4 and the degree of tooth mobility - I, II, III are entered.

8.2. Under the table of schematically arranged teeth, additional data on the teeth, bone tissues of the alveolar processes (changes in their shape, position, etc.) are reflected in writing.

9. In line 10 "Occlusion", the type of relationship of the dentition in the normal, abnormal, pathological state, as well as the nature of the relationship of the alveolar processes of the jaws in the absence of antagonistic teeth or their complete absence, focusing on their relationship in a state of relative rest, is noted.

10. In line 11, "State of oral hygiene, condition of the oral mucosa, gums, alveolar processes and palate. GI and PMA indices" describes the state of the oral mucosa according to visual examination, hygiene index (hereinafter referred to as GI) and papillary marginal alveolar index (hereinafter referred to as PMA), which is an

indicator for assessing the manifestations of gingivitis and periodontal index (PI), aimed at detecting advanced forms of pathology.

11. In line 12 "Data of X-ray examinations, laboratory tests", the conclusions of X-ray examinations and laboratory tests should be indicated.

12. In line 13 "Colour according to the Vita scale" indicate the correspondence of the colour range of the applied material to the colour of the patient's dental crowns.

13. In line 14 "Date of training in oral hygiene skills", indicate the date when a conversation was held on proper toothbrushing and other oral hygiene skills.

14. In line 15, "Date of oral hygiene control", enter the date after the assessment of the hygienic state of the oral cavity.

15. Section 16, "Doctor's diary," indicates all cases of patient visits to the doctor, draws up an examination plan, a patient treatment plan with notes on the consultative opinions of related specialists. It is completed with an epicrisis, a brief description of the results of treatment and practical measures recommended by the doctor. After the treatment, the doctor who performed the treatment and the head of the department sign the epicrisis, and after the completion of certain stages of treatment, the doctor who directly treats the patient signs it.

16. In a dental polyclinic, department or office, there shall be one form No. 043/o per patient.

17. Form No. 043/o is signed and dated by the physician who is in charge of the patient's dispensary supervision.

18. If Form No 043/o is kept in electronic format, it must include all the information contained in the approved paper form.

19. Form No 043/o shall be kept in the registry of the health care facility. 20. The storage period of Form No 043/o is 5 years.

#### **IV. Control questions for the class topic:**

1. What is the scheme of examination of a dental patient?
2. What is the sequence of collecting complaints in dental caries?
3. What is the sequence of collecting complaints in non-carious dental lesions?
4. What features of the objective examination of the patient do you know?
5. What features of the subjective examination of the patient do you know?
6. Do you know the mistakes in the treatment of caries?

#### **V. Control test tasks and/or case tasks:**

1. During the subjective examination of a patient, the following are performed:

- A. questioning;
- B. examination of the patient;
- C. examination of the tooth and surrounding tissues;
- D. external examination of the patient, questioning;
- E. external examination, examination of the patient, questioning.

**The correct answer is: A.**

2. Subjective methods of patient examination include:

- A. external examination, finding out passport data, medical history,

life history;

B. ascertainment of passport data, life history, medical history, examination of examination of the tooth;

C. clarification of passport data, complaints, medical history, dental examination;

D. clarification of complaints, conducting basic and additional examination methods;

E. clarification of passport data, complaints, medical history, life history.

**The correct answer is: E.**

3. Pain in which the patient clearly indicates the causative tooth is called:

A. localised;

B. causal;

C. acute;

D. irradiating;

E. short-lived.

**The correct answer is: B.**

4. Pain that occurs from the action of mechanical stimuli is called:

A. causal;

B. involuntary;

C. aching;

D. short-term;

E. dull.

**The correct answer is: D.**

5. Causes of secondary caries:

A. incomplete removal of necrotic dentin from the bottom of the carious cavity;

B. drug treatment with potent antiseptic solutions;

C. compliance with the principles of preparation;

D. penetration of microflora into the microspace between the filling and the tooth tissue;

E. compliance with the filling technology.

**The correct answer is: A, D.**

## LIST OF REFERENCES

### Main literature

1. Stomatology: textbook: in 2 books. Book I / M.M. Rozhko, Z.B. Popovych, V.D. Kuroiedova et al.: edited by M.M. Rozhko. – Kyiv: AUS Medicine Publishing, 2020. – 792 p.: color edition.

2. Periodontal and Oral Mucosa Diseases: textbook. Vol. 2 / A.V. Borsenko, L.V. Lynovytska, O.F. Nesyn et al.; edited by A.V. Borysenko. - Kyiv: AUS Medicine Publishing, 2018. – 624 p.; color edition.

3. Stomatology: textbook: in 2 books. Book 2 / M.M. Rozhko, I.I. Kyrylenko, O. H. Denysenko et al.; edited by M. M. Rozhko. – Kyiv: AUS Medicine Publishing, 2018. – 960 p.; color edition.

### **Additional literature**

1. Esthetic Dentistry: A Clinical Approach to Techniques and Materials 3rd Edition by Kenneth W. Aschheim. Publisher: Mosby; 3rd edition, 2014. – 600 p.
2. Esthetic and Restorative Dentistry: Material Selection and Technique 3rd Edition by Douglas A Terry, Willi Geller. Publisher: Quintessence Publishing Co Inc.; 3rd edition, 2017. – 776 p.
3. Dental Composite Materials for Direct Restorations Softcover reprint of the original 1st ed. by Vesna Miletic. Publisher: Springer; 1st edition, 2018. – 327 p.
4. Posterior Direct Restorations 1st Edition by Salvatore Scolavino, Gaetano Paolone. Publisher: Quintessence Pub Co; 1st edition, 2021. – 264 p.
5. Smile Design Integrating Esthetics and Function Essentials of Esthetic Dentistry Volume Two by Jonathan B. Levine. Elsevier Health Sciences, 2015. – 240 p.
6. Cohen's Pathways of the Pulp 12th Edition by Louis H. Berman, Kenneth M. Hargreaves. Publisher: Elsevier; 12th edition, 2020. –992 p.