

© V.L. Denisenko, Yu.M. Gain, 2014

УДК [616.351+616.345]:616-006:[616-006.[616-089:615:849.19]

V.L. DENISENKO¹, Yu.M. GAIN²

¹*Establishment of public health «Second Vitebsk regional clinical hospital»;* ²*State establishment of education «Belarus medical academy of postgraduate education», Vitebsk, Belarus*

TUMOUR LASER RECANILIZATION APPLICATION IN COMPLEX SURGICAL TREATMENT OF OBSTRUCTING COLORECTAL CANCER

Authors develop and use in clinical practice a technique laser recanalization of colon tumors, allowing in the conditions of intestinal obstruction to execute early antegrade decompression of digestive tracts with its fast restoration of motive-evacuation functions and early clinical-metabolic compensation (without laparotomy and formations of intestinal fistula). The offered approach allows to carry out preparation of the patient for radical intervention in the limited terms, not writing out it from a hospital, promotes increase of reliability of surgical treatment and efficiency of one-stage restoration of digestive tracts continuity. Early endoscopic decompression of intestines as the first stage of realization of the concept «Fast-Track Recovery», in a combination to the complex program of medicinal correction of infringements of a homeostasis and intraparietal intestinal haemocirculation, allow to eliminate in deadlines morphological-and-functional infringements from resulting departments of intestines and to execute radical surgical treatment of colorectal cancer by principles of planned intervention in the absence of problems with resulting department of intestines and possibility of reliable one-stage restoration of digestive tracts continuity.

Key words: laser vaporization, colorectal cancer, tumour recanalization

The urgency of the problem. In the structure of oncological pathology in most of the developed countries of the world colorectal cancer takes the third place, the number of patients with advanced forms of the disease making 70% even at present [1]. While the highest mortality is registered in the countries of western Europe (34,3 per 100 000 people) and the lowest one in the USA (15,2) [1]. The morality is increasing with age, reaching the maximum at the age of 70 and over. Within the past 11 years (from 1990 to 2011) in the Republic of Belarus the number of patients with this localization cancer diagnosed for the first time has increased from 12,9 to 19,5 persons per 100 thousand of population [2].

70% patients are delivered to the in-patient department in emergency (while in the absolute majority of cases the developed complications have become the initial manifestation of the disease). The most common complication of colorectal cancer is intestinal obturation obstruction. It develops in 26,4-69% patients [3]. This complication is the most typical to left colon tumours (67-72%), which is related to the peculiarities of the local growth (endophytic, circular), the specific character of intramural lymphatic outflow, as well as the higher density of this localization tumour and smaller bowel diameter [3]. Most of the patients are hospitalized when having concomitant cardiovascular or respiratory pathology [4]. Over a hundred thousand people die of colorectal cancer annually. According to the official data in the Republic of Belarus the total colon cancer mortality in 2009 was 2 173 people or 22,9 per 100 thousand of population (1628 or 23,1 per 100 thousand of urban population, 545 or 22,2 per 100 of rural population); in 2011 this localization cancer caused death of 2 278 people or 24,0 per 100 of thousand of population (1 750 or 24,5 per 100 thousand of urban population, 528 or 22,7 per 100

thousand of rural population) [5]. Meanwhile, in most of the economically developed countries of the world over 70 out of a hundred of patients newly diagnosed with colonic and rectal cancer die, of whom about 40% patients die within the first year since the diagnosis was made. This occurrence is due to the fact that on the initial visit to a doctor the advanced forms of cancer (III-IV stages) are diagnosed in 71,4% colonic cancer patients and in 62,4% patients in cases of rectal cancer [6]. The developed countries waste enormous money for the reason that colorectal cancer affects population. For instance, in the USA the cost of complex treatment of patients with this localization cancer takes the second place in expenses for cancer patients treatment, being 6,5 milliard dollars per year [7]. So far surgical approach in intestinal obturation obstruction against the background of colorectal cancer has remained a matter of hot discussion. There are no generally accepted approaches to the choice of surgical manual and operation completion, which requires further scientific search and study of possibility to realize new trends in the solution to the problem.

In surgery and oncology the trend of complex treatment based on “rapid (accelerated) recovery” concept, the so called “Fast-Track Recovery” or “Fast-Track Surgery”, is coming into force. In relation to complicated colorectal cancer “Fast-Track Recovery” concept realization consists in transformation of multistage surgical treatment (Zeidler-Schlofer operations type) into single-stage interventions with previous minimal invasive resolution of intestinal obstruction episodes and primary restoration of the digestive tract continuity without discharging the patient from the in-patient department. The given approach not only results in rapid recovery with significant decrease in the total treatment and rehabilitation duration, but also leads to considerable decrease in economic expenses

for treatment, has substantial social effect due to more rapid and effective quality of patient's life restoration [8].

One of the components of minimal invasive removal of colon obturation may be tumour recanalization using self-expanding stents. The authors of this article initiated successful application of this technology in complex treatment of obstructing colorectal cancer by "Fast-Track Recovery" method. In addition reasonably high cost of this technique and absence of manufacture of domestic stents limit wide application of the given technology in practical surgery.

One of the methods of stenosis zone recanalization is laser vaporization of the central cancer portion. Various models of high-energy lasers compatible with endoscopic complex are used for effective evaporation and coagulation of digestive tract tumours. The most popular for this have become argon laser (wave length 514 nm), semiconductor laser scalpel (970 nm) and neodymium laser on yttrium-aluminum garnet (Nd: YAG-laser, 1064 nm). Rapid reaching of vaporization threshold under contact method of laser radiation contributes to rapid evaporation of pathologic tissue, which in its turn provides effective cooling and preventing deep burn of colonic tissues [7].

Currently there is lack of methodological information on application of laser radiation in surgical endoscopy. Surgeons use laser installations and pathological tissues photodestruction methods of various in technique and mode. This has adverse effect on the frequency, efficacy and safety of laser radiation application in practice of intraluminal gastrointestinal endoscopy, causes valid uncertainty of most practical endoscopists having no proper conditions for practising optimal techniques in the experiment and in practice [8].

The aim of investigation. To increase the efficacy of complex treatment of obstructing colorectal cancer by developing and introducing tumour laser recanalization technique and accelerated preparation of the digestive tract for radical surgical treatment with primary restoration of digestive tract continuity.

Materials and methods. To fulfill the task of the first stage of "Fast-Track Recovery" concept realization in the treatment of obstructing colorectal cancer complicated with colonic obstruction the authors have used high-intensity impulsive laser radiation with wave length 1,06 mcm and power 20-25 watt. In the work they used solid impulsive laser for endoscopic use "Photek LK-50" ("Mediola-Endo", Private Unitary Enterprise "Photek", the Republic of Belarus) in the structure of endoscopic stand for colon examination (wave length 1,064 mcm, maximal average radiation power – 60 watt, impulses recurrence frequency on the maximal radiation power – no more than 50 Hz, maximal impulse energy – 1,2 joule, impulse duration – 300 msec, laser danger class – IV, maximal consumed power – 2,5 kilowatt).

The prospective clinical investigation with evaluation of treatment outcomes for 35 patients with obstructing colorectal cancer which caused intestinal obstruction development was performed. The age of the patients varied from 54 to 81 (on average $62,4 \pm 7,32$). There were 23 females (65,7%), males being 22 (62,8%). All the patients had evidence of colon obstruction – failure to pass feces and gases within the last 2-4 days, abdominal distension, pneumatosis coli (revealed by percussion and X-ray) with lumen dilatation 2-2,5 times, pneumatosis of small intestine. All the patients were divided into 2 groups (Table 1).

Table 1

Patients distribution by tumour process localization in the basic and control groups

Obstructing tumour localization	Basic group (n=20)	Control group (n=15)
Rectal cancer	6	4
Colonic rectosigmoid cancer	6	5
Sigmoid cancer	4	4
Descending cancer	4	3

In the first (basic) group on admission to the in-patient department (up to 24 hours) all the patients underwent medical and diagnostic recto- and colonoscopy, under which after making the diagnosis of obstructing colonic cancer and biopsy laser vaporization of the internal tumour portion with restoration of the digestive tract lumen in the tumour zone on no less than 0,8-1 cm. Following laser recanalization the patients were given a siphon enema, which resulted in effective antegrade colonic emptying in 100% cases. The patients were administered laxatives and vaseline oil. The treatment

complex included daily infusion therapy (crystalloid and colloid solutions, potassium-polarizing mixture, according to indications – parenteral feeding preparations), Diavetol 15-20 mg/kg (by dry substance), Emoxipine 1,5-2,5 mg/kg, Pentoxifylline 0,2% solution 200-400 ml/daily and Reamberin 400-800 ml/daily (or Cytoflovine 10 ml solution in 100 ml of 0,9% sodium chloride solution) were given intravenously. After 4-6 days without discharging the patient from the in-patient department in the state of clinical and metabolic compensation radical operation with primary restoration of digestive tract

continuity was performed (only in one patient tumor recanalization became ultimate symptomatic operation considering the severity of background pathology with cardiovascular function decompensation). Sigmoid resection, low anterior resection of rectum, left hemicolectomy with primary restoration of digestive tract continuity by circular mechanic suture were performed as radical interventions.

In the second (control) group in failure of conservative measures following preoperational preparation (from 6 to 25 hours) emergency interventions were made: left hemicolectomy with terminal transverse colostomy, Gartman operation type – obstructive sigmoid resection with terminal sigmoidostomy, loop sigmoidostomy, transverse colostomy.

Comparing groups had no reliable differences in sex, age, pathological stage process, stricture formation degree, severity of intestinal obstruction ($p > 0,05$).

In the aspect of comparison postoperative period course peculiarities, evidence of complications were evaluated, investigation of quality of the operated patients before discharge from the in-patient department and a month after intervention by questioning using

questionnaire “SF-36” (The Medical Outcomes Study Short Form 36 Items Health Survey) based on the evaluation of wide range of indices of physical and mental wellbeing, social adaptation and lifestyle characteristics determined by health condition. Quantitative and qualitative indices obtained as a result of the investigation have been analyzed using application statistical programs package «STATISTICA» (Version 6-Index, Stat Soft Inc., USA).

The results of investigation and discussion. Under recto- and colonoscopy during the first stage of “Fast-Track Recovery” concept realization in the first group patients under endoscopic study colonic and rectal luminal narrowing were found to vary from 5 to 8 mm (the average diameter in the stenosis zone was $7,32 \pm 2,11$ mm). While stenosis zone extent ranged from 5 to 100 mm (on the average $7,12 \pm 1,97$ mm) (Figure 1). Under laser vaporization of the obstructing tumour portion by means of laser apparatus “Photek LK-50” (“Mediola-Endo”) pulse sequence of energy generation was used (wave length 1,064 mcm, power – 20-25 watt, impulses occurrence frequency at maximal radiation power – up to 50 Hz, maximal umpulse energy – 1,2 joule, impulse duration – 300 msec).

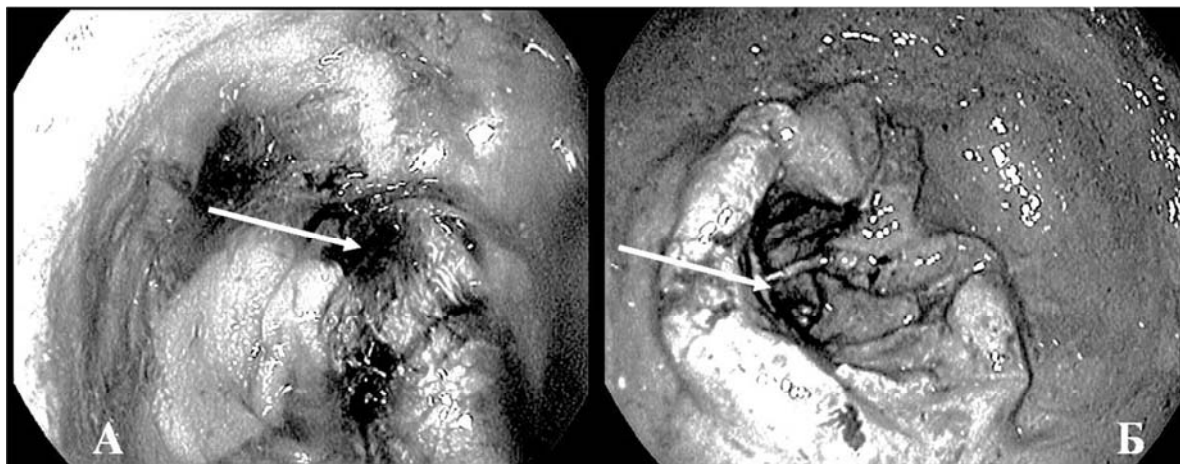


Figure 1. Descending colon obstructing cancer with lumen diameter in the stenosis zone 5 mm (A) and rectal obstructing cancer with lumen diameter in the stenosis zone up to 6mm (B). Colonoscopy findings. The stenosis zone is marked with arrows.

On practising vaporization mode the most effective distance from the quartz optical fiber end to radiated tissue was found to be 3-5 mm. While the treatment of protruding tumour portion was performed in scanning regimen along the perimeter of obstructing cancer tissue. Optical fiber end contact with tissue resulted in the burning of optical fiber with further decrease in vaporization efficacy.

Laser recanalization procedure lasted from 25 to 65 minutes (on the average $40,0 \pm 11,4$ min.). Smoke generation and excessive motor activity of the patient had adverse effect on the procedure duration (which required additional drug sedation in one case). Laser vaporization of the inner tumour portion was performed until digestive tube lumen

restoration in the tumour zone was no less than 0,8-1 cm. In five cases (25%) repeated laser vaporization of tumour tissue was required to reach the target recanalization. Even with incomplete restoration of colonic lumen in the tumour zone just within the first twenty four hours after the manipulation the patients had abuse passage of gases, 40% had unassisted stool. After twenty four hours all the patients had no clinical and roentgenological evidence of colonic obstruction. The maximal effect of recanalization was observed after 3-4 days following laser procedure (Figure 2), which was due to gradual rejection of necrotic tissues into the bowel lumen. There were no haemorrhages related to devitalized cancer tissues rejection.

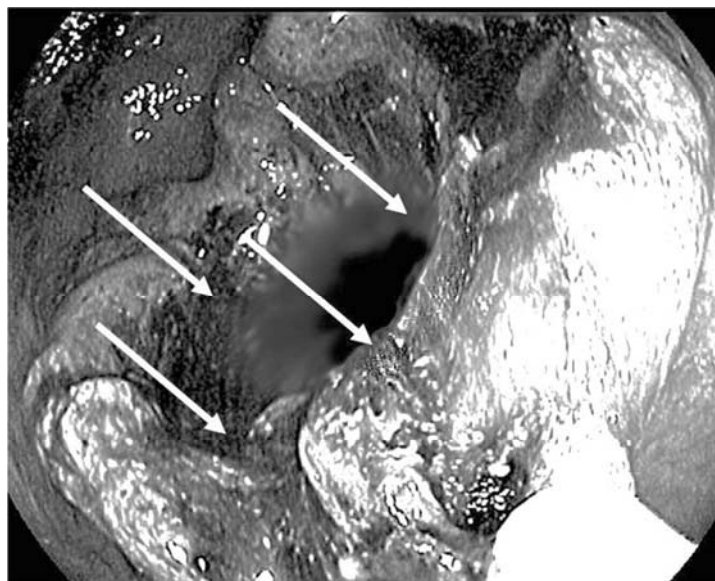


Figure 2. Sigmoid colon tumour recanalization zone (the borders are marked with arrows).

Laser recanalization was technically complex in cases of poor visibility of tumour canal orifice, mainly in infiltrative character of its growth, impossibility to fix the endoscope on the axis with the tumour canal, as well as in marked morbidity in insufflation and “hyperinflation” of the overlying parts of the colon due to valve formation in the tumour canal zone.

The performed laser recanalization enabled to conduct an adequate preparation of the bowel and to perform the uneventful routine radical resection of the sigmoid colon. After laser destruction and colonic lumen restoration in tumour zone a siphon enema was given, which resulted in abundant defecation and passage of gases. The patients were administered laxatives and vaseline oil. The treatment complex included daily infusion therapy (crystalloides and colloid solutions, potassium polarizing mixture, according to indications parenteral feeding preparations), Diavetol 15-20 mg/kg (by dry substance), Emoxipine 1,5-2,5 mg/kg, Pentoxifylline 0,2% solution 200-400 ml/daily and Reamberin 400-800 ml/daily (or Cytoflavin 10 ml solution in 100 ml of 0,9% sodium chloride solution) were given intravenously. The latter allowed to reach clinical and metabolic compensation and motor and digestive evacuating function restoration in 90% cases within 2-3 days. Beginning with the second day all the patients started receiving enteral dietary feeding.

After 4-6 days without discharging the patient from the in-patient department in the state of clinical and metabolic compensation radical operation with primary digestive tract continuity restoration was performed (only in 1 patient aged 83 tumour recanalization became the ultimate symptomatic operation considering the severity of the background pathology with cardiac decompensation against the background of CHD, postinfarction large-focal cardiosclerosis with insufficient circulation 2A, ascending aorta aneurism, arterial hypertension 3 risk 4). In this group patients sigmoid resection, low anterior resection of rectum, left hemicolectomy with primary digestive tract conti-

nity restoration by means of circular mechanic suture was performed as radical interventions. The postoperative period was uneventful. All the patients were discharged from the in-patient department in the satisfactory state for rehabilitation under ambulant conditions. The average bed day (with regard for the first treatment stage) was $17,3 \pm 6,72$.

In the comparing group in case of conservative measures being of no effect after preoperative preparation (from 6 to 25 hours) emergency interventions were performed: left hemicolectomy with terminal transverse colostomy, Gartman operation type– sigmoid obstruction resection with terminal sigmoidostomy, loop sigmoidostomy, transverse colostomy. The marked signs of intestinal obstruction required intraoperative use of various techniques of probe intestinal decompression in 71,4% cases. The postoperative course was grave in all the patients. Under all observations it required application of additional methods of restoration of digestive tract motor and evacuating function restoration (intestinal dialysis, pharmacological intestinal stimulation), performance of additional techniques of afferent therapy and systemic antibacterial treatment. In spite of intensive treatment a number of this group patients were registered postoperative complications: pneumonia (14,3%), postoperative intervention zone infection (35,7%), deep veins thrombophlebitis (7,1%). The average bed day in this group patients was $28,7 \pm 9,28$.

Life quality evaluation on the SF-36 scale revealed significant differences in the patients of comparing groups during all the analyzed terms. So the mean value of patients’ general health index after 10 days following surgical intervention in the basic group patients (treated by “Fast-Track Recovery” technique) was $68,9 \pm 7,3$, while in the comparing group it was $56,4 \pm 5,2$ (the differences between the groups are reliable in $p=0,02$). A month after discharging from the in-patient department life quality of the basic group patients (treated by “Fast-Track Recovery” technique) was enormously higher (by 32,4-50,7%) by most of

the SF-36 scale indices (domains) [PF, BP, GH, VT, SF and MH] than in the comparing group ($p=0,0006-0,0346$ by U-test Mann-Whitney).

Conclusion. Colon tumour laser recanalization enables to perform early antegrade decompression of the digestive tract with rapid restoration of motor and evacuating function and early clinical and metabolic compensation (without laparotomy and intestinal fistula formation) under the conditions of intestinal obstruction. The suggested approach allows to prepare the patient for the radical intervention in the limited terms without discharging the patient from the inpatient department, contributes to higher reliability of surgical treatment and efficacy of single-stage digestive tract continuity restoration.

Early endoscopic intestinal decompression as the first stage of “Fast-Track Recovery” concept in combination with complex program of drug correction of homeostasis impairments and intraparietal intestinal hemocirculation allow to eliminate morphofunctional impairments of adducting intestinal part and perform radical surgical treatment of colorectal cancer by prin-

ciple of routine intervention with no evidence of adducting intestinal portion problems and possibility of reliable single-stage digestive tract continuity on a tight timetable.

Laser recanalization of tumour allows successful realization of “Fast-Track Recovery” concept basic principles, which in combination with radical surgical treatment and primary digestive tract continuity restoration decreases patients’ hospital stay duration significantly, obviates the need for further surgical rehabilitation under colostomy. It contributes to sufficient economic and social effect (at the expense of hospitalization duration shortening, postoperative complications frequency decrease, disability incidence decline, exclusion of repeated surgical treatment as well as much earlier restoration of optimal life quality of the patients).

Under the conditions of cancer process neglect or absolute contraindications to surgery laser recanalization (isolated or in combination with colonic lumen stenting) may be the ultimate treatment manual in progressing intestinal obstruction.

REFERENCES

1. AJCC (American Joint Committee on Cancer) Cancer Staging Manual, 7th ed. / S.B. Edge, D.R. Byrd, C.C. Compton, A.G. Fritz. — New York: Springer, 2010. — 143 p.
2. Dunlop M. Colorectal cancer / M. Dunlop // Br. Med. J. — 1997. — Vol. 314. — P. 1882—1885.
3. Ivoghli A. Der Stellenwert minimal-invasiver Operationstechniken im Fast-track-Konzept für die Gefäßmedizin / A. Ivoghli, P. Kruska, T. Kerner, M. Göpfert, E.S. Debus // Gefäßchirurgie. — 2010. — Vol. 15, № 3. — P. 176—182.
4. Kehlet H. Evidence-Based Surgical Care and the Evolution of Fast-Track Surgery / H. Kehlet, D.W. Wilmore // Annals of Surgery. — 2008. — Vol. 248, № 2. — P. 189—198.
5. Longo W.E. Risk factors for morbidity and mortality after colectomy for colon cancer / W.E. Longo, K.S. Virgo, F.E. Johnson [et al.] // Dis. Colon. Rectum. — 2000. — Vol. 43. — P. 83—91.
6. Manual of Fast Track Recovery for Colorectal Surgery / N. Francis, R.H. Kennedy, O. Ljungqvist, M.G. Mythen [et al.]. — Toronto: Springer, 2011. — 181 p.
7. Recart A. Efficacy and Safety of Fast-Track Recovery Strategy for Patients Undergoing Laparoscopic Nephrectomy / A. Recart, D. Duchene, P.F. White [et al.] // Journal of Endourology. — 2005. — Vol. 19, № 10. — P. 1165—1169.
8. White P.F. The Role of the Anesthesiologist in Fast-Track Surgery: From Multimodal Analgesia to Perioperative Medical Care / P.F. White, H. Kehlet, J.M. Neal // Anesthesia & Analgesia. — 2007. — Vol. 104, № 6. — P. 1380—1396.

В.Л. ДЕНИСЕНКО¹, Ю.М. ГАЙН²

Друга Вітебська обласна клінічна лікарня,¹ Білоруська медична академія післядипломної освіти,² Вітебськ, Республіка Білорусь

ЗАСТОСУВАННЯ ЛАЗЕРНОЇ РЕКАНАЛІЗАЦІЇ ПУХЛИН У КОМПЛЕКСНОМУ ХІРУРГІЧНОМУ ЛІКУВАННІ ОБСТРУКТИВНОГО КОЛОРЕКТАЛЬНОГО РАКУ

Автори впровадили в клінічну практику метод лазерної реканалізації при пухлинах товстої кишки, який дозволяє в умовах кишкової непрохідності виконати ранню антеградну декомпресію шлунково-кишкового тракту із швидким відновленням моторно-евакуаторної функції та ранньою клініко-метаболічною компенсацією (без виконання лапаротомії та формування кишкових нориць). Запропонований підхід дозволяє провести підготовку пацієнта до радикального втручання за короткий період часу без виписки із стаціонару, підвищує надійність хірургічного втручання та ефективність одноетапної реконструкції шлунково-кишкового тракту. Рання ендоскопічна декомпресія кишки як перший етап концепції «швидкого відновлення» у комбінації з комплексною програмою медикаментозної корекції порушень гомеостазу та інтрапарієтальної кишкової гемоциркуляції, дозволяє швидко ліквідувати морфологічні і функціональні порушення та виконати радикальне хірургічне лікування при колоректальному раку згідно з принципами планової хірургії, що робить можливим виконання надійних одноетапних реконструкцій шлунково-кишкового тракту.

Ключові слова: лазерна вапоризація, колоректальний рак, реканалізація пухлини

Стаття надійшла до редакції: 2.04.2014