

## SURGICAL TECHNIQUE IN LEIOMYOSARCOMA OF THE INFERIOR VENA CAVA DEPENDING ON ITS LOCATION

DOI: 10.36740/WLek20220420108

Vasil I. Rusin, Serhii O. Boiko, Fedir V. Horlenko, Vasil V. Rusin, Serhii Shandor S. Boiko, Oleksandr V. Syma  
UZHHOROD NATIONAL UNIVERSITY, UZHHOROD, UKRAINE

### ABSTRACT

**The aim:** To improve the outcomes of inferior vena cava (IVC) leiomyosarcoma, propose own classification of IVC segments, which correlates with surgical access, methodology, sequence and amount of surgery.

**Materials and methods:** In the period from 1991 to 2021 in the Transcarpathian Regional Clinical Hospital named after A. Novak and in the Transcarpathian Antitumor Center 8 patients with IVC leiomyosarcoma were operated. The prevalence of leiomyosarcoma in IVC was determined according to the division of IVC into 7 segments. Defeat of one segment of IVC was in 50% of cases, two - in 37.5%, three - in 12.5%. In 5 (62.5%) cases circular resection and alloprosthesis of IVC were performed; in 2 (25%) - circular resection, alloprosthesis of IVC and implantation of the right and left renal veins in the prosthesis; in 1 (12.5%) - circular resection, alloprosthesis of IVC and implantation of the left renal vein in the prosthesis. All surgeries were performed with laparotomy access (87.5% by Chevron type).

**Results:** The average operation time was 215 (160-320) minutes, the average blood loss was 305 (250-500) ml. Postoperative complications were recorded in 2 (25%) cases. There were no cases of pulmonary embolism, venous thrombosis, prosthesis thrombosis, perioperative mortality. In 7 (87.5%) cases, surgery was radical. The overall 1-year, 2-year and 3-year survival rates were 87.5%, 71.4% and 57.7%.

**Conclusions:** The division of IVC into 7 segments characterizes the detailed definition of the cranial limit of leiomyosarcoma and segmental involvement of IVC in the tumor process, which allows to choose the right surgical tactics, perform radical resection of IVC and maintain laminar blood flow to IVC and its tributaries.

**KEY WORDS:** leiomyosarcoma, inferior vena cava, resection, prosthesis

Wiad Lek. 2022;75(4 p2):965-969

### INTRODUCTION

The incidence of leiomyosarcoma in the structure of all malignant soft tissue sarcomas is about 10% [1]. However, vascular origin of leiomyosarcoma occurs in only 0.5% of cases and at the same time, the share of inferior vena cava (IVC) accounts for 60-90% of these tumors [2].

Leiomyosarcoma of IVC is one of the rare types of malignant soft tissue sarcoma of mesenchymal origin that develops from smooth muscle in the vein wall. Evidence of this is the nature of publications, which are based mainly on literature reviews and include own data presented on a case-by-case basis within up to 10 observations. Today, only two studies have been presented in the available literature, based on the results of the treatment of a large number of patients. Thus, in 1996 the results of the world experience of surgical treatment of 218 patients with leiomyosarcoma of IVC were published, and in 2015 the presented analysis included 377 cases [3,4]. The results of these studies have shown that radical surgical resection with a negative surgical margin is the most important factor in cancer-specific survival.

The radicalism of surgical treatment can be achieved through adequate exposure of the tumor and related organs and structures, which can be achieved through properly chosen surgical access. The most common access is median laparotomy, which is considered by most of surgeons and

provides good visualization of any segment of the IVC [5]. Some authors prefer right-sided thoracoabdominal access [6], right-sided subcostal access [7] or double-side subcostal access [8]. When the suprahepatic segment of the IVC is affected or the tumor thrombus spreads towards the right atrium, it is necessary to use combined approach: median laparotomy and sternotomy [9].

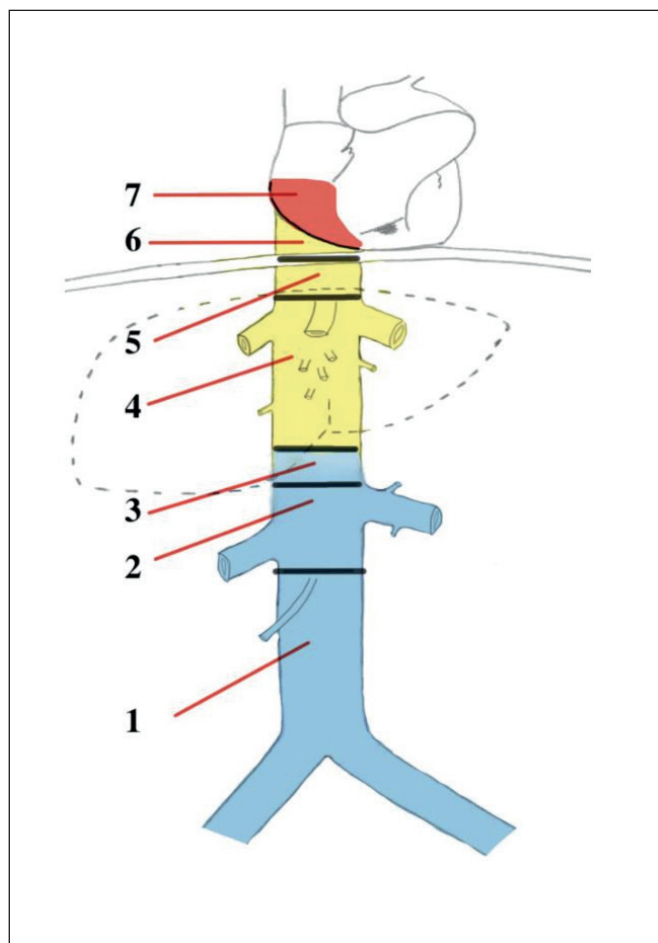
The question of the choice of the amount of resection and reconstruction of the IVC and its visceral branches of the first order remains controversial [5,10,11].

The numerous of studies use a three-level classification of IVC segments according to C.J. Staley et al.[12]. The inconsistent approach to the division into IVC segments makes it difficult to interpret the data obtained to determine the spread of the tumor process.

Active introduction of IVC leiomyosarcoma surgery into clinical practice requires a revision of the approach to the classification of IVC segments, as this affects the personalized algorithm of surgical treatment of patients.

### THE AIM

To improve the outcomes of IVC leiomyosarcoma, propose own classification of IVC segments, which correlates with surgical access, methodology, sequence and amount of surgery.



**Fig. 1.** Scheme of IVC segments: 1 – infrarenal; 2 – interrenal; 3 – suprarenal; 4 – retrohepatic; 5 – infradiaphragmatic; 6 – supradiaphragmatic; 7 – intracardiac

**MATERIALS AND METHODS**

In the period from 1991 to 2021 in the surgical department of the Transcarpathian Regional Clinical Hospital named after A. Novak and the Transcarpathian Antitumor Center performed surgery on 8 patients with leiomyosarcoma IVC: 7 women and 1 man, aged 45 to 74 years (mean – 57).

Color Doppler ultrasound and intravenous contrast computed tomography were performed during the examination. X-ray contrast phlebography was performed in 2 patients.

Based on the analysis of literature data and own experience of surgical treatment of tumor and hemorrhagic thrombosis of IVC, taking into account cranial border of venous obstruction, we used our own classification of IVC segments, according to which we consider 7 segments of IVC (Figure 1): 1) infrarenal – from the confluence of common iliac veins to the orifice of lower limit of the right renal vein; 2) interrenal – from the lower limit of the orifice of the right renal vein to the upper limit of the orifice of the left renal vein; 3) suprarenal – from the upper limit of the orifice of the left renal vein to the short hepatic veins; 4) retrohepatic – from the short hepatic veins to the upper limit of the orifice of the main hepatic veins; 5) infradi-

aphragmatic – from the upper limit of the orifice of the main hepatic veins to the lower limit of the diaphragm; 6) supradiaphragmatic– from the upper limit of the diaphragm to the right atrium; 7) intracardiac – penetration into the right atrium.

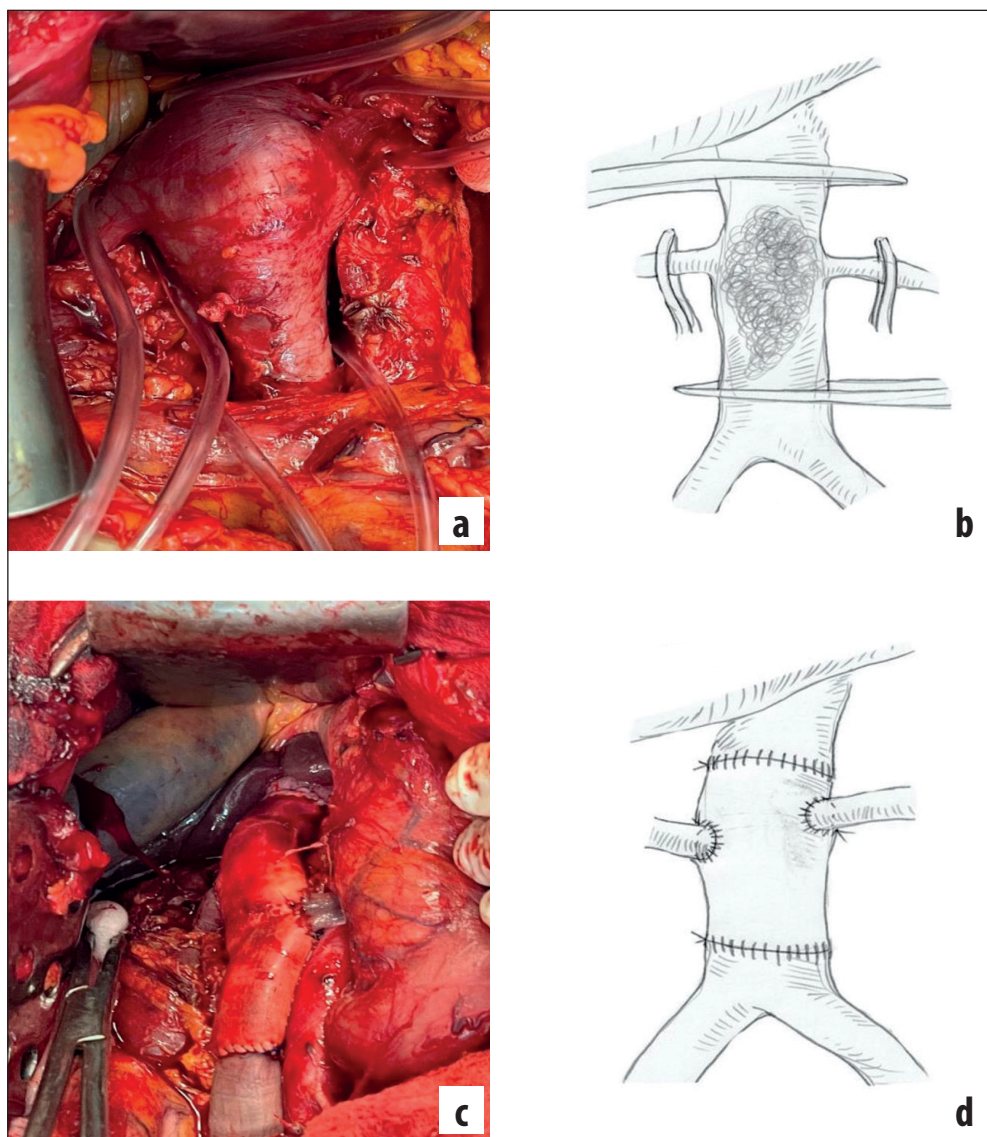
Intraluminal localization of the tumor was observed in 3 (37.5%), extraluminal – in 1 (12.5%), combined – in 4 (50%) patients. In 4 (50%) patients, the tumor was localized in one segment (in the infrarenal segment of IVC), while in 4 patients the tumor spread to several segments of IVC: in 1 (12.5%) – in infrarenal and interrenal, in 1 (12.5%) – in infrarenal, interrenal and suprarenal, in 1 (12.5%) – in suprarenal and retrohepatic segments of IVC, in 1 (12.5%) – in the infrarenal and interrenal segments of IVC with the right kidney invasion. The size of intraluminal tumors varied from 5 to 7 cm, extraluminal – from 12 to 17 cm in the largest dimension.

Surgical access: in one (12.5%) case a median laparotomy was performed, in 7 (87.5%) – a double-side subcostal laparotomy of the chevron type. To penetrate the right retroperitoneal space, a Cattell-Braash technique was performed, which involved mobilization of the cecum, ascending and hepatic curvature of the colon along the right side channel of the abdominal cavity along the Told's line to the level of common iliac vessels. The retroperitoneal tissue was stratified in a blunt and sharp pathway and the hepatic curvature of the colon and the ascending colon were removed downwards and medially. Small vessels were coagulated and large vessels were ligated. The hepato-colon and hepato-renal ligaments were dissected and Kocher's duodenum was extensively mobilized with careful gentle isolation of IVC and aorta, providing capacious access to the right kidney, duodenum, IVC, renal veins and aorta.

IVC were mobilized by dissecting the peritoneum on both sides of it. Performed mobilization of renal veins. Lumbar veins were ligated and dissected. IVC were first isolated in the interrenal and infrarenal segments, after which they were transferred to the suprarenal segment. During the mobilization of IVC, we imposed turnstiles and all 4 areas of interest: infrarenal and suprarenal segments of IVC, right and left renal veins.

In the case of intraluminal localization of the tumor, IVC intersected at a distance of at least 5 mm from the caudal limit of invasion of the tumor into the vein wall, its distal end was raised, which contributed to adequate revision of the posterior surface of the IVC where branches of lumbar veins can left which were not detected in front access. If the tumor was localized only in the infrarenal segment, then above the tumor by 5 mm, but below the renal veins, IVC intersected again and removed the drug in one block. When the tumor spread to the suprarenal segment, the upper limit of the IVC section passed above the renal veins, and the renal veins themselves were cut off from the IVC at a distance of 5 mm from their orifice. After that, end-to-end alloprosthesis and end-to-side one or both renal veins implantation was performed in the prosthesis (Figure 2 a, b, c, d).

In the case of extraluminal or combined tumor growth, the resection amount included the involved of IVC segment and



**Fig. 2.** Intraluminal tumor of infrarenal, interrenal and suprarenal segments of IVC, segmental resection and prosthesis of IVC with Gore-tex prosthesis with implantation of right and left renal veins: a-b) intraluminal tumor of infrarenal, interrenal and suprarenal segments of IVC (type of surgical wound and scheme); c-d) segmental resection and prosthesis of IVC with Gore-tex prosthesis with implantation of right and left renal veins (type of surgical wound and scheme).

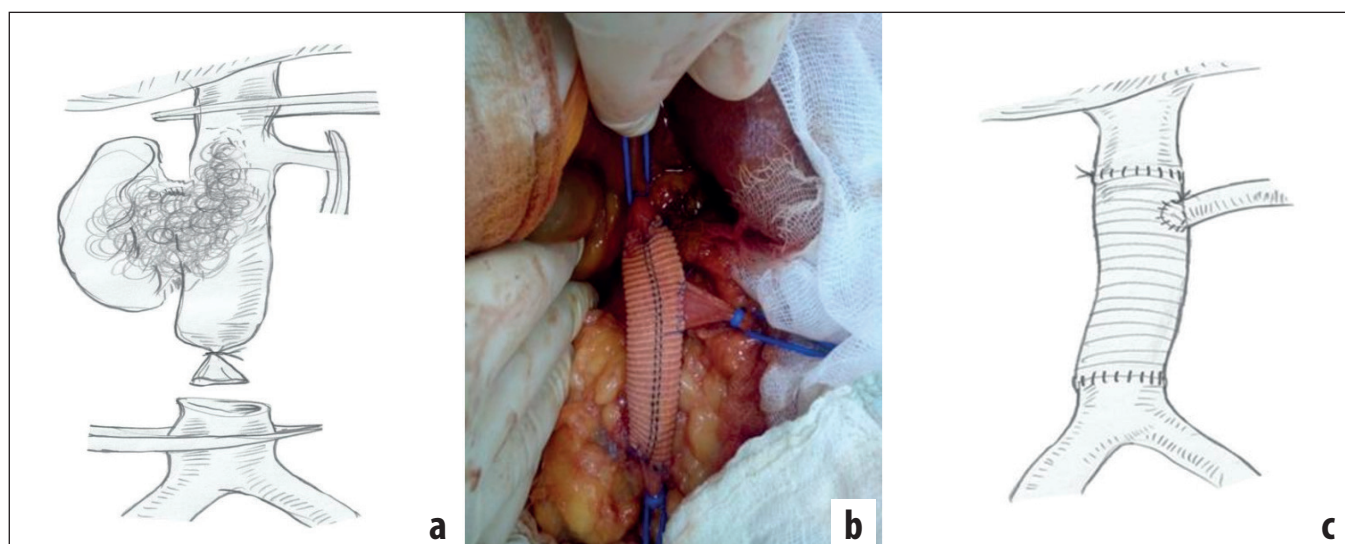
adjacent organs and tissues. In one (12.5%) case, when the tumor spread to the right kidney, one unit performed segmental resection of the IVC, right nephrectomy, prosthesis IVC and implantation of the left renal vein in the prosthesis (Figure 3 a b c).

In the case of involvement of a retrohepatic segment of IVC, the liver was mobilized by dissecting the entire ligaments. Mobilization of the right lobe of the liver continued toward the IVC, dissecting the hepato-renal and hepato-colonic ligaments and any other additional fixation apparatus of the right lobe of the liver. Additional short hepatic veins, which could be on the posterior surface of the liver in the area of the right and caudal lobes intersected between the imposed ligatures. Gentle movements were performed to rotate the right lobe of the liver using the piggyback technique to the left subcostal area. The piggyback technique of liver mobilization and Pringle maneuver were used in 1 (12.5%) case. After squeezing the hepato-duodenal ligament, we paused for up to 5 minutes, which helped reduce the volume of the liver and made it easier to rotate the liver.

Alloprosthesis of IVC were performed with polytetrafluoroethylene (PTFE) (n = 6) or Gore-tex (n = 2) prosthesis

with a diameter of 18-22 mm. In 5 (62.5%) cases circular resection and alloprosthesis of IVC were performed; in 2 (25%) – circular resection, alloprosthesis of IVC and implantation of the right and left renal veins in the prosthesis; in 1 (12.5%) – circular resection, alloprosthesis of IVC and implantation of the left renal vein in the prosthesis.

IVC prosthetics began with the imposition of the cranial part of the anastomosis, followed by implantation of one or both renal veins. At each stage of the formed anastomosis used early restoration of venous return from the organs by local application of vascular clamps. The caudal part of the anastomosis was formed under conditions of complete recovery of venous return from one or both kidneys. Means of thermal ischemia of the kidneys were not used. Initial systemic heparinization and periodic local heparinization were used all the time during prosthesis suturing. In the early postoperative period up to 14 days used systemic administration of low molecular weight heparin in a prophylactic dose and then patients were prescribed an oral form of low molecular weight heparin in a prophylactic dose for 6 months.



**Fig. 3.** Combined nature of tumor growth of infrarenal and interrenal segments of IVC with spread in the right kidney, segmental resection and prosthesis of IVC with PTFE prosthesis with left renal vein implantation: a) tumor of combined growth of infrarenal and interrenal segments of IVC with spread in the right kidney (scheme); b-c) segmental resection and prosthesis of IVC with PTFE prosthesis with implantation of the left renal vein (type of surgical wound and scheme).

Postoperative complications were assessed according to the Clavien-Dindo classification. Throughout the follow-up period, signs of venous thrombosis, pulmonary embolism, myocardial infarction and kidney damage were monitored at standard postoperative visits and the overall survival of patients was studied.

Given that the study group of patients is less than 10 people, we used simple methods of statistical analysis using which we calculated the average values of indicators.

## RESULTS

The average surgery time was 215 (160-320) minutes, the average blood loss was 305 (250-500) ml.

Postoperative complications were recorded in 2 (25%) cases (I-II severity according to the Clavien-Dindo classification). There were no cases of pulmonary embolism, venous thrombosis, prosthesis thrombosis, perioperative mortality.

In 7 (87.5%) cases, surgery was radical. One (12.5%) patient with large volume of the IVC invasion to the retrohepatic segment and the right lumbar muscle on histological examination revealed a positive surgical margin of the lumbar muscle. After 7 months, this patient developed a local recurrence in the right lumbar muscle and showed signs of disease progression in the form of multiple metastases in the liver and both lungs. The patient died 3 months after disease progression.

The overall 1-year survival was 87.5%. One patient is under observation for one year, the observation continues. The overall 2-year and 3-year survival was 71.4% and 57.7% respectively (among 7 patients).

## DISCUSSION

During the characterization of IVC different variants of division into segments are used, which leads to the diagnosis of a

more general location of the IVC, covering its long sections. The greatest use in clinical practice was the classification of S.J. Staley et al. (1967), according to which it is accepted to divide IVC on the level of renal and hepatic veins into three segments: lower (from the level of confluence of common iliac veins to the level of renal veins), middle – (including the level of renal and hepatic veins) and upper – (above hepatic veins to the atrium) [12]. The segments of IVC where the cranial border of the tumor can be localized are left out, because they are automatically absorbed by this classification and are part of either the middle or upper segments. A clear definition of the cranial border of the affected segment of IVC is directly reflected in the understanding of the level of involvement of IVC in the process and tactics of surgical treatment.

Coverage of the location of the leiomyosarcoma-affected segment of the IVC remains ambiguous. Thus, some authors point to the predominant invasion of the middle segment (from renal to hepatic veins) of IVC, which consists of two separate segments – suprarenal and retrohepatic and therefore, it is not known for sure what is the cranial limit of IVC invasions [9,13], while others indicate a predominant invasion of the infrarenal segment [10,14].

In addition, some authors detail the IVC invasions and provide data on the invasions of one, two or three segments [9]. We also apply a detailed characterization of the segmental spread of leiomyosarcoma by IVC. Thus, in our study, lesions of one segment of the IVC were in 50% of cases, two – in 37.5%, three – in 12.5%.

Based on our own classification approach to the division of IVC into segments, we propose the following algorithm for surgical treatment of IVC leiomyosarcoma: 1) in infrarenal, interrenal and suprarenal spread is performed laparotomy, radical resection of IVC with implantation in the prosthesis of renal veins, if they were involved in the process; 2) in retrohepatic, infradiaphragmatic and supradiaphragmatic spread

is performed laparotomy, diaphragmotomy (if necessary), piggyback liver mobilization technique and Pringle maneuver, radical resection of IVC with implantation in a prosthesis of renal or hepatic veins, if they were involved; 3) at intracardiac distribution the combined access – a thoracotomy in the conditions of artificial blood circulation is carried out.

The most complex segments of IVC at the stage of mobilization are retrohepatic and intracardiac, because access to them is provided by mobilization of the liver and its rotation and diaphragmotomy or thoracotomy. The rest of the IVC segments are available to a wide range of surgeons. If, in most cases, intracardiac and supradiaphragmatic thrombi of IVC can be transferred by finger displacement of the apex of the thrombus into the infradiaphragmatic and sometimes retrohepatic segment of IVC, and removed, the localization of leiomyosarcoma in these segments of IVC involves radical incision.

## CONCLUSIONS

The division of IVC into 7 segments characterizes the detailed definition of the cranial limit of leiomyosarcoma spread and segmental involvement IVC in the tumor process, which allows you to choose the optimal surgical tactics, perform a radical resection of the IVC and maintain laminar blood flow through the IVC and its tributaries of the first order, which provides satisfactory immediate and long-term results.

## REFERENCES

1. LeMinh T., Cazaban D., Michaud J. et al. Great saphenous vein leiomyosarcoma: a rare malignant tumor of the extremity: two case reports. *Ann Vasc Surg.* 2004;18:234-36. doi: 10.1007/s10016-003-0090-2.
2. Italiano A., Toulmonde M., Stoeckle E. Et al. Clinical outcome of leiomyosarcomas of vascular origin: comparison with leiomyosarcomas of other origin. *Ann Oncol.* 2010; 21:1915-21. doi: 10.1093/annonc/mdq039.
3. Mingoli A., Cavallaro A., Sapienza P. Et al. International registry of inferior vena cava leiomyosarcoma: analysis of a world series on 218 patients. *Anticancer Res.* 1996;16:3201-05.
4. Wachtel H., Gupta M., Bartlett E.K. et al. Outcomes after resection of leiomyosarcomas of the inferior vena cava: A pooled data analysis of 377 cases. *Surg Oncol.* 2015;24(1):21-7. doi: 10.1016/j.suronc.2014.10.007.
5. Schwarzbach M.H.M., Hormann Y., Hinz U. Et al. Clinical results of surgery for retroperitoneal sarcoma with major blood vessels involvement. *J. Vasc. Surg.* 2006;44(1):46-55. doi: 10.1016/j.jvs.2006.03.001.
6. Daylami R., Amiri A., Goldsmith B. et al. Inferior vena cava leiomyosarcoma: is reconstruction necessary after resection? *J Am Coll Surg.* 2010;210(2):185-90. doi: 10.1016/j.jamcollsurg.2009.10.010.
7. Brancaccio G., Celoria G., Berti S. et al. Recurrent a symptomatic retrohepatic leiomyosarcoma of the inferior vena cava. *EJVES extra.* 2005;10:136-8. doi: 10.1016/j.ejvsextra.2005.08.009.
8. Zhang H., Wang K., Hong P. et al. Clinical experience with the treatment of retroperitoneal vascular leiomyosarcoma originating from large veins. *BMC Surg.* 2021;21:326. doi: 10.1186/s12893-021-01322-z.
9. Kieffer E., Alaoui M., Piette J.C. et al. Leiomyosarcoma of the inferior vena cava: Experience in 22 cases. *Ann Surg.* 2006;244:289-95. doi: 10.1097/01.sla.0000229964.71743.db.
10. Pantoja J.L., Patel R.P., Baril D.T. et al. Caval reconstruction with undersized ringed graft after resection of inferior vena cava leiomyosarcoma. *Ann Vasc Surg.* 2020;65:25-32. doi:10.1016/j.avsg.2019.11.007.
11. Hardwigsen J., Baque P., Crespy B. et al. Resection of the inferior vena cava for neoplasms with or without prosthetic replacement: a 14-patient series. *Ann Surg.* 2001;233:242-9. doi: 10.1097/0000658-200102000-00014.
12. Staley C.J., Valaitis J., Trippel O.H. et al. Leiomyosarcoma of the inferior vena cava. *Amer J Surg.* 1967;113:211-16.
13. Mingoli A., Feldhaus R.J., Cavallaro A. Et al. Leiomyosarcoma of the inferior vena cava: analysis and search of world literature on 141 patients and report of three new cases. *J Vasc Surg.* 1991;14(5):688-99. doi: 10.1067/mva.1991.30426.
14. Illuminati G., Calio F.G., D'Urso A. Et al. Prosthetic replacement of the infrahepatic inferior vena cava for leiomyosarcoma. *Arch Surg.* 2006;141(9):919-24. doi: 10.1001/archsurg.141.9.919.

*The work was performed as part of a basic study: «Venous hypertension and arterial incapacity: diagnosis, treatment, prevention». State registration number of the topic: № 0120U100405.*

## ORCID and contributionship:

Vasil I. Rusin: 0000-0001-5688-9951<sup>A</sup>  
 Serhii O. Boiko: 0000-0002-8073-3030<sup>F</sup>  
 Fedir V. Horlenko: 0000-0002-0496-2069<sup>B</sup>  
 Vasil V. Rusin: 0000-0003-4854-0228<sup>E</sup>  
 Serhii Shandor S. Boiko: 0000-0003-3016-6901<sup>D</sup>  
 Oleksandr V. Syma: 0000-0002-4780-6322<sup>C</sup>

## Conflict of interest:

*The Authors declare no conflict of interest.*

## CORRESPONDING AUTHOR

**Serhii O. Boiko**  
 Uzhhorod National University  
 22 Peremohy St., 88018 Uzhhorod, Ukraine  
 tel: +38(0312) 61-35-70  
 e-mail: boiko.likar@gmail.com

**Received:** 27.11.2021

**Accepted:** 30.03.2022

A - Work concept and design, B - Data collection and analysis, C - Responsibility for statistical analysis, D - Writing the article, E - Critical review, F - Final approval of the article