

## New Three-Dimensional Cephalometric Analysis Based on Medium Field of View CBCT Scans: Setting of Normality Values for the 7-12 Years Old Children

Larysa A. Dakhno<sup>1</sup>, Tamara Vyshemyrska<sup>2</sup>, Pavlo Burlakov<sup>2</sup>,  
Myroslav Goncharuk-Khomyn<sup>3</sup>, Natalia Rashchenko<sup>2</sup>

1. Department Oral & Maxillofacial Pathology and Radiology, Shupyk National Healthcare University of Ukraine, Kyiv, Ukraine.
2. Department of Orthodontics and Prosthodontics Propedeutics, Bogomolets National Medical University, Kyiv, Ukraine.
3. Department of Restorative Dentistry, Uzhhorod National University, Uzhhorod, Ukraine.

### Abstract

Objective of the research was to determine mean cephalometric parameters among children aged 7-12 years old with the use of originally developed three-dimensional analysis of medium field of view CBCT images and verify sustainability of obtained indicators as references of normality values.

Present research was conducted in the form of retrospective designed study, all CBCT data used for the research was already presented within the database of Central Laboratory Diagnosis of the Head (Kyiv, Ukraine). Final sample of 25 DICOM datasets was converted and analyzed using the SIMPLANT O&O software. Algorithm of originally developed Dakhno-Vyshemyrska-Burlakov (DVB) cephalometric analysis realized for the obtained 3D scans included marking of 33 skeletal and dental landmark points (11 single and 11 paired/ bilateral). Out of 25 CBCT scans, included into study group, 10 were obtained from male pediatric patients, and 15 from female. Mean age of patients at the time of CBCT scan obtainment was  $9.46 \pm 2.31$  years. The differences between each parameter registered among male and female persons were not statistically approved ( $p > 0.05$ ), except for the linear parameters of jaws and parameters of growth pattern prediction.

Adjusted intra-rater agreement for the set of calculated cephalometric parameters after triple repeated assessment for the Investigator 1 was 0.95 and for the Investigator 2 – 0.97, while pooled inter-rater agreement reached level of 0.92. Proposed 3D cephalometric analysis based on medium FOV CBCT scans may be effectively used for the pediatric patients aged 7-12 years old, and such diagnostic approach fully corresponds with the generally accepted recommendations for effective dose minimization among orthodontic pediatric patients.

Skeletal and dental cephalometric parameters were established for children 7-12 years old based on 25 CBCT data sets, which considering repeatability of obtained results registered by the two independent investigators, may be categorized as a reference set of normality values.

**Clinical article (J Int Dent Med Res 2023; 16(4): 1687-1700)**

**Keywords:** Three-dimension, Cephalometric analys, CBCT.

**Received date:** 09 October 2023

**Accept date:** 10 December 2023

### Introduction

2D cephalograms support diagnostics of growth and developmental anomalies among orthodontic patients, while also help to monitor dynamics during the treatment by assessing the mutual interrelations between skeletal structures and the teeth.<sup>1, 2, 3</sup> However, 2D cephalometric

radiographs have significant limitations due to the superimposition of anatomical structures, two-dimensional flattening and various magnifications of facial skull anatomical structures.<sup>4, 5</sup> In most cases, additional panoramic and frontal radiographs are also necessary for precise diagnostics, which in turn increases the radiation dose received by the patient.<sup>6</sup> On the other hand it is important to note that there is still deficiency of reliable evidence-based data regarding dominant diagnostic and therapeutic significance of 2D cephalometry itself, except when it is necessary to make a decision on the extraction of individual tooth or refrain from such manipulation.<sup>7, 8</sup>

#### **\*Corresponding author:**

Myroslav Goncharuk-Khomyn  
Department Oral & Maxillofacial Pathology and Radiology,  
Shupyk National Healthcare University of Ukraine,  
Kyiv, Ukraine.  
E-mail: [myroslav.goncharuk-khomyn@uzhnu.edu.ua](mailto:myroslav.goncharuk-khomyn@uzhnu.edu.ua)

The advent of cone beam computed tomography (CBCT) has made it possible to visualize all of the anatomical structures of the facial skull in detail, as CBCT scan creates a series of cross-sectional images in three planes and also allows to produce three-dimensional reconstructions of 3D structures including teeth, jaws, TMJ, airways, sinuses, nasal cavity and soft tissue structures of the face.<sup>9, 10</sup> However, considering radiation load received by CBCT, indications for prescribing a large field of view (FOV) CBCT scans for children and adolescents are limited to complex cases, such as congenital malformations or skeletal asymmetries.<sup>11, 12</sup>

Basically such cases includes clinical situations when the benefits of 3D imaging justify the received radiation exposure according to the principles of ALARA (As Low As Reasonably Achievable), ALADA (As Low As Diagnostically Acceptable) and the ALADAIP principle (As Low As Diagnostically Acceptable being Indication-oriented and Patient-specific), which were adopted by the DIMITRA research group.<sup>5, 13, 14, 15</sup>

Recent systematic review revealed that diagnostic accuracy of CBCT-synthesized lateral cephalograms are comparable to the conventional ones, while usage of already existed CBCT scans could help to reduce radiation exposure level with saving time and costs for the patients.<sup>16</sup> Moreover, CBCT scans themselves provide opportunities not only for 2D-based, but also for three-dimensional cephalometric analysis.<sup>15, 17, 18</sup>

Lowering field of view, voxel size and dose in general while dealing with CBCT in the orthodontic practice potentially may help to reduce the effective dose on the patients, but it also compromise diagnostic potential of obtained 3D scans, and limits possibilities to analyze small anatomical structure.<sup>17</sup> There is a gap in consensus to which dose radiation load should be minimized, and especially by which approach this reduction should be provided in the first place, to follow specific diagnostic targets of the orthodontic treatment planning.<sup>17, 18</sup>

Considering all above-mentioned facts it seems reasonable to develop different scanning protocols with specifically controlled sets of scanning parameters adapted to the peculiarities of particular orthodontic indications.<sup>17</sup>

## Materials and methods

Present research was conducted in the form of retrospective designed study, focused on the provision of cephalometric analyses over medium FOV CBCT-scans of children 7-12 years old, who's data were already presented within the database of Central Laboratory Diagnosis of the Head – CLDH (Kyiv, Ukraine). STROBE checklist was taken into account during the organization of present research, while also adherence to STROBE guidelines was considered during preparation of present manuscript. No additional X-ray examinations were provided for the patients, who's CBCT scans were already present in available database and further included in present research.

Prior to CBCT examinations, which were held due to the different indications and based on targeted referral from different dental specialists, all patients signed informed consent form agreeing on the above-mentioned diagnostic procedure and possibility of using their anonymized datasets for potential research objective if such would be within scientific interest.

All CBCT scans were performed with Gendex CB-500 by iCat scanner (Imaging Sciences International, Hatfield, PA, USA), which operates in pulsed mode of radiation with following parameters: voxel size – 300  $\mu$ m, sitting patient's position, natural head position, usual occlusion, no chin rest, fixed with a head band.

Primary CBCT database of CLDH included 50069 data sets of dental patients. The following inclusion criteria was used to form primary cohort of CBCT scans, which could be used for the formulated objective: 1) Ukrainian origin of the patient; 2) age range within 7-12 years old; 3) mixed dentition; 4) skeletal symmetry; 5) Angle's class I relationship of the first permanent molars; 6) normal vertical and horizontal incisal overlap (within 2.0 mm  $\pm$  0.5 mm); 7) no clinically detectable orthodontic problems; 8) no congenital developmental pathologies. Specific age range of 7-12 years old was utilized to measure cephalometric parameters of pediatric patient particularly with mixed dentition.

Next parameters were used as exclusion criteria: 1) non-Ukrainian origin of the patient; 2) age under 7 and over 12 years old; 3) absence of one or more first permanent molars; 4) agenesis

or loss of at least one permanent tooth; 5) presence of skeletal asymmetries; 6) post-traumatic malformations or deformities; 7) presence of any form of malocclusion; 8) presence of congenital growth and developmental defects.

After formation of primary CBCT scans cohort they were checked regarding applied protocol of scanning, and only those corresponding to the low-dose protocol of CBCT scanning (120 kVp, 5 mAs, exposure time 3 s) with medium field of view (FOV: 8 cm (H) x 14 cm (D) – EDS Mode) were included for further analysis. Such requirements were considered to ensure minimization of potential exposure dose while not compromising diagnostic potential of the scans.

Medium FOV scans were considered for the study only if such were limited caudally by the point Me (the most inferior midpoint of the chin on of outline of the mandibular symphysis), cranially – by the point Or (the most inferior anterior point on the orbit's margin), ventrally – by the point Pog (the most anterior midpoint of the chin in the midsagittal plane), necessarily including the incisors of the upper and lower jaws and pogonion of soft tissue; laterally – the volume should include the area of the temporomandibular joint (TMJ) and the point Po (the most superior point on the bony external auditory meatus).

Application of inclusion and exclusion parameters, while also considering obligatory condition of realized low-dose CBCT scanning mode, resulted into primary cohort of 72 anonymous sets of medium FOV CBCT scans performed at Central Laboratory Diagnosis of the Head (Kyiv, Ukraine) between April 2019 and December 2021.

Out of these 72 patients, who's data sets were collected, only 25 patients demonstrated availability of portrait and intraoral photos within dental records taken at the period of CBCT examination, by which their harmonious facial features were approved. These twenty-five DICOM datasets formed study group, and were converted and analyzed using the SIMPLANT O&O software (Materialise NV, Ghent, Belgium).

Before the provision of cephalometric analysis itself and marking of anatomical landmark, all CBCT-scans from study group were repositioned for the controlled the Natural Head Position (NHP) obtainment in three mutually

perpendicular planes (axial, sagittal, transversal) following next guidelines: 1) for the sagittal plane – the reference was the horizontal line between the ANS (anterior nasal spine) and PNS (posterior nasal spine); 2) for the axial plane – the reference was the vertical line that crossed the midpoint of the Dens procesus C2, of the middle of C1 and of the foramen magnum; 3) for the transversal plane – the reference was the horizontal line between the zygomaticomaxillary sutures on the floor of the orbit on the right and left.

Processing of converted CBCT datasets was provided due to the originally developed 3D cephalometric analysis algorithm designed by Larysa A. Dakhno (D), Tamara Vyshemyrska (V) and Pavlo Burlakov (B), and abbreviated as DVB cephalometric analysis. Algorithm of DVB analysis included marking of 33 skeletal and dental landmark points (11 single and 11 paired/bilateral).

Table 1 presents a list of anatomical landmark points included in the 3D DVB cephalometric analysis.

Manual placement of the 33 anatomical landmarks were performed independently by two researchers (V.T. and B.P.) on the SIMPLANT O&O software (Materialise NV, Ghent, Belgium), and was repeated twice after a 4-week interval. Each landmark was identified on the 3D surface and rectificated in the multi-planar reconstruction (MPR) images (Fig. 1). The researchers had not access neither to each other's results, nor to their first session's results. In this study, the reliability of the reference points was not investigated.

Used 33 points formed 5 planes, 19 lines (3 of those are bilateral) and 14 angles (5 of those are bilateral). Frankfurt Plane (FP) was considered as the horizontal reference plane and the perpendicular through Orbitale Left and Right to FP established the True Vertical Plane (TVP). The vertical and horizontal position of skeletal landmarks were then measured relative to TVP (Table 2, Fig. 2).

Based on the 33 provided landmarks overall 13 skeletal (3 paired, 7 single), 10 maxillary and mandibular (4 paired, 2 single), and 6 dentoskeletal cephalometric measurements (1 paired, 4 single) could be measured (Table 3-4). All parameters of 3D DVB cephalometric analysis were programmed in a specialized SIMPLANT O&O cephalometric module.

The 3D cephalometric measurements of

midface, maxilla, mandible and dentoskeletal features were calculated.<sup>18</sup> Data export of measured parameters, obtained at each session and on each CBCT scan, as well as their statistical processing were performed using Microsoft Excel 2016 software (Microsoft Office 2016, Microsoft Corporation India Pvt. Ltd., New Delhi, India).

### Statistical analysis

The electronic primary database was created within Microsoft Excel 2016 (16.0.6769.2017) spreadsheet software Microsoft Office 2016, Microsoft Corporation India Pvt. Ltd., New Delhi, India). In-depth statistical analysis was performed using software STATISTICA 10 by StatSoft (Tulsa, OK, United States). The mean normal value for each linear and angular parameter obtained during 3D cephalometric DVB analysis was calculated, while also its' standard deviation (SD) was registered. During the calculation of mean values and standard deviations *i*-parameter was considered. The confidence interval for the measurement average value of the *i* -parameter was determined by taking into account Student's coefficient and mean square deviation of the measurement results. Student's coefficient was 2.060 for the total number of children ( $n = 25$ ) and confidence level ( $p = 0.95$ ). Separately for boys with  $n = 10$  and for girls with  $n = 15$  at the same confidence level, Student's coefficient was 2.228 and 2.133, respectively. Intra- and inter-rater agreements between cephalometric parameters registered by two investigators independently were evaluated by Cohen's kappa criterion.

### Ethical aspects

Protocol of present study and its alliance with corresponding ethical norms was approved by Commission on issues of bioethical expertise and ethics of scientific research formed at the National Medical University named after O. O. Bogomolets (Kyiv, Ukraine) and granted with expert confirmation № 113 dated 07/02/2018.

### Results

Study group consisted of 25 medium FOV CBCT scans, out of which 10 were obtained from male pediatric patients, and 15 from female. Mean age of patients at the time of CBCT scan obtainment was  $9.46 \pm 2.31$  years.

On the basis of the cephalometric bone landmarks pointed on the medium FOV CBCT

images, which were obtained from 25 children without obvious orthodontic pathologies and aged 7-12 years, dentoskeletal, maxilla, mandible and skeletal mean values were calculated, while also their SDs were established (Table 5, Fig. 3, 4, 5).

The dentoskeletal factors largely determine esthetic facial profile at the level of the lower third. Normal values of these factors usually create a balanced and harmonious ratio of the lips, nose base, jaws and chin (Fig. 3).

Maxilla and Mandible normal values are important parameters for determining the symmetry of the facial and for growth individual patterns prediction (Fig. 4).

The skeletal factors determine the proportions and harmony of the face and allow to evaluate the relationship of the jaws with each other and with other structures of the skull in 3D planes (Fig. 5).

The 3D cephalometric measurements of midface, maxilla, mandible and dentoskeletal ratios (left and right sides separately), verified among children of different gender, shown in Table 6.

The differences between each parameter registered among male and female persons were not statistically approved ( $p > 0.05$ ), except for the linear parameters of jaws and parameters of growth pattern prediction. Such outcome could be argued by the inclusion within the study group children of specific age range 7 -12 years old. Girls demonstrated larger mandibular body length by 1.7 mm, nevertheless there was no difference in the mandibular ramus length between genders ( $p > 0.05$ ). Differences regarding growth pattern prediction were presented by the girls having greater mandibular angles by  $3.1^\circ$  and longer lower third of anterior facial height by 2.2 mm, correspondingly.

Adjusted intra-rater agreement for the set of calculated cephalometric parameters after triple repeated assessment for the Investigator 1 was 0.95 and for the Investigator 2 – 0.97, while pooled inter-rater agreement reached level of 0.92.

### Discussion

General trend of dental treatment optimization and individualization is also fair for orthodontic practice by improving techniques of primary diagnostics, treatment planning and



forming conditions for personalized orthodontic interventions considering individual dental and skeletal maturity stages, while also taking into account interrelations within dental and skeletal cephalometric parameters.<sup>19</sup> Cephalometric analysis remains one of the most objective instruments for differentiation and objectification of dental, skeletal and dentoskeletal form of various malocclusions.<sup>1, 2, 3</sup>

Due to the systematic review of 2013 methodologically standardized studies on 3D cephalometric analysis is of high importance to evidence efficiency of 3D cephalometry within orthodontic practice,<sup>3</sup> while nowadays such method already characterized with high level of credibility, but still should be improved to overcome several associated disadvantages, among which radiation load remains prominent one.<sup>20, 21, 22</sup>

Because the vast majority of orthodontic patients are children and adolescents, it must be taken into account that the received effective dose of radiation in children is 36% higher than in adults. It should also be taken into account that there is a high risk of developing stochastic effect due to the continued increase in life expectancy.<sup>23</sup> Thus, when orthodontists prescribe CBCT examinations for children, radiation protection becomes of great importance. Medical physicists and engineers of both CBCT and 2D dental X-ray machines are constantly focused on the technical and algorithmic possibilities to further reduce effective doses. Relevant study concluded that using low-dose protocols CBCT examination can be prescribed for the most radiosensitive patients in pediatric dentistry and orthodontics.<sup>24</sup> Effective but the same time rapid way to decrease the radiation dose during CBCT examination of pediatric orthodontic patients is to reduce the field of view (FOV).

FOV is a cylindrical volume presented as H x D cm, where H is the height and D is the diameter. Medium FOV CBCT scans are a cylinder with a maximum height of 12.88 cm and diameter of 16.48 cm for adults and 11.94 x 15.87 cm for adolescents, respectively.<sup>25, 26</sup> This FOV size is enough to reliably detect all bony landmarks between the Frankfurt horizontal plane (FHP) and soft tissue chin of children, which meets the requirements of 3D cephalometric analysis. Medium FOV size, optimal positioning for each patient and individual scanning settings in accordance with the

indications of CBCT examination, significantly reduces the radiation dose and can be used for comprehensive orthodontic diagnosis of children and adolescents.<sup>25, 26</sup>

Downsizing FOV reflects an aspect included into the list of radioprotective precautions for children undergoing CBCT examination, which also contains collimation, largest voxel size in relation to treatment need, decrease of exposure time, reduction of projections amounts and lowering of beam intensity.<sup>27</sup>

Kissel et al. proposed 3D cephalometry approach, which in some manner is similar to the originally developed DVB analysis described in this study regarding downsizing FOV to reduce the radiation load on the pediatric patients.<sup>26</sup> Authors concluded that usage of alternative variables related to Frankfurt horizontal plane could help to further describe interrelations with standard variables related to the reference plane S-N with the levels of determination in the range of 0.15-0.95.<sup>26</sup> Present research also demonstrated efficiency of medium field of view (FOV: 8 cm (H) x 14 cm (D)) and low-dose scanning mode which may be used for the pediatric patients, while the main focus of our study was to demonstrate that originally developed DVB may be used to set a new values of normality since it have given analogical results among 25 different patients with no obvious sign of orthodontic pathology. Also, in originally developed methodology of DVB analysis the reference system was adopted for measurements of medium FOV CBCT images: for the vertical measurements reference plane of the anterior cranial base was replaced by the Frankfurt horizontal plane, and for diagnostics in the sagittal plane True Vertical Plane was used.

Previously approach of using cephalograms reconstructed from ultra-low dose CBCT scans was proposed, which helped to minimize the difference in cephalometric measurements to 2 mm or smaller while comparing such with using standard lateral cephalograms.<sup>28</sup> In present study it was highlighted that 3D images provide greater amount of features for cephalometric analysis compare to the conventional 2D images, taking in to account possibilities for spatial but not only for planimetric processing of linear and angular measurements.

Farronato M. et al. approved that

reduced FOV does not compromise possibility of correct skeletal class determination even without using cephalometric landmark of S and N.<sup>25</sup> On the other hand the same author has proposed 3D cephalometric normality ranges, which clinician may use as a reference set of normality for 3D cephalometrics.<sup>18</sup> In present study we also presented set of cephalometric values which may be interpreted as parameters of normality while using proposed DVB protocol of 3D cephalometric analysis provided over medium FOV CBCT scans. Also mean values established in our study may be interpreted as a set of normality values just for patients of Ukrainian origin aged 7-12 years old, which may be categorized as one of the limitations of the provided research.

Future perspective of present research is based on the approbation of originally proposed approach among greater set of orthodontically-healthy children with mixed dentition to approve sustainability of obtained cephalometric measurements as values of norm, which in future may be used as references. Also, usage of machine learning methods for the detection of targeted 33 points and further automated or at least semi-automated calculations of the angular and linear parameters would be beneficial for the optimization of diagnostic process considering growing interest to the implementation of AI-based models into the clinical dental practice.<sup>29</sup> Still it should be kept in mind that methods of AI-based computer vision characterized by different level of divergences during cephalometric landmarks verification, and due to such issue validated testing samples should be formed. Moreover, AI-models developed for the cephalometric analysis purpose must be repeatedly corrected and confirmed before their daily in-practice usage, since such previously demonstrated significant discrepancies for several important cephalometric measurements, such as corpus length, mandibular arc, lower face height and overjet compare to values obtained by manually compare to orthodontist specialists.<sup>30</sup>

Attention also should be paid to the possibility for using medium FOV CBCT scans

for measuring cephalometric parameters different from those originally proposed by DVB algorithm, thus expanding diagnostic potential of obtained 3D data with no additional increase in radiation load.

Limitations of present research associated with relatively small study sample, nevertheless, it should be kept in mind that present study is a pilot one demonstrating possibilities of 3D cephalometry based on medium FOV scans with involvement of randomly selected 25 children of 7-12 years old; further greater amount of patients would be involved to confirm significance of obtained cephalometric measurements as values of normality. Also, obtained results is reliable for Ukrainian study sample of pediatric patients, and such should be validated over samples of different origin to argument universality of proposed DVB approach, since previous researches have demonstrated possibility of normal cephalometric values variations among persons of different ethnic entity.<sup>31, 32</sup>

## Conclusions

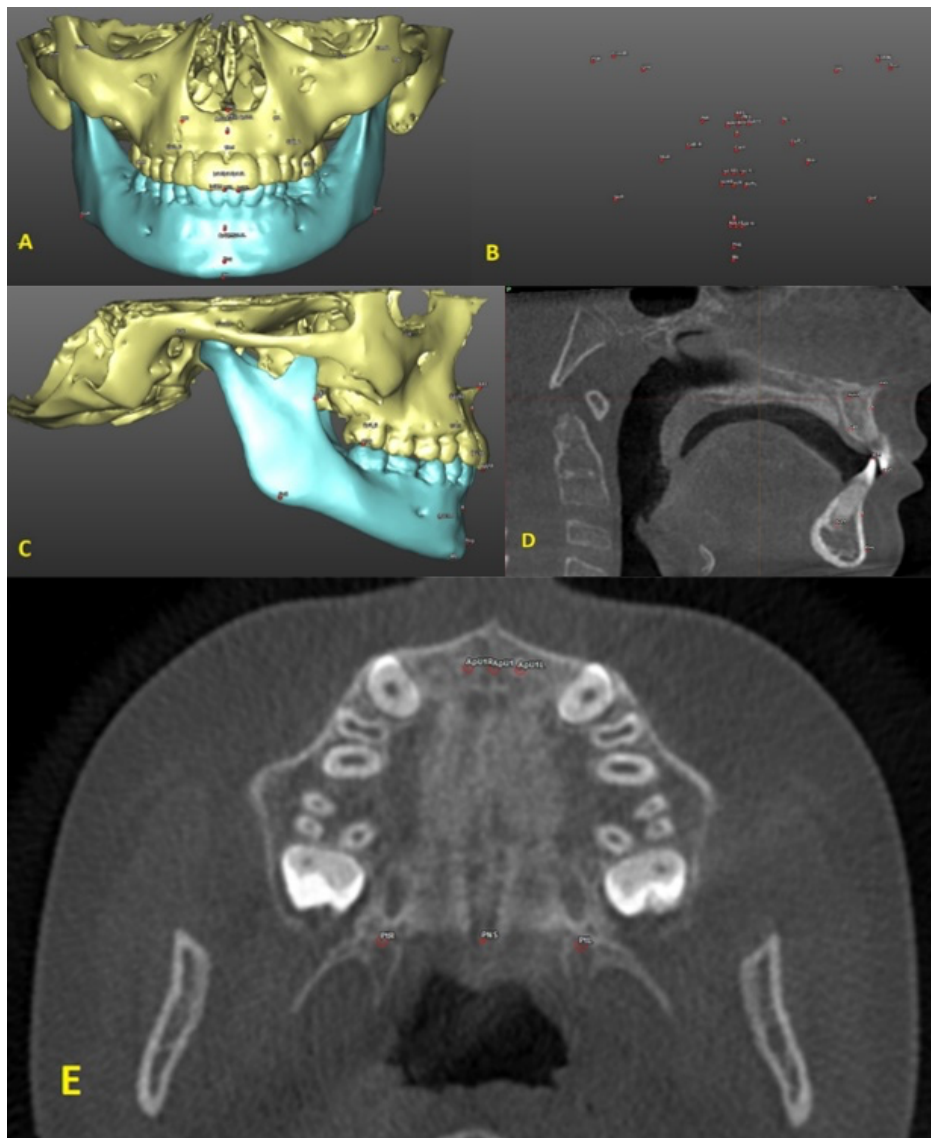
Proposed 3D cephalometric analysis based on medium FOV CBCT scans may be effectively used for the pediatric patients aged 7-12 years old, and such diagnostic approach fully corresponds with the generally accepted recommendations for effective doze minimization among orthodontic pediatric patients. Skeletal and dental cephalometric parameters were established for children 7-12 years old based on 25 CBCT data sets, which considering repeatability of obtained results registered by the two independent investigators may be categorized as a reference set of normality.

## Declaration of interest

The authors report no conflict of interest, and the article was not funded or supported by any research grant.

Landmark Name	Description
<b>Cranium</b>	
Porion L/R (PoL/PoR)	the most superior point on the bony external auditory meatus
Orbitale L/R (OrL/OrR)	the most inferior anterior point on the orbit's margin
<b>Midface &amp; Maxilla</b>	
Anterior nasal spine (ANS)	the most anterior midpoint of the anterior nasal spine of the maxilla
Posterior nasal spine (PNS)	the most posterior midpoint of the posterior nasal spine of the palatine bone
Pterygomaxillary L/R (PtL/PtR)	a bilateral, inverted teardrop shaped radiolucency, whose anterior border represents the posterior inferior surfaces of the greater palatine canals
Subspinale A-point (A)	the point of maximum concavity on the midline on the anterior surface of the maxilla
CpB L/R (CpBL/ CpBR)	the point on the palatal cortical bone plate at the level of furcation of the first upper molar and its projection of the resistance center
Incisal canal (CanI)	the most anterior midpoint of the incisal canal in the midsagittal plane
<b>Mandible</b>	
Supramentale B-Point (B)	the point of maximum concavity on the midline of the mandibular symphysis
Pogonion (Pog)	the most anterior midpoint of the chin in the midsagittal plane
Menton (Me)	the most inferior midpoint of the chin on the outline of the mandibular symphysis
Gonion L/R (GoL/GoR)	the most inferior point on angle of mandible
Condylion L/R (CondL/CondR)	the most posterior superior point of the mandibular condyle
<b>Dentoalveolar</b>	
Incision inferior IsL1 L/R (IsL1L/ IsL1R)	the most occlusal point of the lower incisor
Incision superior IsU1 L/R (IsU1L/ IsU1R)	the most occlusal point of the upper incisor
IsL1	point as midpoint of IsL1L and point IsL1R
IsU1	point as midpoint of IsU1L and point IsU1R
ApL1 L/R (ApL1L/ApL1R)	the tip of the root of the lower incisor
ApU1 L/R (ApU1L/ ApU1R)	the tip of the root of the upper incisor
ApL1	point as midpoint of ApL1L and point ApL1R
ApU1	point as midpoint of ApU1L and point ApU1R
Molars L/R (MoL/MoR)	the overbiting point of the first molars (if preset) or the distal tip of the first molar in the jaw of interest

**Table 1.** Definition of landmarks used in 3D DVB cephalometric analysis (L/R: Left/Right).

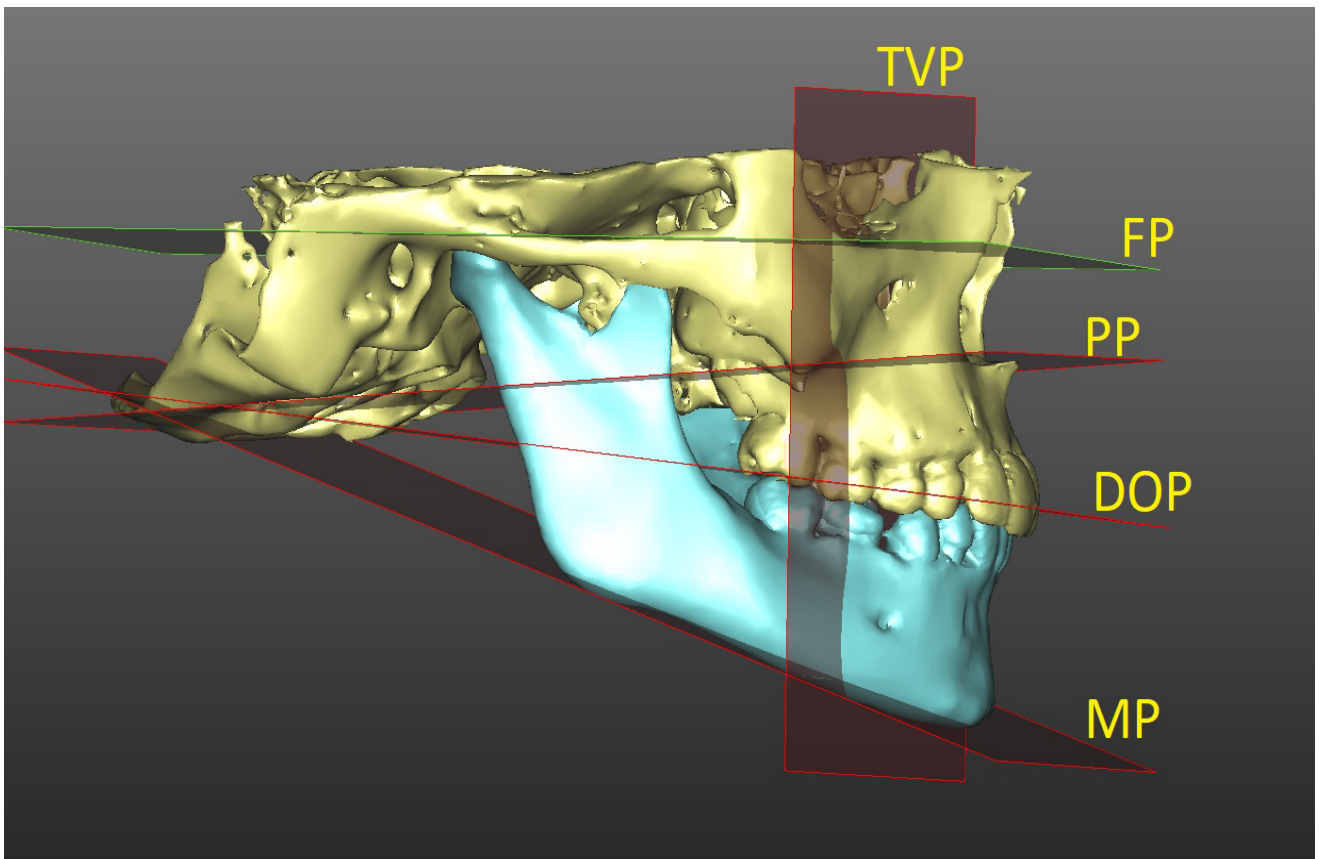


**Figure 1.** Cephalometric landmarks. A, B – front view – illustration of the set of 33 landmarks identified by the researcher on the 3D virtual model. C - right view – in the case of bilateral landmarks, only right landmarks is illustrated. D, E – all landmarks rectified on the most appropriate CT slice in the sagittal (D – control of Can1, ANS, A, B and Pog points), frontal and axial (E – control of PtL and PtR points) views.

Plane Name	Description
Frankfurt Plane (FP)	plane defined by point PoL, point PoR and point OrR
Dental Occlusal Plane (DOP)	plane defined by point MoL, point MoR and point IsL1
Mandibular Plane (MP)	plane defined by point GoL, point GoR and point Me
Palatal Plane (PP)	plane defined by point ANS, point PtL and point PtR
True Vertical Plane (TVP)	plane defined by point OrR, point OrL and their perpendiculars to the Frankfurt plane

**Table 2.** Definition of planes formed by the anatomical landmarks included in the 3D DVB cephalometric analysis.





**Figure 2.** The reference planes. FP - horizontal Frankfurt Plane was passing through the Right and Left Porion points and point Right Orbitale. TVP - True Vertical Plane was passing through the Right and Left Orbitale points and perpendicular to the FP plane. PP - Palatal Plane was passing through the Right and Left Pterygomaxillary points and point ANS. DOP - Dental Occlusal Plane was passing through the Right and Left Molars points and point IsL1. MP - Mandibular Plane was passing through the Right and Left Gonion points and point Me.

Line Name	Description
AB	line between point A and point B
ANS – PNS	line between point ANS and point PNS
PNS – Me	line between point PNS and point Me
Me – Pt L/R	line between point Me and point Pt (L/R)
Me – Go L/R	line between point Me and point Go (L/R)
Go L/R – Cond L/R	line between point Go (L/R) and point Cond (L/R)
AO	perpendicular line from point B onto Dental Occlusal Plane
BO	perpendicular line from point B onto Dental Occlusal Plane
A – TVP	perpendicular line from point A onto True Vertical Plane
B – TVP	perpendicular line from point B onto True Vertical Plane
CpBL – CpBR Line16-26	line between point CpBL and point CpBR
U1	line between point ApU1 and point IsU1
L1	line Angle point ApL1 and point IsL1
Overbite	perpendicular line from point IsU1 onto Dental Occlusal Plane
Overjet	horizontal line from point IsU1 and point IsL1
Canl – Line16-26	perpendicular line from point Canl to Line16-26

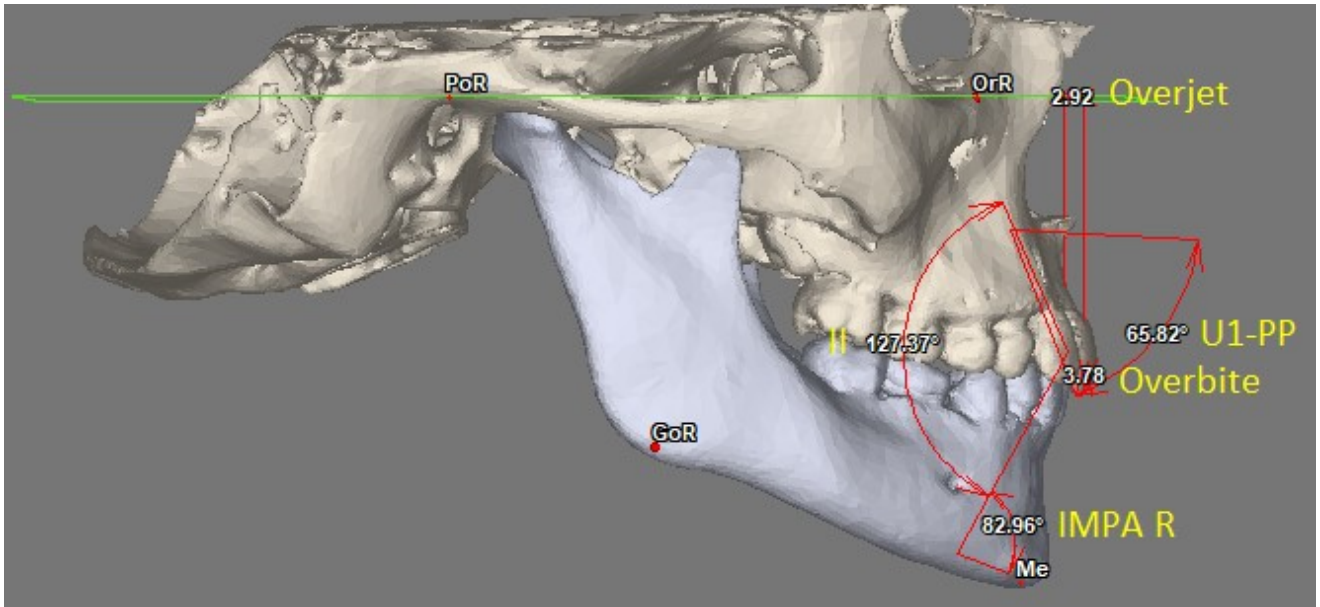
**Table 3.** Definition of lines formed by the anatomical landmarks included in the 3D DVB cephalometric analysis (L/R: Left/Right).

Angle Name	Description
Gonial Angle L/R Me – Go – Cond	left and right angle between line Me-GoL/R and line GoL/R-CondL/R
Mandibular Angle L/R	angle between line PoL/R-OrL/R (FH) and line Me-GoL/R
AB line angle AB – TVP	angle between line AB and True Vertical Plane
AB – MeGo L/R	angle between line AB and line MeGoL/R
IMPA L/R L1 – MeGo L/R	angle between line L1 and line MeGoL/R
U1-PP	angle between line U1 and Palatal Plane (PP)
Interincisal angle II	angle between line U1 and line L1
Palatal Angle FPPP	angle between Frankfurt Plane (FP) and Palatal Plane (PP)
Occlusal Plane inclination L/R	angle between line PoL/R-OrL/R (FH) and line IsL1-MoL/R

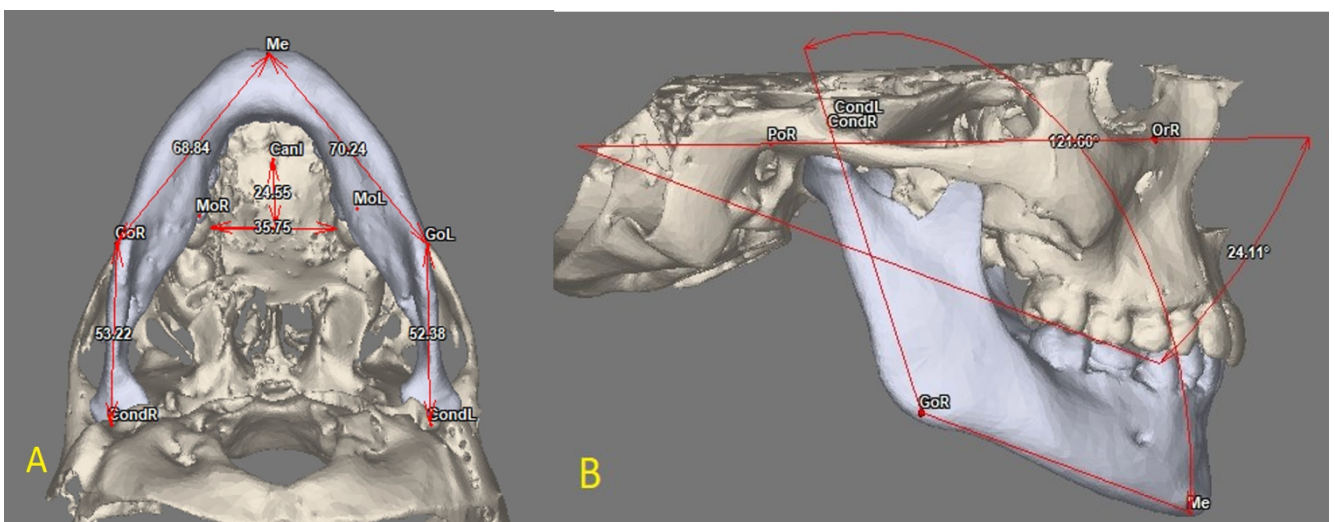
**Table 4.** Definition of angles included in the 3D DVB cephalometric analysis (L/R: Left/Right).

Dentoskeletal normal values				
Parameter	min value	max value	mean value	SD
II, °	124.68	135.52	130.58	±3.3
U1-PP, °	63.88	73.78	65.94	±3.07
IMPA (L/R), °	80.12	89.69	87.25	±2.45
Overjet, mm	1.93	3.36	2.64	±0.81
Overbite, mm	1.21	3.26	2.76	±0.52
Maxilla and Mandible normal values				
Gonial angle (L/R), °	116.36	128.22	124.81	±3.91
Mandibular angle (L/R), °	18.82	32.77	25.65	±5.45
Go-Me (L/R), mm	62.07	72.29	69.36	±2.87
Cond-Go (L/R), mm	44.56	53.22	49.4	±3.19
Canl-Line16-26, mm	22.90	28.30	26.67	±1.48
16-26 bone distance, mm	26.53	35.87	31.29	±1.46
Skeletal normal values				
AB-MeGo (L/R), °	69.44	78.86	71.21	±2.55
AB-TVP angle, °	5.56	12.84	9.04	±3.14
B-TVP, mm	4.37	6.29	5.49	±0.63
A-TVP, mm	10.38	13.25	11.71	±0.66
AOBO, mm	0.02	2.03	0.91	±0.61
Pt-Me (L/R), mm	62.70	73.75	67.33	±3.4
PNS-Me, mm	58.20	66.12	62.16	±2.21
ANS-Me, mm	50.11	59.82	55.9	±3.46
Palatal Angle, °	0.48	9.41	3.69	±2.55
Occlusal Plan inclination (L/R), °	1.44	13.97	8.24	±3.56

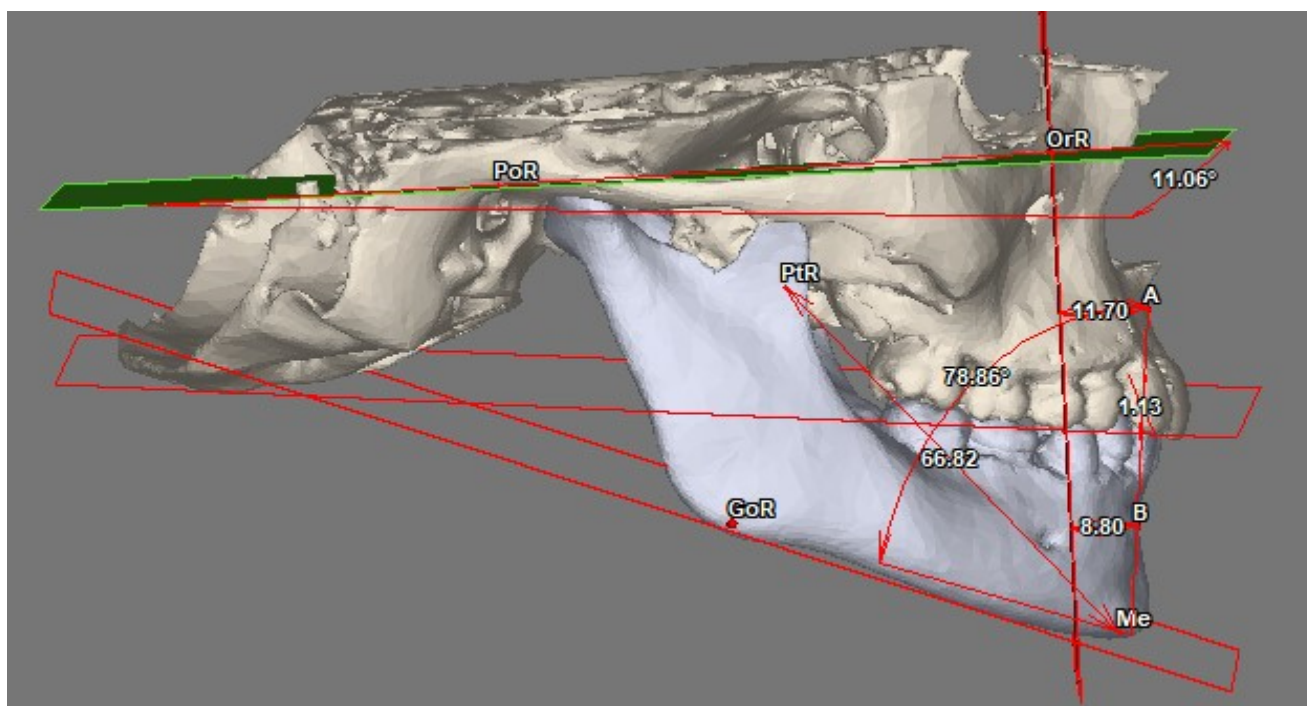
**Table 5.** Mean values per each measured parameter and SDs obtained during 3D DVB cephalometric analysis for Ukrainian children 7-12 years old (L/R: Left/Right).



**Figure 3.** Dentoskeletal factors: upper incisors to palatal plane (U1-PP), lower incisors to mandibular plane (IMPA L/R), interincisal angle (II), overbite, and overjet are represented.



**Figure 4.** Maxilla and Mandible factors: A – mandibular ramus length (left and right sides separately), mandibular body length (left and right sides separately), palatal width, palatal length, B – gonial angle, mandibular angle.



**Figure 5.** Certain skeletal vertical and anteroposterior measurements: Palatal Angle, Interjaw relations (angles AB-MeGoR and linear parameters A-TVP, B-TVP, Wits, PtR-Me).

Parameter	Boys (n = 10) Mean (SD)	Girls (n = 15) Mean (SD)	Overall (n = 25) Mean (SD)
<b>Interincisal angles</b>			
II L, °	131.45 (±1.94)	129.80 (±1.82)	130.37 (±3.05)
II R, °	132.76 (±2.78)	129.41 (±3.12)	130.79 (±3.54)
<b>Upper incisors inclination</b>			
U1 L -PP, °	65.19 (±2.83)	67.10 (±3.07)	66.04 (±3.17)
U1 R -PP, °	65.53 (±2.99)	66.36 (±3.87)	65.84 (±3.05)
<b>Lower incisors inclination</b>			
IMPA L, °	85.70 (±2.24)	87.99 (±3.06)	86.95 (±2.25)
IMPA R, °	85.98 (±1.47)	88.10 (±2.31)	87.56 (±2.05)
<b>Interincisal overlap</b>			
Overjet, mm	2.78 (±0.67)	2.66 (±0.30)	2.64 (±0.81)
Overbite, mm	2.48 (±0.83)	2.88 (±0.47)	2.76 (±0.82)
<b>Mandibular angles – growth pattern prediction</b>			
Gonial angle L, °	123.81 (±3.76)	124.86 (±3.65)	124.21 (±3.83)
Gonial angle R, °	124.50 (±4.35)	126.84 (±2.81)	125.41 (±3.99)
Mandibular angle L, °	23.77(±5.36)	27.41(±5.55)	25.82 (±5.05)



Mandibular angle R, °	24.25 (±6.02)	26.62(±5.81)	25.48 (±5.85)
<b>Maxillary angle – growth pattern prediction</b>			
Palatal Angle, °	3.71 (±2.51)	3.68 (±2.58)	3.69 (±2.55)
<b>Mandibular body length – dimensions and symmetry</b>			
Go-Me L, mm	67.73 (±2.42)	69.68 (±3.13)	68.56 (±3.02)
Go-Me R, mm	69.87 (±2.11)	71.29 (±2.86)	70.16 (±2.69)
<b>Mandibular ramus length – dimensions and symmetry</b>			
Cond-Go L, mm	49.05 (±2.62)	49.33 (±3.87)	49.16 (±3.02)
Cond-Go R, mm	49.56 (±3.12)	49.71 (±3.92)	49.65 (±3.35)
<b>Maxilla length at the palate level – sagittal maxillary dimension</b>			
Canl-Line16-26, mm	26.17 (±1.26)	26.91 (±1.83)	26.67 (±1.48)
<b>Maxilla width at the palate level – transverse maxillary dimension</b>			
16-26 bone distance, mm	30.80 (±0.67)	32.51 (±1.58)	31.29 (±1.46)
<b>Angles between maxilla and mandible – vertical ratio</b>			
AB-MeGo L, °	71.95 (±3.19)	71.69 (±1.84)	71.86 (±2.43)
AB-MeGo R, °	70.93 (±2.75)	70.41 (±3.22)	70.56 (±2.62)
<b>Anteroposterior jaw relationship – sagittal ratio</b>			
AB-TVP angle, °	10.62 (±2.26)	7.96 (±3.26)	9.04 (±3.14)
AOBO, mm	1.27 (±0.64)	0.8 (±0.35)	0.91 (±0.61)
<b>Anteroposterior maxillary position</b>			
A-TVP, mm	11.66 (±0.59)	11.9 (±0.95)	11.71 (±0.66)
<b>Anteroposterior mandibular position</b>			
B-TVP, mm	5.05 (±0.62)	5.63 (±0.56)	5.49 (±0.63)
<b>Facial proportions and symmetry – lower third of facial height</b>			
ANS-Me, mm	54.38 (±2.72)	56.61 (±3.37)	55.9 (±3.46)
PNS-Me, mm	61.84 (±3.09)	62.71 (±1.36)	62.16 (±2.21)
Pt-Me L, mm	67.96 (±4.07)	66.12 (±3.22)	67.16 (±3.49)
Pt-Me R, mm	68.13 (±3.31)	67.25 (±3.59)	67.49 (±3.34)
<b>Occlusal plane angle</b>			
Occlusal Plan inclination L, °	7.59 (±3.89)	8.15 (±3.68)	8.10 (±3.79)
Occlusal Plan inclination R, °	8.07 (±3.25)	8.63 (±3.53)	8.37 (±3.38)

**Table 6.** Descriptive statistics for measurements obtained during 3D DVB cephalometric analysis (left and right sides separately) for Ukrainian children 7-12 years old (boys and girls separately).

## References

1. Durão AR, Pittayapat P, Rockenbach MI, Olszewski R, Ng S, Ferreira AP, Jacobs R. Validity of 2D lateral cephalometry in orthodontics: a systematic review. *Prog Orthod.* 2013;14(1):1-1.
2. Kotula J, Kuc AE, Lis J, Kawala B, Sarul M. New Sagittal and Vertical Cephalometric Analysis Methods: A Systematic Review. *Diagnostics.* 2022;12(7):1723.
3. Pittayapat P, Limchaichana-Bolstad N, Willems G, Jacobs R. Three-dimensional cephalometric analysis in orthodontics: a systematic review. *Orthod Craniofac Res.* 2014;17(2):69-91.
4. Lo Giudice A, Ronsivalle V, Zappalà G, Leonardi R, Campagna P, Isola G, Palazzo G. The Evolution of the Cephalometric Superimposition Techniques from the Beginning to the Digital Era: A Brief Descriptive Review. *Int J Dent.* 2021;2021:6677133.
5. Dakhno L, Vyshemyrska T, Burlakov P, Storozhenko K., Flis P. Assessment of the feasibility of using cone-beam computed tomography in children for diagnostics, 3D cephalometry and planning orthodontic treatment (review). *Georgian Med News.* 2022;323:54-60.
6. Maspero C, Abate A, Bellincioni F, Cavagnetto D, Lanteri V, Costa A, Farronato M. Comparison of a tridimensional cephalometric analysis performed on 3T-MRI compared with CBCT: A pilot study in adults. *Prog Orthod.* 2019;20(1):1-0.
7. Durão AR, Alqerban A, Ferreira AP, Jacobs R. Influence of lateral cephalometric radiography in orthodontic diagnosis and treatment planning. *Angle Orthod.* 2015;85(2):206-10.
8. Devereux L, Moles D, Cunningham SJ, McKnight M. How important are lateral cephalometric radiographs in orthodontic treatment planning?. *Am J Orthod Dentofacial Orthop.* 2011;139(2):e175-81.
9. De Grauwe A, Ayaz I, Shujaat S, Dimitrov S, Gbadegbegnon L, Vande Vannet B, Jacobs R. CBCT in orthodontics: a systematic review on justification of CBCT in a paediatric population prior to orthodontic treatment. *Eur J Orthod.* 2019;41(4):381-9.
10. Akleyin E, Goncharuk-Khomyn M. Cone Beamed Computerized Dental Tomography in Dentistry. *J Int Med Res.* 2019;12(4):1613-7.
11. Colceriu-Şimon IM, Băciuţ M, Ştiufiuc RI, Aghiorghiese A, Ţărmure V, Lenghel M, Hedeşiu M, Băciuţ G. Clinical indications and radiation doses of cone beam computed tomography in orthodontics. *Med Pharm Rep.* 2019;92(4):346.
12. Güneş M, Fidancıoğlu YD. Reasons for Use of Cone Beam Computed Tomography in Pediatric Dentistry. *J Int Med Res.* 2022;15(4):1591-6.
13. Oenning AC, Jacobs R, Pauwels R, Stratis A, Hedeşiu M, Salmon B, DIMITRA Research Group, <http://www.dimitra.be>. Cone-beam CT in paediatric dentistry: DIMITRA project position statement. *Pediatr Radiol.* 2018;48:308-16.
14. Oenning AC, Pauwels R, Stratis A, De Faria Vasconcelos K, Tijksens E, De Grauwe A, Jacobs R, Salmon B. Halve the dose while maintaining image quality in paediatric Cone Beam CT. *Sci Rep.* 2019;9(1):5521.
15. Kapila SD, Nervina JM. CBCT in orthodontics: assessment of treatment outcomes and indications for its use. *Dentomaxillofac Radiol.* 2015;44(1):20140282.
16. Raj G, Raj M, Saigo L. Accuracy of conventional versus cone-beam CT-synthesised lateral cephalograms for cephalometric analysis: A systematic review. *J Orthod.* 2023;14653125231178038.
17. Baumann E, Bornstein MM, Dalstra M, Verna C, Dagassan-Berndt DC. Image quality assessment of three cone beam computed tomography scanners—an analysis of the visibility of anatomical landmarks. *Eur J Orthod.* 2022;44(5):513-21.
18. Farronato M, Baselli G, Baldini B, Favia G, Tartaglia GM. 3D cephalometric normality range: auto contractive maps (ACM) analysis in selected caucasian skeletal class I age groups. *Bioengineering.* 2022;9(5):216.
19. Goncharuk-Khomyn M, Akleyin E, Zhulkevych I, Nahirnyi Y, Brekhlichuk P, Mochalov Y, Melnychuk I, Horzov L, Stoika O. Correspondence between Dental and Skeletal Maturity Parameters Among Patients with Different Sagittal Relationships at the end of Puberty Period. *J Int Med Res.* 2020;13(1):223-8.
20. Alsubai S. A critical review on the 3D cephalometric analysis using machine learning. *Computers.* 2022;11(11):154.
21. Pinheiro M, Ma X, Fagan MJ, McIntyre GT, Lin P, Sivamurthy G, Mossey PA. A 3D cephalometric protocol for the accurate quantification of the craniofacial symmetry and facial growth. *J Biol Eng.* 2019;13(1):1-1.
22. Farronato G, Garagiola U, Dominici A, Periti G, de Nardi S, Carletti V, Farronato D. "Ten-point" 3D cephalometric analysis using low-dosage cone beam computed tomography. *Prog Orthod.* 2010;11(1):2-12.
23. Theodorakou C, Walker A, Horner K, Pauwels R, Bogaerts R, Jacobs Dds R, SEDENTEXCT Project Consortium. Estimation of paediatric organ and effective doses from dental cone beam CT using anthropomorphic phantoms. *Br J Radiol.* 2012;85(1010):153-60.
24. Abdelkarim A. Cone-beam computed tomography in orthodontics. *Dent J.* 2019;7(3):89.
25. Farronato M, Maspero C, Abate A, Grippaudo C, Connelly ST, Tartaglia GM. 3D cephalometry on reduced FOV CBCT: Skeletal class assessment through AF-BF on Frankfurt plane—Validity and reliability through comparison with 2D measurements. *Eur Radiol.* 2020;30:6295-302.
26. Kissel P, Mah JK, Bumann A. Modern 3D cephalometry in pediatric orthodontics—downsizing the FOV and development of a new 3D cephalometric analysis within a minimized large FOV for dose reduction. *Clin Oral Investig.* 2021;25:4651-70.
27. Van Acker JW, Pauwels NS, Cauwels RG, Rajasekharan S. Outcomes of different radioprotective precautions in children undergoing dental radiography: a systematic review. *Eur Arch Paediatr Dent.* 2020;21:463-508.
28. Van Bunningen RH, Dijkstra PU, Dieters A, van der Meer WJ, Kuijpers-Jagtman AM, Ren Y. Precision of orthodontic cephalometric measurements on ultra low dose-low dose CBCT reconstructed cephalograms. *Clin Oral Investig.* 26(2): 1543–1550.
29. de Queiroz Tavares Borges Mesquita G, Vieira WA, Vidigal MT, Travençolo BA, Beaini TL, Spin-Neto R, Paranhos LR, de Brito Júnior RB. Artificial Intelligence for Detecting Cephalometric Landmarks: A Systematic Review and Meta-analysis. *J Digit Imaging.* 2023;36(3):1158-79.
30. Guinot-Barona C, Alonso Pérez-Barquero J, Galán López L, Barmak AB, Att W, Kojs JC, Revilla-León M. Cephalometric analysis performance discrepancy between orthodontists and an artificial intelligence model using lateral cephalometric radiographs. *J Esthet Restor Dent.* 2023;online ahead of print.
31. Alshammery DA, Almubarak S, Hezaim AB, Alkhunein R, Pani SC, Mossadomi H. Cephalometric norms of skeletal relationship among populations in selected Arab countries: A systematic review and meta-analysis. *Saudi J Oral Sci.* 2016;3(2):69-74.
32. Girhe V, Borle R, Datey P, Shirivastav S, Bhola N. Cephalometric norms for the north Indian population: A systematic review. *Natl J Maxillofac Surg.* 2022;13(2):172.