


Peculiarities of Morphology of Large Salivary Glands in Experimental Animals Under Different Conditions of Motor Activity of Their Mothers During Pregnancy


Yuliia Slynko¹, Iryna Sokolova², Halyna Gubina-Vakulik³, Anatoly Potapchuk⁴, Iryna Korneyko⁵


¹Department of Pediatric Dentistry, Pediatric Oral Surgery and Implantology, Kharkiv National Medical University, Kharkiv, Ukraine. 0000-0002-9718-5202

²Department of Dentistry, Kharkiv National Medical University, Kharkiv, Ukraine. 0000-0002-2339-4909

³Central Research Laboratory, Pathomorphology Division, Kharkiv National Medical University, Kharkiv, Ukraine.

0000-0003-3816-8530

⁴Department of Stomatology, Uzhhorod National University, Faculty of Dentistry, Uzhhorod, Ukraine. 0000-0001-9857-1407

⁵Department of Foreign Languages, Kharkiv National Medical University, Kharkiv, Ukraine. 0000-0003-3581-4138

Author to whom correspondence should be addressed: Dr. Irina Sokolova, Department of Dentistry, Kharkiv National Medical University, Kharkiv, Ukraine. Phone: +38 050 3433988. E-mail: sokdentirina@gmail.com.

Academic Editors: Alessandro Leite Cavalcanti and Wilton Wilney Nascimento Padilha

Received: 03 October 2018 / Accepted: 20 January 2019 / Published: 06 February 2019

Abstract

Objective: To evaluate of the microstructure of the salivary glands of experimental animals born from of females rats, who were subjected to different modes of motor activity during the pregnancy: limited and compensated by regular moderate training. **Material and Methods:** The sample was composed 84 three-month-old descendants of Wistar rats which were divided into three groups: G1 (n = 27): posterity of female rats, who during gestation were in standard conditions; G2 (n = 25): posterity of female rats, who during pregnancy were in hypokinesia conditions; G3 (n = 32): which stayed in conditions of hypokinesia, but had running load in running wheel regularly 5 times a week. **Results:** In adult descendants of G2, morphological structure of the submandibular salivary glands was characterized by decrease size and number of glandular cells; reduction of their cytoplasm; increase in heterochromatin amount and decrease in the intensity of fuchsinophilia. Microstructure of the submandibular salivary glands of the offspring of G3 indicates positive effect of regular short-term physical activity on the morphofunctional state of the specified glands. An increased number of tissue basophils in their stroma is also in favor of greater functional activity of salivary glands. **Conclusion:** This study indicates deceleration of the metabolic processes in salivary glands of animals under the influence of hypokinesia of their mothers during pregnancy. It was also confirmed that regular physical activity completely eliminates the negative effect of mothers' hypokinesia on morphology the salivary glands of the descendant.

Keywords: Animal Experimentation; Salivary Glands; Morphological and Microscopic Findings.

Introduction

Mouth fluid is a constant and necessary component ensuring the proper functioning of organs and tissues of the human oral cavity. Absolutely all processes, both physiological and pathological, occur in the oral cavity in the conditions of its constant presence. On the other hand, it is the oral fluid that is the first biological environment actively affected by any negative factors, especially external ones [1-3]. Among the various functions of the oral fluid, protective function has an exceptional value for maintaining the normal functioning of the organs and tissues of the oral cavity [4-7].

The salivary glands produce a unique component of the oral fluid, mucin, which, covering the oral mucosa with a thin layer, provides an adequate level of moisture and prevents or reduces the risk of traumatic damage. Decrease of functional activity of the salivary glands has negative consequences, which leads to deterioration of cleansing of the organs of the oral cavity and, consequently, increase in microbial contamination, even oral dysbiosis. The latter, in turn, is a powerful impetus for development of the most common dental diseases, including periodontal tissue diseases [8].

In the dentistry literature, the issue of the morphofunctional state of the large and small salivary glands in acute odontogenic inflammatory diseases of the soft tissues and jaws, chronic inflammatory diseases of the salivary glands, fractures of the mandible, galvanic pathology is well covered [9-11]. The information on the condition of the salivary glands and the specifics of their morphofunctional state under the influence of negative factors of the environment or modern lifestyle, including sedentary lifestyle or hypokinesia, is poor [12-16], which makes the research relevant.

Therefore, the objective of the present study was to determine the influence of different regimes of motor activity of female rats during pregnancy on the microstructure of the salivary glands of their offspring.

Material and Methods

The experimental study consisted of the following steps: selection and adaptation of the females Wistar rats to the experimental conditions, male planting, distribution of experimental animals by groups depending on the conditions of stay (standard according to GLP requirements, hypokinesia - by keeping in cages with the reduced floor area, hypokinesia with additional daily moderate physical activity by transplanting into a "running wheel" for 15 minutes), carrying of pregnancy and getting offspring. After delivery, all females rats and their offspring (84 individuals: G1 (n = 27): posterity of female rats, who during gestation were in standard conditions; G2 (n = 25): posterity of female rats, who during pregnancy were in hypokinesia conditions; G3 (n = 32): which stayed in conditions of hypokinesia, but had running load in "running wheel" regularly 5 times a week) were transferred to standard conditions of animal management in the experimental biological clinic of the university. The last stage involved sacrificing the resulting offspring (at 3 months of

age) by euthanizing animals with overdose of thiopental sodium (20 mg/kg) with subsequent decapitation.

Immediately after the experiment was completed, morphological studies were performed, specimens for which were biopsies of large submandibular salivary glands of the offspring of female rats. The choice of these salivary glands was due to the fact that it is the submandibular gland that accounts for 70% of the volume of saliva produced.

The obtained material was prepared in the traditional way: first, fixation in 10% solution of neutral formalin, then, alternate immersion in spirits of increasing strength and trichloroacetic acid for decalcification. Subsequently, the material was subjected to the celloidin-paraffin treatment, after which sections of 5-6 microns thickness were stained with hematoxylin and eosin, picrofuchsin according to Van Gieson, acid-Schiff (PAS) reaction, gallocyanine by Einarsson and investigated microscopically [18]. Further study of histological structures was performed using a microscope Axiostar plus (Carl Zeiss, Gottingen, Germany).

Ethical Aspects

This study was conducted in accordance with the recommendations of the Helsinki Convention for the Protection of Vertebrate Animals Used for Experimental and Other Scientific Purposes, Practical Recommendations for Management of Laboratory Animals and Working with Them [17] and the positive opinion of the local bioethics committee of Kharkiv National Medical University was received.

Results

The histological structure of the large submandibular glands of the offspring of female rats, which during the pregnancy were subjected to different motor activity, had common features irrespective of the conditions of management, namely: outside, the glands had a connective tissue capsule, with trabecular membranes dividing the glands into the lobes extending away from it. The connective tissue of the interstices was infiltrated with blood vessels, nerve endings, excretory ducts. The stroma of the glands was formed by a connective tissue located inside the lobes and in the zone of interlobular trabeculae, and the parenchyma was infiltrated by a system of excretory ducts (protein and mixed acinus) and glandular epithelium, the main structural unit of which was glandulocyte, a cell from which the secretory function begins. The above corresponds to the normal structure of the salivary glands.

However, the analysis of the microspecimens demonstrated certain features in the morphological structure of the submandibular glands, depending on the motor regimen of their mothers during pregnancy.

The morphological aspects of the salivary glands in the control group (Group 1) demonstrated a small volume of stroma, as opposed to a well-expressed parenchyma. Thus, the vast majority of glandulocytes were high, with light and granular cytoplasm. The nuclei of glandulocytes,

often flattened, were located in the basal portion of the secretory cells. The glanulocytes were crowded in patches and resemble islets. Acini were densely placed, their finite portions were round-oval (Figure 1).

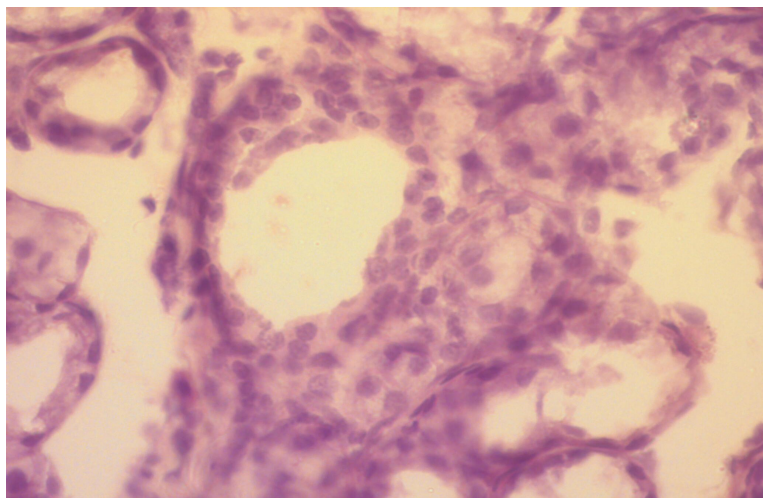


Figure 1. Well-expressed parenchyma and moderate content of neutral glycoproteins in the cytoplasm of glandular cells of the submandibular salivary gland of offspring from group 1. Staining: Hematoxylin-eosin. X400.

The microstructure of the submandibular salivary glands of the offspring of female rats, which were simulated the conditions of hypokinesia (group 2), was characterized by a markedly lower parenchyma volume compared with the control group. Glanulocytes were noticeably less in number in both the stroma itself and the perimeter of the acini, the size of which was also diminished. The latter is also due to the smaller size of glanulocytes. Reduction in the volume of the cytoplasm of glanulocytes and the darker color of their nuclei due to the increased amount of inactive portion of chromatin – heterochromatin was notable. Finally, the intensity of fuchsinophilia in Schiff reaction in the tissues of the salivary glands of the offspring of group 2 females was less than the control group (Figure 2).

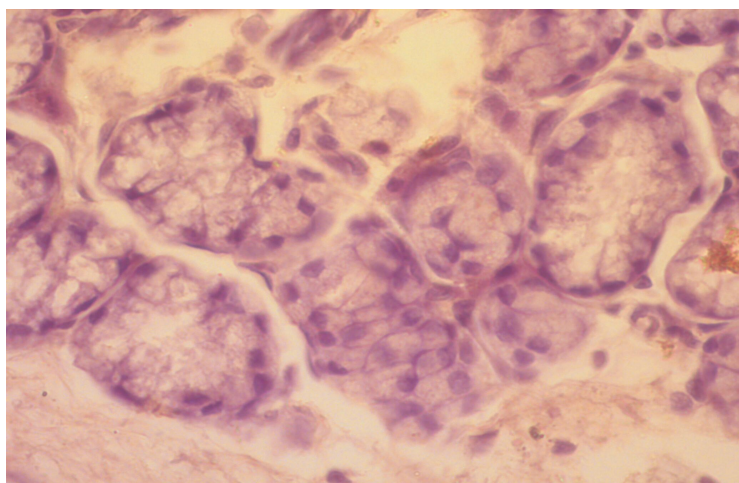


Figure 2. Reduced number of glanulocytes, less pronounced fuchsinophilia of secretion of the submandibular salivary glands of offspring of animals of group 2. Staining: Hematoxylin-eosin. X400.

Analysis of microspecimens of the submandibular salivary glands of the offspring of female rats, in which the condition of hypokinesia during the pregnancy was compensated by regular daily moderate exercise in the form of running in the "running wheel" for 15 minutes (group 3), demonstrated the following changes. Glanulocytes of the salivary gland were high with large nuclei located in the basal portion of the cells. Their cytoplasm was filled with volumetric, more fuchsinophilic, than in group 2, secretion (Figure 3).

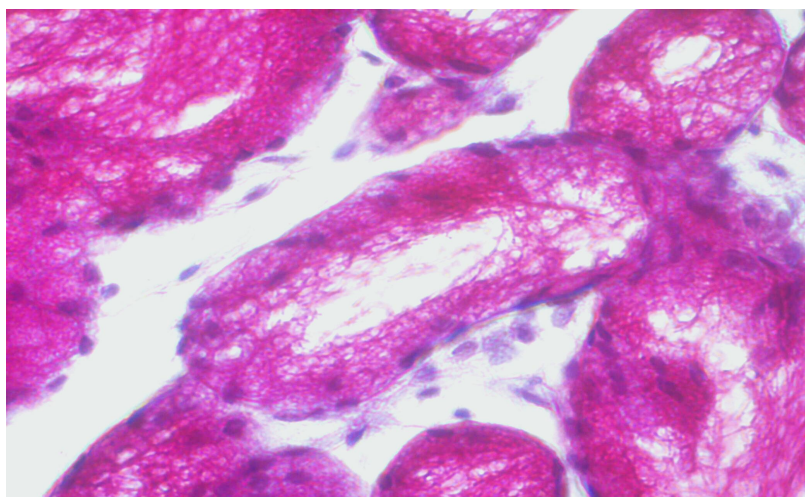


Figure 3. Expressed fuchsinophilia of the secretion of the submandibular salivary gland in group 3. Staining: Schiff reaction. X400.

Acini were also considerably larger than in the offspring of the females, which were pregnant in conditions of limited motor activity. In the stroma of the salivary gland of group 3, in comparison with group 2, increase in the number of glandulocyte clusters in the form of islets and the number of tissue basophils were recorded (Figure 4).

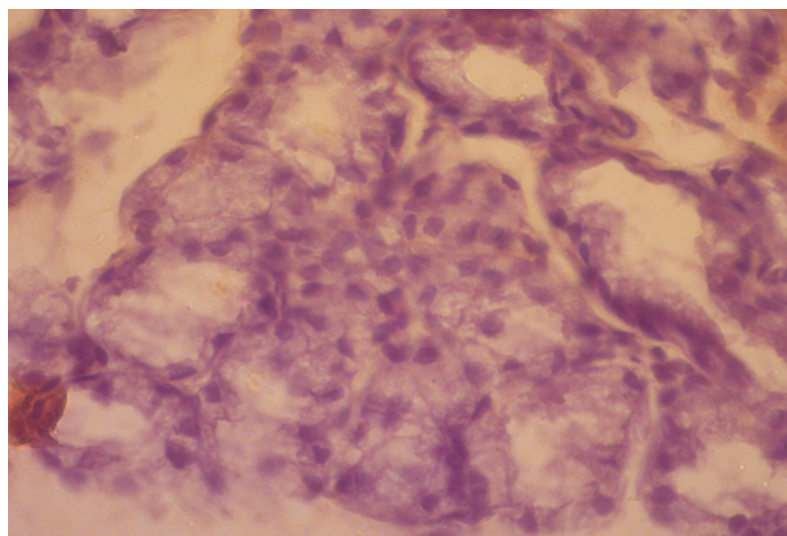


Figure 4. Large island of glanulocytes in the submandibular salivary gland in group 3. Staining: Hematoxylin-eosin. X400.

Discussion

The histological findings of this study corresponded to the normal structure of the salivary glands [18]. The morphofunctional condition of the salivary glands tissues is directly connected with production of the relevant volume of saliva [2], the ability to realize numerous functions of the glands, among which the protective plays an especially important role [3,10,11]. The proper functional activity of the submandibular salivary glands of the female rats offspring is confirmed by identification of the so-called islets of the glandular cells, glanulocytes, which are the source of the potential reserve of activation of the gland acini activity and the presence of a volumetric granular cytoplasm in glandular cells, which is directly associated with "stocks" of protein rich saliva and which will be brought to the oral cavity as necessary.

The morphofunctional state of the submandibular salivary glands of experimental animals born from the mothers, who were during pregnancy in a state of limited motor activity, can be characterized as suppressed. This is confirmed by the diminished size and number of glandular cells, both in the stroma of the gland, and in the ducts of the acini; reduction of their cytoplasm; increase in heterochromatin amount, which is an inactive structure, and decrease in the intensity of fuchsinophilia at Schiff reaction, which may indirectly indicate metabolic processes deceleration.

Approximation of the microstructure of the parenchyma of the submandibular salivary glands of the offspring of females, in which the state of hypokinesia was compensated by moderate physical activity, when compared to the control animals, indicates positive effect of regular short-term physical activity on the morphofunctional state of the specified glands. An increased number of tissue basophils in their stroma is also in favor of greater functional activity of salivary glands.

Conclusion

Changes in the physical and chemical properties of the oral fluid, the rate of its secretion depends not only on the age, nervous excitement, food stimulus and the presence of concomitant diseases. Oral fluid properties can also respond to such an external factor as lifestyle. Thus, under the influence of limited motor activity of experimental female rats during pregnancy on their offspring, morphofunctional conditions for decreasing secretory activity develop, which may lead to deterioration of the purification of the oral cavity organs and, as a consequence, development of numerous dental diseases, including those of periodontal tissues. In contrast, regular short-term moderate exercise of a pregnant female leading a sedentary lifestyle, in the form of a 15-minute daily running in the wheel, resulted in complete restoration of the morphofunctional state of the salivary gland with an increase in its functional potential.

Financial Support: None.

Conflict of Interest: The authors declare no conflicts of interest.

References

- [1] Afanasyev VV, Yaglova NV, Khubutiya BN, Krasnikova TV, Zoryan YeV, Khripunkov VA. Morfofunktsionalnyye izmeneniya malykh slyunnykh zhelez u bolnykh s razlichnymi formami sialadenoza. *Rossiyskiy stomatologicheskiy Zhurnal* 2012; 5:7-10. [In Ukrainian]
- [2] Shipsky AV. Xerostomia, hyposalivation and disorders of the excretory evacuation function of the salivary glands (review). *Parodontology* 2002; 3:45-50.
- [3] Carpenter GH. The secretion, components and properties of saliva. *Annu Rev Food Sci Technol* 2013; 4:267-76. <https://doi.org/10.1146/annurev-food-030212-182700>
- [4] Woof JV, Kerr MA. The function of immunoglobulin A in immunity. *J Pathol* 2006; 208(2):270-82. <https://doi.org/10.1002/path.1877>
- [5] Soares RV, Lin T, Siqueira CC, Bruno LS, Li X. Salivary micelles identification of complexes containing MG2, sIgA, lactoferrin, amylase, glycosylated proline-rich protein and lysozyme. *Arch Oral Biol* 2004; 49(5):337-43. <https://doi.org/10.1016/j.archoralbio.2003.11.007>
- [6] Ebersole JL, Dawson D 3rd, Emecen-Huja P, Nagarajan R, Howard K, Grady ME, et al. The periodontal war: Microbes and immunity. *Periodontol* 2000 2017; 75(1):52-115. <https://doi.org/10.1111/prd.12222>
- [7] Leito TD, Ligtenberg AJM, Nazmi K. Identification of salivary components that include transition of hyphae to yeast in *Candida albicans*. *FEMS Yeast Res* 2009; 9(7):1102-10. <https://doi.org/10.1111/j.1567-1364.2009.00575.x>
- [8] Vavilova TP, Shtrunova LN, Shishkin SV, Shishkin VS. The use of mixed saliva laboratory values for evaluation of periodontal tissue condition. *Russian J Dent* 2010; 1:10-12.
- [9] Sichkoriz HA, Minko LY. Changes in physical and chemical properties of oral fluid in patients with periodontal diseases in the settings of chronic hepatitis C during antiviral therapy. *Ukrainian Dental Almanach* 2016; 3(1):13-7.
- [10] Tymofieiev O, Viesova A. Secretion function of big and small salivary glands after the operation on extirpation parotid gland. *Modern Dent* 2011; 4(58):66-9. [In Ukrainian]
- [11] Tymofieiev O. Secretory function of large and small salivary glands at galvanism and galvanosis. *Modern Dent* 2013; 3(67):72-6. [In Ukrainian]
- [12] Antonova LK. Influence of hypokinesia on the state of health of teenage girls. *Ross Med Zhurn* 2003; 3:35-7.
- [13] Kachelayeva YV. Hypodynamia and human health. In the world of scientific discoveries 2010; 4(14):26-7.
- [14] Cavill N, Sonja Kahlmeier S, Racioppi F. Physical Activity and Health in Europe: Evidence for Action. - Copenhagen: World Health Organization; 2006. 55p.
- [15] Reedeker N, Van Der Mast RC, Giltay EJ, Van Duijn E, Roos RA. Hypokinesia in Huntington's disease co-occurs with cognitive and global dysfunctioning. *Mov Disord* 2010; 25(11):1612-8. <https://doi.org/10.1002/mds.23136>
- [16] Gubina-Vaculic G, Slynko Y, Sokolova I, Colousova N. Morphofunctional peculiarities of submandibular salivary gland of rats in conditions of experimental hypokinesia in their mothers' organisms. *World Med Biol* 2013; 2:26-8.
- [17] Kozhemiakin YM, Khromov OS, Filonenko MA, Sayfetdinova HA. Scientific and practical recommendations on the maintenance and handling of laboratory animals. Kyiv: Avicenna, 2002. 156p.
- [18] Kozak HI, Zapryvoda LP, Ostapenko OV, Stechenko LO, et al. Histology. Short Course: Textbook. Chaikovskiy YB (Editor). Vinnytsia: New Book; 2016. 336p.