

Wiadomości Lekarskie

Medical Advances

Official journal of the Polish Medical Association
Wiadomości Lekarskie has been published since 1928



Volume LXXVIII, Issue 4, APRIL 2025

ISSN 0043-5147

E-ISSN 2719-342X

Wiadomości Lekarskie

Medical Advances

Official journal of the Polish Medical Association
Wiadomości Lekarskie has been published since 1928



Volume LXXVIII, Issue 4, APRIL 2025



Memory of
dr Władysław
Biegański

Wiadomości Lekarskie Medical Advances is abstracted and indexed in:
PUBMED/MEDLINE, SCOPUS, EMBASE, INDEX COPERNICUS,
MINISTRY OF SCIENCE AND HIGHER EDUCATION, POLISH MEDICAL BIBLIOGRAPHY

Copyright: © ALUNA Publishing

Articles published on-line and available in open access are published under Creative Commons Attribution-Non Commercial-No Derivatives 4.0 International (CC BY-NC-ND 4.0) allowing to download articles and share them with others as long as they credit the authors and the publisher, but without permission to change them in any way or use them commercially.

Publisher:

ALUNA Publishing
29 Przesmyckiego st.,
05-510 Konstancin – Jeziorna, Poland
www.wydawnictwo-aluna.pl
www.wiadomoscilekarskie.pl
www.wiadlek.pl

Wiadomości Lekarskie

Medical Advances

Official journal of the Polish Medical Association
Wiadomości Lekarskie has been published since 1928



Editorial Team

Editor in-Chief:

Prof. Paweł Kalinski – Buffalo, USA

Honorary Editor in-Chief:

Prof. Władysław Pierzchała – Katowice, Poland

Deputy Editor in-Chief:

Prof. Waldemar Kostewicz – Warsaw, Poland
President Polish Medical Association

Statistical Editor:

Dr Lesia Rudenko – Konstancin-Jeziorna, Poland

Managing Editor:

Agnieszka Rosa – amarosa@wp.pl

International Editorial Office:

Nina Radchenko (editor) – n.radchenko@wydawnictwo-aluna.pl

International Editorial Board – in-Chief:

Marek Rudnicki

Chicago, USA

International Editorial Board – deputy in-Chief:

Aleksander Sieroń

Katowice, Poland

International Editorial Board – Members:

Stalbek M. Akhunbaev	Bishkek, Kyrgyzstan	Jerzy Robert Ładny	Białystok, Poland
Kris Bankiewicz	San Francisco, USA	Stella Nowicki	Memphis, USA
Christopher Bara	Hannover, Germany	Alfred Patyk	Gottingen, Germany
Krzysztof Bielecki	Warsaw, Poland	Palmira Petrova	Yakutsk, Russia
Zana Bumbuliene	Vilnius, Lithuania	Waldemar Priebe	Houston, USA
Stanislav Czudek	Ostrava, Czech Republic	Maria Siemionow	Chicago, USA
Mowafaq Muhammad Ghareeb	Baghdad, Iraq	Vladyslav Smiiianov	Sumy, Ukraine
Nataliya Gutorova	Kharkiv, Ukraine	Tomasz Szczepański	Katowice, Poland
Marek Hartleb	Katowice, Poland	Andrzej Witek	Katowice, Poland
Roman Jaeschke	Hamilton, Canada	Jerzy Woy-Wojciechowski	Warsaw, Poland
Andrzej Jakubowiak	Chicago, USA	Zbigniew Wszolek	Jacksonville, USA
Peter Konturek	Saalfeld, Germany	Vyacheslav Zhdan	Poltava, Ukraine
George Krol	New York, USA		

CONTENTS

ORIGINAL ARTICLES

- Tetiana M. Cherenko, Nataliia S. Turchyna, Yuliya L. Heletiuk
Prevalence and structure of pain syndrome in patients with stroke and Covid-19 687
- Aidyn G. Salmanov, Igor V. Maidannyk, Olena O. Chorna, Oleksandr V. Zabudskyi, Volodymyr V. Artyomenko, Pankiv V. Mariana, Lidiya V. Suslikova, Vitalii S. Strakhovetskyi, Victor O. Rud, Svitlana M. Korniyenko, Serhii Yu. Vdovychenko, Andriy I. Chubatyy, Serhii V. Dudka, Karina Voronina
Epidemiology of endometriosis in female evacuated from the Eastern Ukrainian military conflict regions: results a multicenter study (2022-2024) 694
- Zinaida Y. Zhehulovych, Yuriy I. Babaskin, Vitalii V. Parii, Tetiana A. Shumynska, Roman V. Popov, Tamara A. Melnichuk, Olexandr I. Kovalchuk
Comparative analysis of treatment options for impacted mandibular canines in different age groups of patients. A retrospective study 702
- Yevhen S. Hotko, Diana Stryzhak, Svyatoslav V. Zhero, Viktor Ya. Ihnatko
Changes in morphological and immunohistochemical parameters of tumors during neoadjuvant hormone therapy in postmenopausal patients with luminal type of breast cancer 710
- Valentyna M. Kulygina, Roman S. Arshynnikov, Myroslava S. Drohomiretska, Olha Yu. Pylypiuk, Nataliia G. Gadzhula, Halyna M. Poberezhna, Natalya Polyanyk
Morphological studies of changes in dental hard tissues following different methods of dental deposit removal 717
- Ivan M. Leshchyshyn, Leonid Yu. Markulan, Olga I. Okhotska, Yaroslav M. Susak, Pavlo L. Byk
Quality of life in patients with chronic slow-transit constipation according to the PAC-QOL scale one year after surgical treatment: comparison with preoperative data and reference values 726
- Vitalina V. Ivachevska, Daria A. Korchagina, Olesya A. Kozel, Liliia V. Tsyhanyk, Mykhaylo M. Hechko, Mykhailo M. Ivachevskyi
Beyond traditional lipid markers: why lipoprotein(a) screening matters 735
- Volodymyr V. Maliar, Vitali V. Maliar, Vasyl A. Maliar
Pathomorphological characteristics of the supravaginal part of the cervix depending on the echogenicity ratios of the cervix to the uterine body 740
- Renata V. Symonenko, Leonid O. Etnis, Zinaida Y. Zhehulovych, Vitalii V. Parii, Olena O. Astapenko, Daryna I. Bohatyrova, Iryna M. Fedianovych
Peculiarities of complex oral rehabilitation of young patients with juvenile idiopathic arthritis and malocclusion 746
- Yaroslav Mykhalko, Svitlana Dydytska, Larisa Balatska, Felix Filak, Yelyzaveta Rubtsova
AI-driven rehabilitation: evaluation of ChatGPT-4o for generating personalized physical rehabilitation plans in comorbid patients 753
- Olexii I. Dronov, Inna O. Kovalska, Ivanna A. Shchyhel, Tetiana P. Shevchyk, Vitaliy R. Balyak, Vadym O. Kostiukevich
Pathomorphological features of systemic manifestations of severe acute pancreatitis complicated by abdominal compartment syndrome 760

Ferial Mahmood Abdulrida, Ameena Ryhan Diajil, Taghreed Fahdil Zaidan Assessment of olfactory and gustatory dysfunction in post-COVID dentists by a modified CCCRC	768
Iurii O. Mochalov, Serhii S. Tsuperiak, Vladyslav O. Humeniuk, Bohdan G. Mykhajlychenko, Oksana V. Klitynska Experience in clinical application of various protocols in bone insertion channel preparation for dental implants	777
Olesya M. Horlenko, Yuriy Yu. Chuhran, Gabriella B. Kossey, Viktoria V. Ivano, Mariya A. Derbak, Volodymyr D. Symulyk, Lybov Yu. Pushkash Clinical manifestation, laboratory and instrumental characteristics of infants born to mothers with a complicated anamnesis	783
Yarema V. Kuz, Iryna V. Stovban, Rostyslav Ye. Kovalchuk Prevention of oral diseases in the practice of primary care teams	790
Ashraf Alathary, Zahraa Al-Isawi Tirzepatide therapy counters inflammatory and apoptotic responses induced by high-fat diet in rat liver	797
Iryna Smolanka, Yelyzaveta S. Sirchak The role of lipid metabolism disorders and dysbiotic changes in metabolically dysfunction-associated steatotic liver disease combined with acne vulgaris	806
Yaroslav M. Popovych, Volodymyr S. Kostyunin, Yaroslav Ya. Popovych Surgical prevention of venous thromboembolic complications of thrombosis in the basin of the small saphenous vein	813
Andriy V. Makhnitsky, Igor M. Deykalo, Larysa Ya. Fedoniuk, Tamara V. Datsko, Nadiia I. Gryniv, Nazar M. Ostrovskyy Histological manifestations in the structures of the anterior abdominal wall after implantation of the acellular dermal matrix using the sublay method	821
Oksana V. Bakun, Kristina V. Dyak, Oksana V. Kolesnik, Tetiana Protsak, Yevheniia A. Dudka Correlation between MRNA IL1B and type, duration of infertility in women with endometriosis on the stage preparing to assisted reproductive technologies using probiotics	828
Olesya M. Horlenko, Khrystyna A. Hechko, Lyubomyra B. Prylypko, Mykhaylo M. Hechko, Fedir V. Horlenko, Bohdan M. Galay Comprehensive approach to comparative characteristics of clinical and laboratory parameters of the study in children - in 6 months after Covid-19 treatment and 6 months after Covid-19 vaccination	838
Hiba Hadi Rashid, Raghad Emad Salman, Alyaa Younis Ali, Maysaa Ali Abdul Khaleq The significant impact of T-cell immunoglobulin and mucin domain 3(Tim-3) gene polymorphism on HCV infection and viral load	845
Olesya M. Horlenko, Iryna Yu. Pikina, Olga A. Pushkarenko, Oksana O. Korchynska, Iryna M. Boysak, Ivan I. Pushkash, Halyna M. Beley Cytomorphological characteristics of the nasopharyngeal mucosa in children with acute respiratory infections	853
Maryna M. Dolzhenko, Natalia A. Bilousova, Vasyl M. Mykhalchuk, Natalia O. Tkachenko, Yuliya O. Luchinskaya Study of the influence of medication properties and lifestyle of patients with coronary heart disease on adherence to treatment	860
Olesya M. Horlenko, Oksana M. Berezovska, Lyubomyra B. Prylypko, Valeriya V. Brych, Yana V. Lazur, Kristian O. Debreetseny, Lyubov A. Halay Dynamic morphofunctional characteristics of the respiratory tract in children with recurrent respiratory diseases depending on the method of therapy	876
Zinah Shakib Majeed, Mohammed Qays Mahmood Fahmi Casein phosphopeptide-amorphous- calcium phosphate's effect on enamel microhardness of teeth treated with nano silver in sodium fluoride solution	885

Olga M. Gorbatyuk, Taras V. Martyniuk, Andrey A. Momotov

Practical experience in the surgical treatment of newborns with isolated gastrointestinal perforations based on scientific evidence

894

REVIEW ARTICLES

Olexandr Tyvochuk, Ivan Babii, Vladyslav Makarov

Surgical treatment strategy for Barrett's esophagus as a complication of hiatal hernia

900

Stepan S. Filip, Rudolf M. Slivka, Andrii M. Bratasiuk, Yuriy P. Skrypynets, Antonina V. Varvarets

Features of clinical flow of traumatic illness on a background chronic stress

908

Viktor V. Zaborovskyy, Olena V. Ustych, Tereziia P. Popovych, Vasil V. Manzyuk

Certain ethical issues that arise when using 3D bioprinting technology

915

Anatoliy Potapchuk, Vasyl Almashi, Viktoria Demidowa, Nazar Basarab

Comparative analysis of the clinical application of modern adhesive protocols for ceramic restorations (literature review)

921

Ivan I. Gabani, Jakub Matis, Serhii Bodnar, Stepan S. Kalyniuk

Fourth generation rights in healthcare: Theoretical and practical aspects of implementation

930

Taras I. Griadii, Bohdana V. Bezushko, Olexsandr O. Dutko, Mykhailo M. Lopit

The clinical and pathogenetic manifestations of gastroesophageal reflux disease and obesity and approaches to their diagnosis, treatment, and prevention: current state of the problem (literature review)

937

Vitaliy M. Herzanych, Andrianna Yu. Badyda, Nadiya V. Buletsa, Viktoriia Yu. Svyshcho

Ethical and legal principles of biomedical research

943

Vadym I. Pishta, Sandra O. Boldizhar, Tereziia P. Popovych, Nazar T. Holovatskiy, Anatoliy M. Potapchuk, Mykhaylo M. Hechko

Personal data protection in mHealth apps: international experience and prospects for legislative changes in Ukraine

949

Pathomorphological characteristics of the supravaginal part of the cervix depending on the echogenicity ratios of the cervix to the uterine body

Volodymyr V. Maliar, Vitali V. Maliar, Vasyl A. Maliar

UZHGOROD NATIONAL UNIVERSITY, UZHGOROD, UKRAINE

ABSTRACT

Aim: To analyze the morphological features of the supravaginal part of the cervix depending on the echogenicity ratios of the cervix to the body of the uterus.

Materials and Methods: In 87 reproductive-age patients (30–40 years) with uterine leiomyoma (>14 weeks gestation), morphological features of the supravaginal cervix were analyzed in 23 hysterectomy specimens based on echogenicity ratios: Group I (n = 10): Cervical echogenicity > uterine body. Group II (n = 8): Cervical echogenicity = uterine body. Group III (n = 5): Cervical echogenicity < uterine body.

Results: Histological analysis revealed that increased cervical echogenicity corresponded to a predominance of collagen fibers over smooth muscle bundles. Conversely, when cervical echogenicity was equal to or lower than the uterine body, smooth muscle bundles dominated. These specimens also exhibited destructive changes, connective tissue disorganization, and dystrophic alterations, which are pathognomonic signs of potential lower uterine segment failure during pregnancy.

Conclusions: 1. Comparative studies show that in cases of excess echogenicity of the cervix over the body of the uterus, pathomorphological changes in the supravaginal part of the cervix were not detected. 2. Equal or reduced cervical echogenicity was associated with connective tissue disorganization and dystrophic changes in smooth muscle, indicating structural inferiority. 3. A change in the ratio of echogenicity of the cervix to the body, which is closely related to the morphological structure of the isthmus of the uterus, can serve as one of the criteria for predicting the failure of the lower segment of the uterus in women.

KEY WORDS: Echogenicity, cervix, uterine body

Wiad Lek. 2025;78(4):740-745. doi: 10.36740/WLek/203848 DOI

INTRODUCTION

The increasing frequency of surgical interventions in the lower segment requires improvement of criteria for assessing the morphofunctional state of this anatomical structure even before pregnancy [1-4].

However, only a few scientific works have been devoted to the study of the morphostructure of the lower uterine segment in comparison with the echogenicity of the cervix and uterine body [5].

At the same time, it is known that one of the main contributing factors to inferiority of the lower uterine segment is pathomorphological changes in the area of the lower edge of the uterine body and isthmus, especially after cesarean section [6, 7].

Some authors have established [8] that in conditions of hypo- or hypercollagenosis, the structure of connective tissue may change, becoming more or less elastic in its structure, which affects its elasticity and echo signal reflectivity during ultrasound scanning [9].

Therefore, there are many outstanding issues in early diagnosis of changes in the structural elements of the isthmus of

the uterus, which does not allow to improve the prediction of lower uterine segment insufficiency and improve measures to prevent scar incompetence, especially after cesarean section.

AIM

To analyze the morphological features of the supravaginal part of the cervix depending on the echogenicity ratios of the cervix and the body of the uterus.

MATERIALS AND METHODS

Sonographic determination of echogenicity ratios of the tissues of the cervix and uterine body before surgery and pathomorphological examination of the removed uterus and its isthmus after hysterectomy in women of reproductive age (30-40 years) who were diagnosed with uterine leiomyoma > 14 weeks of gestation. According to the ratio of echogenicity of the cervix to the body, three representative study groups were identified in terms of age and uterine pathology:

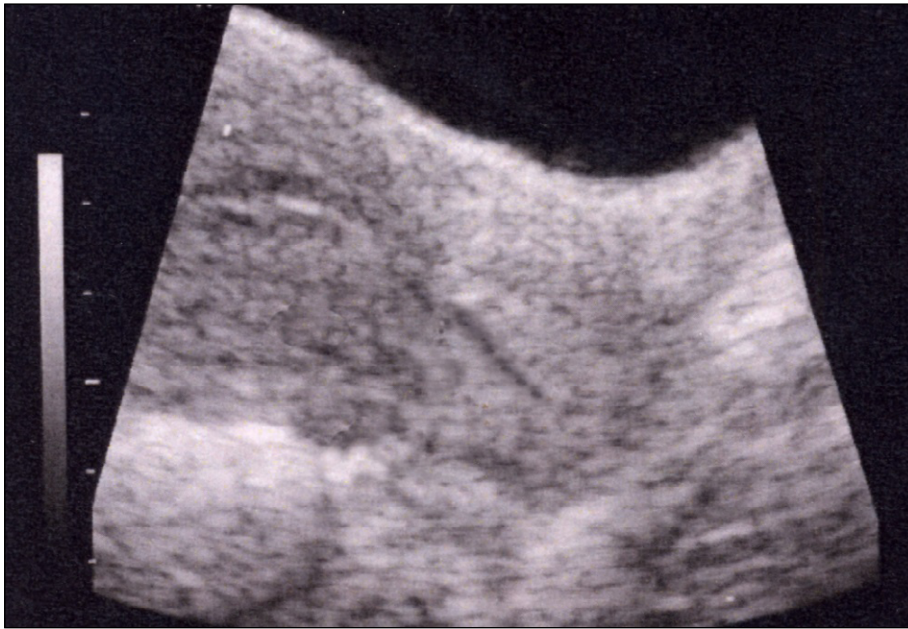


Fig. 1. Echogram of the uterus. The echogenicity of the cervix is higher than the echogenicity of the body of the uterus.

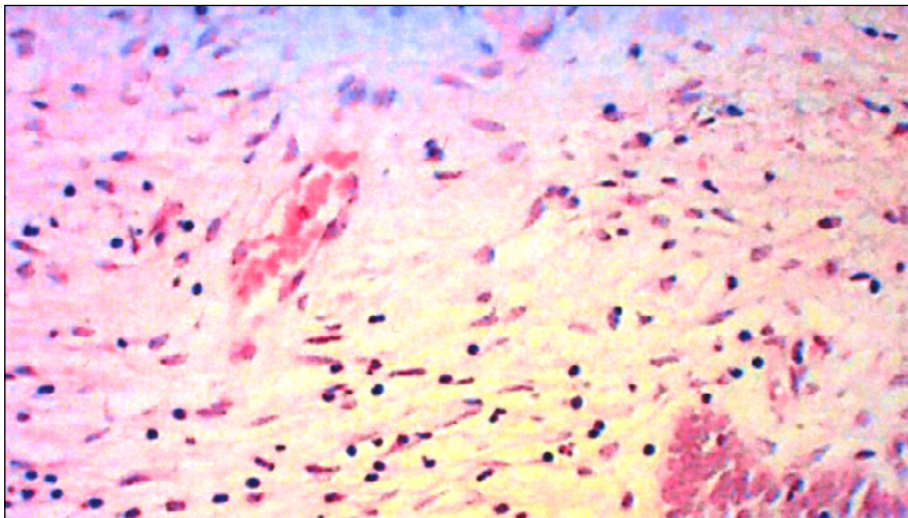


Fig. 2. Biopsy sample supravaginal part of the cervix (isthmus). *Hematoxylin and eosin staining. Predominance of connective tissue (collagen fibers) over smooth muscle bundles. Enlargment: oculus 10, lens 20.

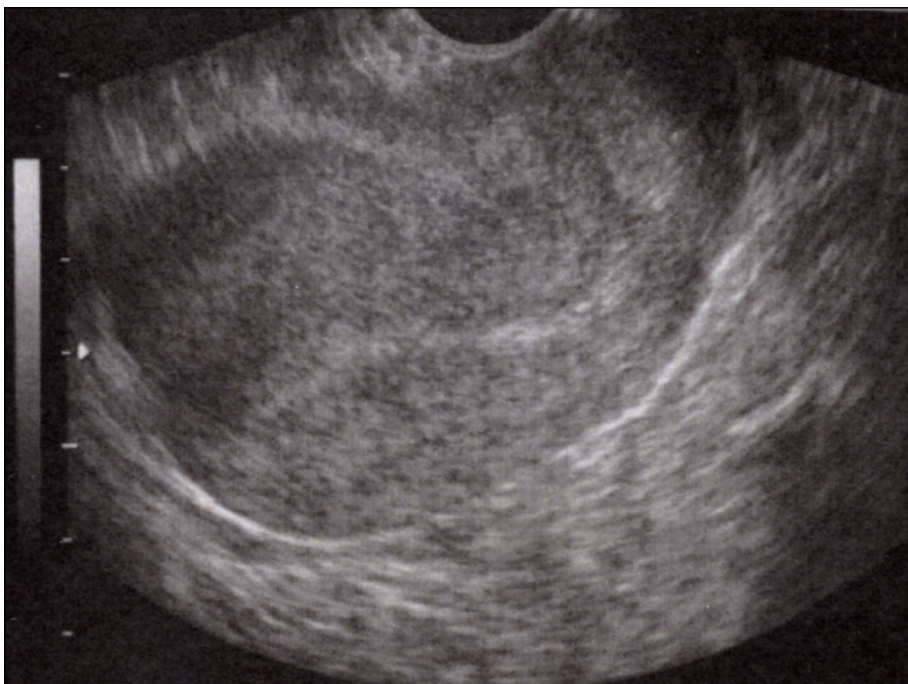

Fig. 3. Echogram of the uterus. The echogenicity of the cervix is the same as the echogenicity of the body of the uterus.

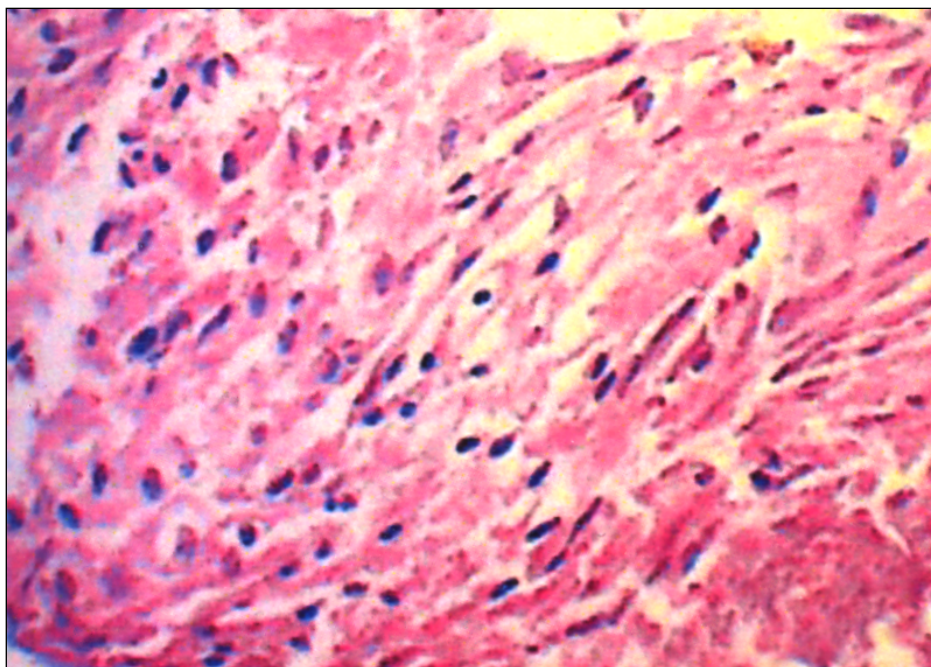


Fig. 4. Biopsy sample supravaginal part of the cervix (isthmus). Staining with hematoxylin and eosin. There is an increase in smooth muscle components over connective tissue components. Enlargement: oculus 15, lens 20.

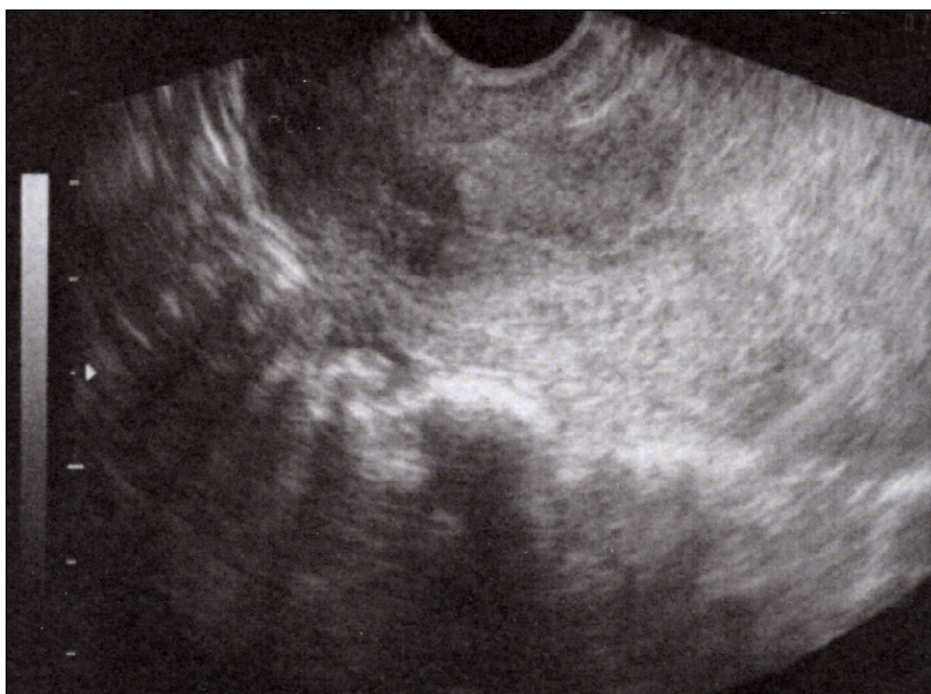


Fig. 5. Echograms of uterine leiomyoma . The echogenicity of the cervix is lower than the echogenicity of the uterine body.

Group I (n = 10) patients whose echogenicity of the cervix prevailed over the echogenicity of the uterine body;

Group II (n = 8), where the echogenicity of the cervix and uterine body coincided with each other;

Group III (n = 5), patients whose echogenicity of the cervix was lower than that of the body.

For the purpose of pathomorphological examination, a biopsy specimen was taken from the supravaginal part of the cervix from the removed uterus. The obtained material was fixed in a 10 percent solution of neutral buffered formalin (pH 7.9) for 24-36 hours, followed by embedding in paraffin blocks.

Features of the morphological structure of the uterine isthmus were studied in histological sections stained with

hematoxylin and eosin depending on the echogenicity ratios of the cervix and uterine body in patients after hysterectomy. uterine leiomyomas . To assess the connective tissue component, sections were additionally stained according to Van Gieson and Masson (Trichrome Stain Kit).

RESULTS

In the first observation group with increased echogenicity of the cervix above the body of the uterus (Fig. 1), in hysterosalpingograms (Fig. 2) of the supravaginal part of the cervix, smooth muscle bundles were found in the form of a thin layer or individual cellular elements.

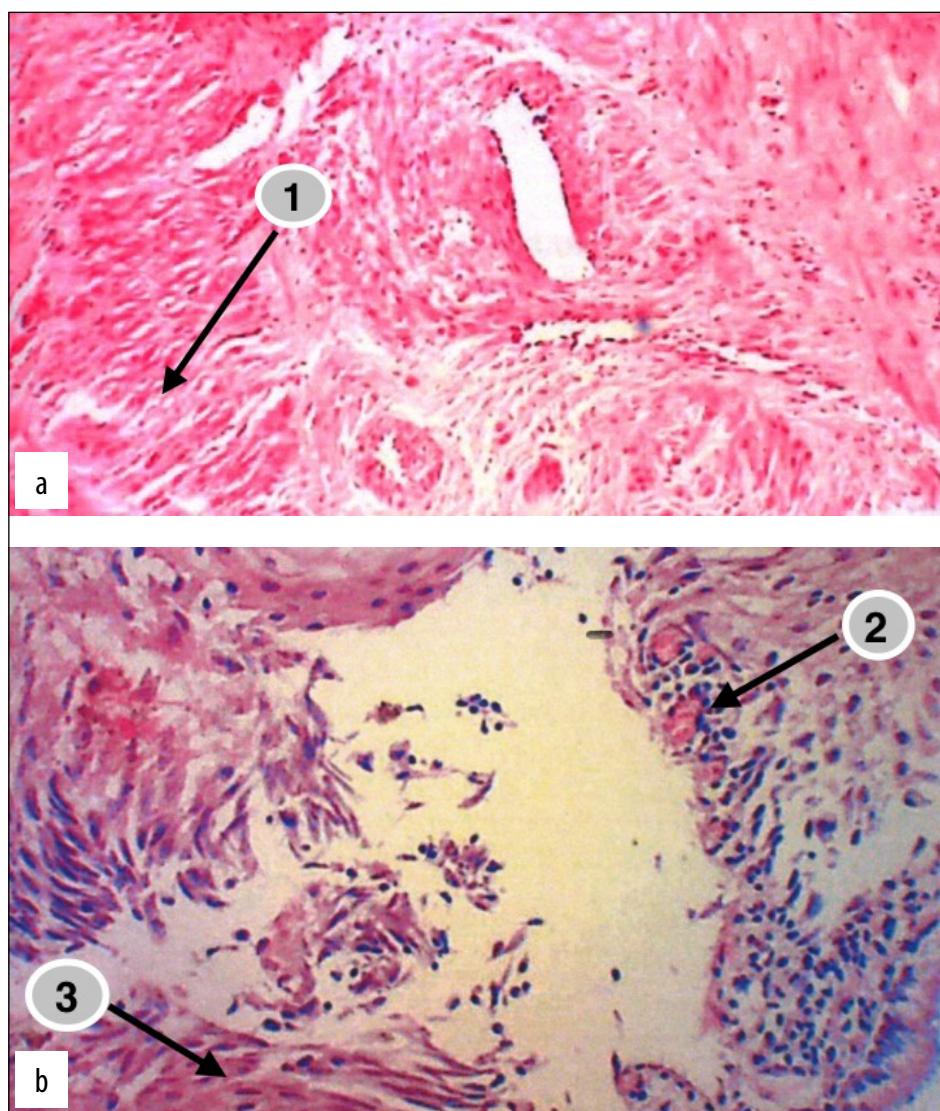


Fig. 6. a, b. Biopsy sample supravaginal part of the cervix with a violation of the morphological structure of the connective tissue in the form of an increase in the spaces between collagen fibers (1), hyperemia of the vessels of the connective tissue with the presence of foci of angiogenesis (2) and a significant number of smooth muscle fibers (3). Staining with hematoxylin and eosin. Enlargement: oculus 10, lens 20.

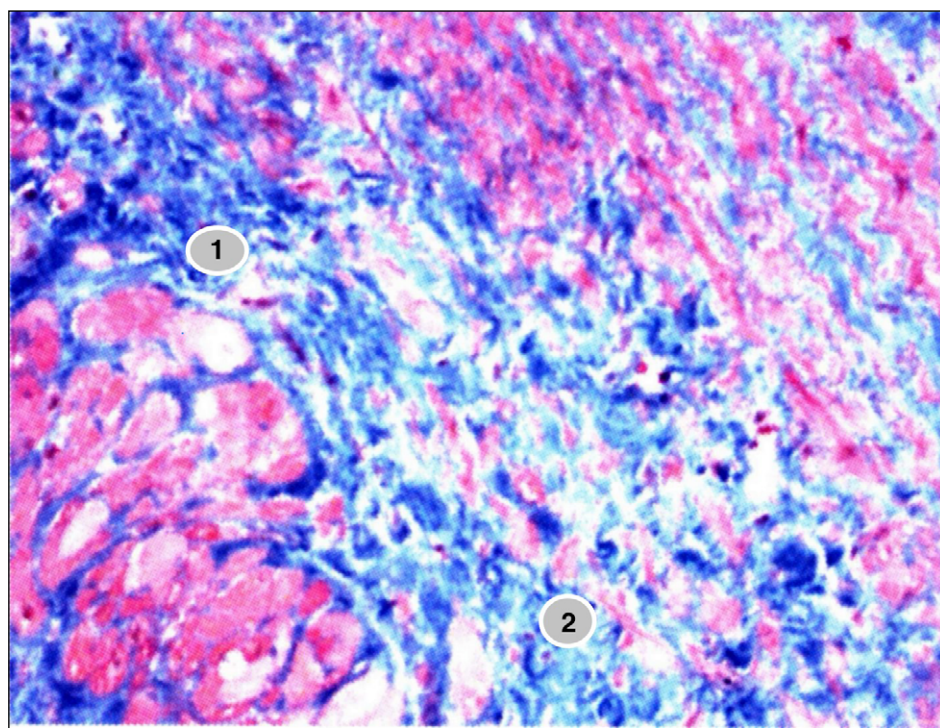


Fig. 7. Biopsy sample supravaginal part of the cervix from a multiparous patient. The histopathology shows a chaotic arrangement of connective tissue fibers with heterogeneous areas of hypochromia (1) and hyperchromia (2) and foci of degeneratively altered smooth muscle bundles. Staining according to Van Gieson and Masson. Enlargement: oculus 10, lens 20.

Smooth muscle bundles were separated by connective tissue fascia, where connective tissue elements predominated, creating a typical paravasal environment through which the functional activity of myocytes is ensured [10].

According to the results of the study, in the second group, both the cervix and the body of the uterus had the same echogenicity (Fig. 3).

Histomorphological data indicate a relative increase in the muscle component over the connective tissue component of collagen and elastic fibers, which predominated by 20-25% over smooth muscle bundles (Fig. 4).

In women of group III with echogenicity of the cervix less than the echogenicity of the uterine body (Fig. 5), on histological specimens. In the supravaginal part of the cervix, there is disorganization of the connective tissue with the presence of individual smooth muscle fibers, hyperemia of the connective tissue, and the presence of angiomas (Fig. 6).

In this case, the collagen tissue of the supravaginal part of the uterus, especially in multiparous patients, is stained heterogeneously with individual areas of hypo- and hyperchromia with the presence of foci of altered smooth muscle bundles (Fig. 7).

DISCUSSION

The results of our study indicate that in the supravaginal part of the cervix, when the echogenicity of the tissues of the cervix exceeds that of the body, the predominance of the muscular component over the connective tissue component is noted. In this case, the smooth muscle bundles are supported by connective tissue, which creates a typical paravasal environment between the muscle bundles, through which the functional activity of myocytes are ensured [10, 11].

In all women with the same echogenicity of the cervix relative to the body of the uterus or lower, disorganization of connective tissue was noted in histological preparations and dystrophic changes were observed in the cells of smooth muscle bundles, which changed the

reflective activity of the echo signal by the structural elements of the cervix and body of the uterus and isthmus. The obtained data are consistent with the literature [11].


In some studies, there is evidence indicating that under conditions of chronic hypoxia, the processes of both collagenogenesis and lithogenesis are disrupted. Therefore, the disorganization of connective tissue and dystrophic changes in the cells of smooth muscle bundles that we have discovered, especially in multiparous patients, indicate the consequence of hypoxia in structural reorganization after traumatization of the lower uterine segment during childbirth.

In the literature there are some scientific works [11,12], which indicate that the intensity of collagen synthesis and the formation of collagen fibers occurs due to autoregulation of the processes of collagen synthesis and breakdown. This can be realized in two ways: pathological, when collagen fibers appear inside the cells in the cytoplasm of fibroblasts and myofibroblasts or by replacing damaged smooth muscle cells in bundles with connective tissue in case of impaired reparative processes [12], which is confirmed by histomorphological changes in histological specimens of multiparous women.

CONCLUSIONS

1. Comparative studies show that in cases of excess echogenicity of the cervix over the body of the uterus, pathomorphological changes in the supravaginal part of the cervix are not detected.
2. With the same or reduced echogenicity of the cervix compared to the body of the uterus, disorganization of connective tissue and dystrophic changes in the smooth muscle bundles of the supravaginal part of the cervix were observed in histological specimens.
3. A change in the ratio of echogenicity of the cervix to the body, which is closely related to the morpho-structure of the isthmus of the uterus, can serve as one of the criteria for predicting the failure of the lower uterine segment in women.

REFERENCES

1. Cesarean section should be performed only if there are medical indications. WHO. 2015. <https://www.who.int/news/item/09-04-2015-caesarean-sections-should-only-be-performed-when-medically-necessary> [Accessed 10.12.2024]
2. Sakai-Bizmark R, Ross M, Estevez D et al. Evaluation of Hospital Cesarean Delivery—Related Profits and Rates in the United States. *JAMA Netw Open*. 2021;4(3):212–235. doi:10.1001/jamanetworkopen.2021.2235. 
3. Zahorodnia OS, Leush SSt, Ventskivska IB. Vahinalni polohy pislia poperednoho kesareva roztynu. [Vaginal positions after previous cesarean dissolve] *Reproduktyvne zdorovia zhinky*. 2021;1:66–6. (Ukrainian)
4. Pro zatverdzhennia Unifikovanoho klinichnogo protokolu pervynnoi, vtoryynnoi (spetsializovanoi) ta tretynnoi (vysokospetsializovanoi) medychnoi dopomohy “Kesariv roztyn” [On approval of the Unified Clinical Protocol of the Primary – Secondary (Specialized) SMOH of Ukraine “Caesarean Section”. Order of the Ministry of Health of Ukraine dated 05.04.2022 No. 8]. <https://ips.ligazakon.net/document/MOZ33363> [Accessed 10 February 2025] (Ukrainian)

5. Prokip US. Udoshonalennia diahnostychnykh ta likuvalnykh zakhodiv pry idiopatychnii ishemiko-tservikalnii nedostatnosti [Improvement of diagnostic and therapeutic measures in idiopathic isthmio-cervical insufficiency]: author's abstract for the degree of candidate of sciences: special 14.01.01.2016. Lviv. 2016, p.20. (Ukrainian)
6. Vakalyuk LM. Kliniko-ekhohefichna kharakterystyka rubtsia na mattsi u vahitnykh [Clinical and echographic characteristics of uterine scar in pregnant women]. Odes'kyi medychnyy zhurnal. 2003;4(78):23-25. (Ukrainian)
7. Kovida NR, Goncharuk OO, Dyadyk OO. Morphological capability of the uterine scar after the previous caesarean section. Reproductive Endocrinology. 2020;(51):42–46. doi:10.18370/2309-4117.2020.51.42-46. DOI [10.18370/2309-4117.2020.51.42-46](#)
8. Lyzin MA. Matkovo-platsentarnyi kompleks pry sindromi zatrymky rostu vahitnoi matky (kliniko-morfolohichne doslidzhennia) [Uteroplacental complex in the syndrome of growth retardation of the pregnant uterus (clinical and morphological study)]. Ivano-Frankivsk: Tipovit. 2002, p.222. (Ukrainian)
9. Berghella V, Kuhlman K, Weiner S et al. Cervical funneling sonography criteria predictive of preterm delivery. Ultrasound Obstet Gynecol. 2002;10(3):161-6. doi: 10.1046/j.1469-0705.1997.10030161.x. DOI [10.1046/j.1469-0705.1997.10030161.x](#)
10. Lyzin MA. Ultrastrukturni osnovy spoluchnotkanynnoho karkasa matky pry fiziologichnii vahitnosti ta u zhinok iz zatrymkoiu rozvytku ta rostu ploda. [Ultrastructural basis of the connective tissue framework of the uterus during physiological pregnancy and in women with delayed fetal development and growth]. Ukrainian Medical Almanac. 2000;5(3):116-118. (Ukrainian).
11. Lyzin MA. Morfolohichni ta ultrastrukturni zminy miometrii pry zatrymtsi rozvytku ploda [Morphological and ultrastructural changes in the myometrium in fetal growth retardation]. Naukovyy visnyk Uzhhorods'koho universytetu, seriya "Medytsyna". 2000;11:276-279. (Ukrainian)
12. Potapov VA, Medvedev MV, Stepanova DYU et al. Reproduktyvne zdorovia zhinok pry leiomiomi matky [Reproductive health of women with uterine leiomyoma]. Medychni perspektyvy. 2011;16(3):34-38. (Ukrainian)

CONFLICT OF INTEREST

The Authors declare no conflict of interest

CORRESPONDING AUTHOR

Vitalii V. Maliar

Uzhhorod National University

3 Narodna Sg., 88000 Uzhhorod, Ukraine

e-mail: mvitv1975@ukr.net

ORCID AND CONTRIBUTIONSHIP

Volodymyr V. Maliar: 0000-0003-0113-8995 [A](#) [C](#)

Vitalii V. Maliar: 0000-0002-9950-5 014 [B](#) [E](#)

Vasyl A. Maliar: 0000-0003-0350-3255 [D](#) [F](#)

[A](#) – Work concept and design, [B](#) – Data collection and analysis, [C](#) – Responsibility for statistical analysis, [D](#) – Writing the article, [E](#) – Critical review, [F](#) – Final approval of the article

RECEIVED: 11.12.2024

ACCEPTED: 28.03.2025

